



IMAGE ARTICLE

A Large Lipoma of Neck

Alhad Mulkalwar*, Sujay Jaju and Samir Deolekar

Department of General Surgery, Seth Gordhandas Sunderdas Medical College and King Edward Memorial Hospital, Mumbai, India

*Corresponding author: Alhad Mulkalwar, Intern (M.B.B.S), Seth Gordhandas Sunderdas Medical College and King Edward Memorial Hospital, Acharya Donde Marg, Parel, Mumbai - 400 012, India



A 30 year-old female presented with a gradually increasing painless swelling in the back of the neck, growing since the last two years. The swelling was about 2 cm in size when first noticed, which gradually increased to its present size (Figure 1). Examination revealed a large, soft, globular swelling in the back of the nape of the neck. Surface was lobulated and the margins were rounded, well defined and slipped under the finger. Fluctuation and transillumination

tests were negative. The skin was free and the swelling was freely mobile on the underlying structures. The swelling became more prominent on contraction of the underlying trapezius muscle. Its location and clinical examination suggested the diagnosis of a subcutaneous lipoma. Owing to the physical discomfort it was causing, the lipoma was successfully excised. Histopathological examination (Figure 2) of the specimen confirmed the diagnosis of a lipoma.

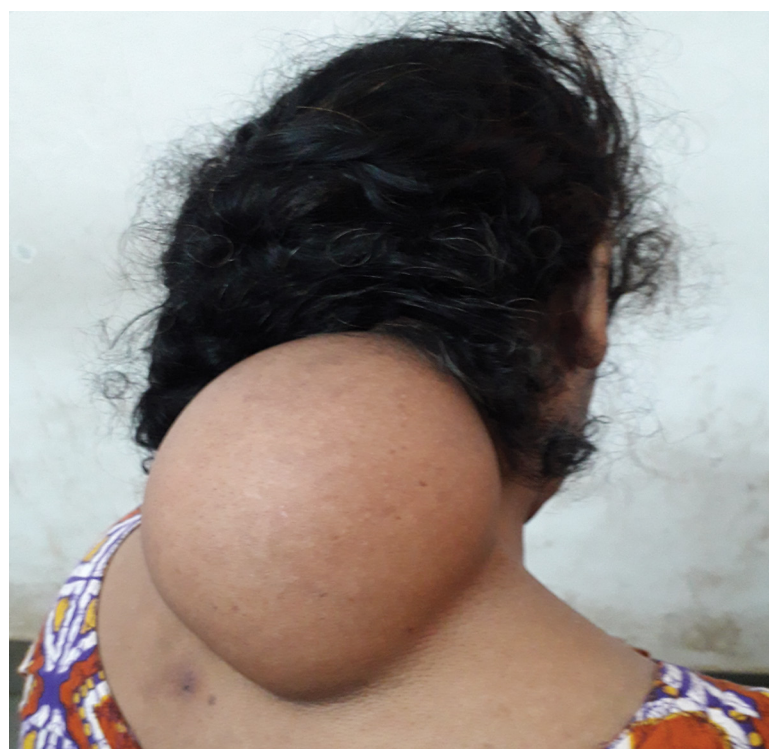

Figure 1: A large, soft, globular swelling in the back of the nape of the neck.

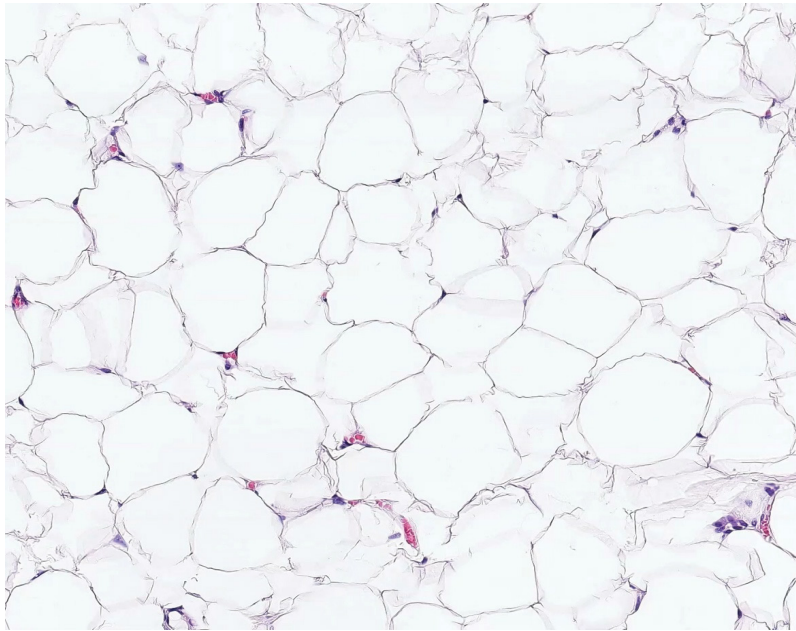


Figure 2: Histopathology of the excised specimen showed mature adipose tissue (adipocytes with peripheral nuclei). Few small capillaries within thin fibrous strands could also be seen.