



IMAGE ARTICLE

Vesico-Vaginal Fistulae

Benatta Mahmoud*

Head of Urology Department, Chu Oran, Oran 1 University, Algeria

*Corresponding author: Benatta Mahmoud, Head of Urology Department, CHU Oran benzerdjeb, Oran 1 University Ahmed Ben Bella, Algeria, Fax: +213412232



Case Description

42 years deaf virgin female consulted for urine permanent leakage through vagina.

She had gynecologic surgery six months ago for uterine fibroids.

Classic physical examination was limited.

Digital touch and speculum and by methylene blue test, was not performed because the patient and her family did not agree.

Diagnosis of vesico-vaginal fistula made mainly by radiology imaging (Figure 1 and Figure 2).

Retrograde and mictionnal uretro-cystography showed a clear leakage of contrast from the bladder into the vagina.

We avoided a trans-vaginal approach and closed the fistula in two plans by transvesical route with excellent results.

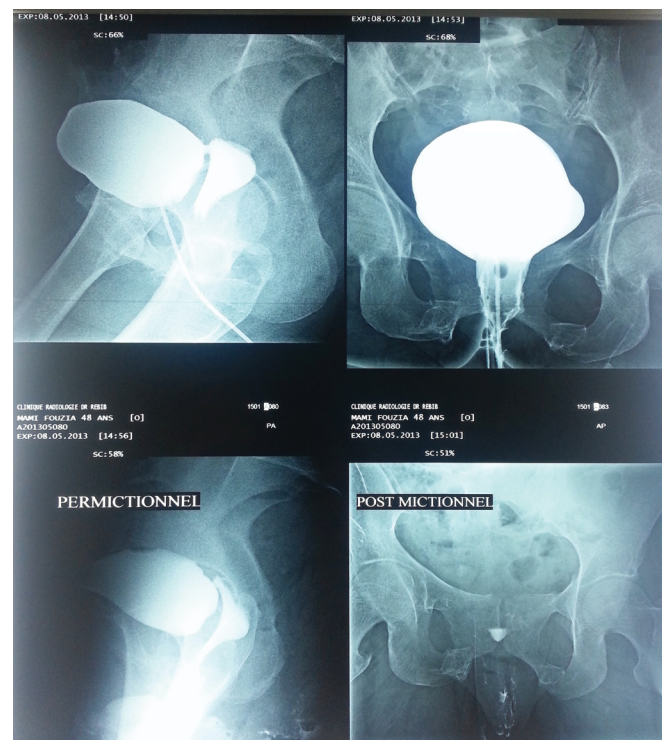


Figure 1: Diagnosis of vesico-vaginal fistula made mainly by radiology imaging- FVV 2.

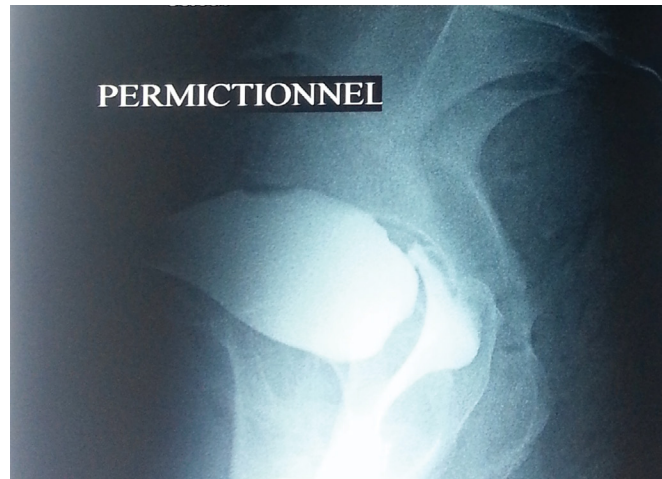


Figure 2: Diagnosis of vesico-vaginal fistula made mainly by radiology imaging- Per miction FVV 2.