



A Patient with Rare Heterogenic Histopathological Presentation and Atypical Sites of Metastases in Oropharyngeal/Hard Palate Cancer: A Case Report

Aleksandra Danieluk¹, Aleksandra Filimoniuk¹, Joanna Mańdziuk¹, Anna Marczuk¹, Marek Z Wojtukiewicz^{2,3} and Ewa Sierko^{2,3*}

¹Students' Scientific Association affiliated with the Department of Oncology Medical University of Bialystok, Poland

²Department of Oncology, Medical University of Bialystok, Poland

³Comprehensive Cancer Center in Bialystok, Poland

*Corresponding author: Ewa Sierko, MD, PhD, Department of Oncology, Medical University of Bialystok, Poland, Tel: 0048-602337020, E-mail: ewa.sierko@iq.pl

Abstract

Introduction: The incidence of head and neck cancers is relatively high in Poland, with approximately 6500 new cases diagnosed each year. More than 90% of them are squamous cell carcinomas, treatment of which continues to provide a challenge for clinicians, despite recent advancements in surgery, radiotherapy and chemotherapy. The described patient presented subcutaneous metastases, which account for less than 10% of distant metastases from this kind of tumour. Apart from unusual site of metastases, the tumour presented histological heterogeneity. During the patient's treatment, epidermal growth factor receptor-targeted therapy - cetuximab was used and possibly influenced the patient's survival time.

Case presentation: A case of a 45-year-old Caucasian female oropharyngeal cancer patient, who developed rare metastases to the skin and pleura, is presented. The tumour was characterised by four different histological types of cancer (mucoepidermoid carcinoma, squamous cell carcinoma, undifferentiated carcinoma and adenoid cystic carcinoma). The patient was first diagnosed with locoregionally advanced mucoepidermoid carcinoma (T3N0M0). She was primarily treated with radical surgery. Histopathological report identified the positive margin of resected fragment as squamous cell carcinoma. Subsequent chemoradiation to the tumour bed and regional lymph nodes was administered and locoregional control was achieved. After six months, the first cutaneous metastasis appeared. Pathological report revealed metastatic undifferentiated cancer cells. A chest computed tomography performed at the same time showed subpleural metastases. The patient was administered chemotherapy based on platinum and 5-fluorouracil, combined with cetuximab, followed by cetuximab in monotherapy. Three months after the initiation of the treatment with cetuximab, new skin lesions on the scalp appeared. Surgical removal of the subcutaneous lesions was carried out, and histopathological report identified metastatic sialogenic tumour (adenoid cystic carcinoma - tubular type). Second-line chemotherapy, consisting of vinblastine, methotrexate, 5-fluorouracil and cyclophosphamide was applied. The patient died of respiratory failure 16 months after developing distant metastases.

Conclusion: The report highlights the importance of novel forms of anticancer therapy in effective treatment of metastatic oropharyngeal cancer patients, particularly those with heterogenic tumours. It also emphasises how early recognition and treatment of atypical metastases can improve the patients survival rates.

Keywords

Oropharyngeal cancer, Atypical metastases, Squamous cell carcinoma, Cetuximab, Heterogenic histopathological presentation

List of Abbreviations Used

HNSCC: Head and Neck Squamous Cell Carcinoma; EGFR: Epidermal Growth Factor Receptor; CT: Computed Tomography; IMRT: Intensity Modulated Radiation Therapy; 5-FU: 5-Fluorouracil; G-CSF: Granulocyte Colony-Stimulating Factor; SCC: Squamous Cell Carcinoma; MEC: Mucoepidermoid Carcinoma; ACC: Adenoid Cystic Carcinoma; PF Chemotherapy: Platinum-Fluorouracil Chemotherapy; RTKs: Receptor Tyrosine Kinases; EGF: Epidermal Growth Factor; TGF: Tumour Growth Factor; FDA: Food and Drug Administration; EAMA: European Academy for Medicine of Ageing

Background

Head and neck cancers account for 5% of all malignancies registered in Poland [1]. The majority of them are squamous cell carcinomas (about 90%) [2]. Head and neck squamous cell carcinoma (HNSCC) is the sixth most common neoplasm in the world [3]. One of the subgroups of head and neck cancers (10%) are cancers that occur in the oropharynx [4]. Traditional treatment options for squamous cell oropharyngeal carcinoma patients include primary surgery followed by radiation/chemoradiation, definitive chemoradiation, or induction chemotherapy followed by chemoradiation. Despite administration of radical antineoplastic treatment, some patients experience disease progression (local, regional or distant). Distant metastases are observed in about one fifth of squamous cell carcinomas of the head and neck [5]. The most commonly diagnosed are pulmonary metastases (accounting for more than half of distant

Citation: Danieluk A, Filimoniuk A, Mańdziuk J, Marczuk A, Wojtukiewicz MZ, et al. (2016) A Patient with Rare Heterogenic Histopathological Presentation and Atypical Sites of Metastases in Oropharyngeal/Hard Palate Cancer: A Case Report. Clin Med Rev Case Rep 3:124

Received: June 29, 2016; **Accepted:** August 06, 2016; **Published:** August 10, 2016

Copyright: © 2016 Danieluk A, et al. This is an open-access article distributed under the terms of the Creative Commons Attribution License, which permits unrestricted use, distribution, and reproduction in any medium, provided the original author and source are credited.

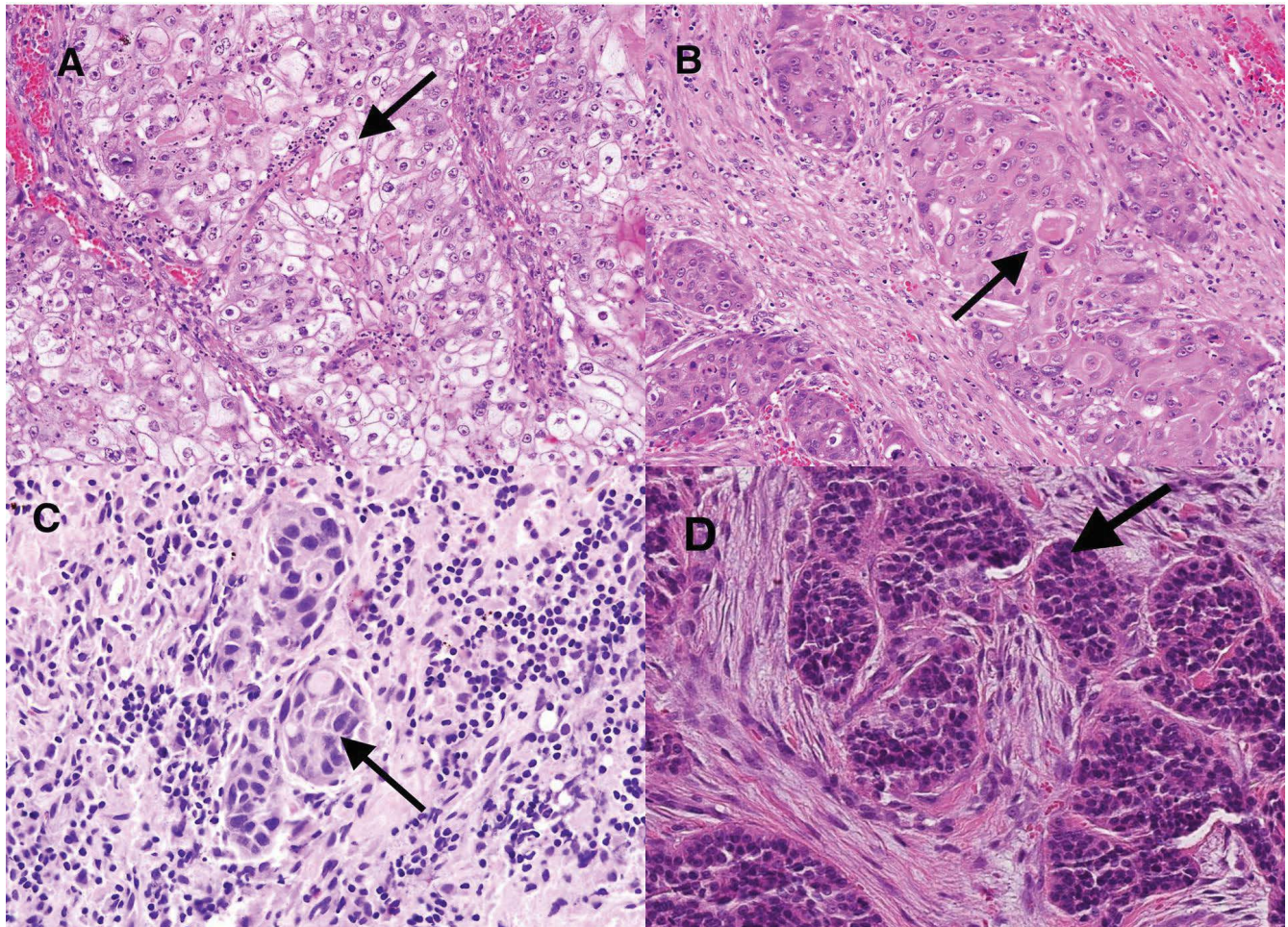


Figure 1: Specimens obtained from the patient described in the paper. Arrows show tumour cell bodies of (A) mucoepidermoid carcinoma; (B) squamous cell carcinoma; (C) undifferentiated carcinoma; (D) adenoid cystic carcinoma. Haematoxylin and eosin stain; original magnification $\times 200$ (A, B, D) and $\times 400$ (C).

metastases), followed by bone and liver metastases. Rarely, metastases can occur in other sites, e.g. in the subcutaneous tissue [6]. More than half of head and neck cancer patients present with locoregionally advanced stages (III and IV) of the disease [7]. To date, palliative treatment of disseminated head and neck cancers is disappointing. Therefore, a need for new therapies has emerged. To date the most effective palliative method is adding targeted therapy to standard chemotherapy. Targeted therapy aims to inhibit the proliferation of tumour cells, using small molecules or monoclonal antibodies that bind to the extracellular domain of receptor protein, or to its ligand, thereby blocking a signalling pathway responsible for uncontrollable cell divisions. Epidermal growth factor receptor (EGFR) plays a role in tumour cell growth, angiogenesis and invasion. Most of the head and neck cancers are characterised by EGFR presence. The first monoclonal antibody used in extensive randomised clinical trials, in patients with HNSCC, was cetuximab.

In recent years, multiple clinical trials have attempted to establish the efficacy of combining cetuximab with radiotherapy or platinum-fluorouracil chemotherapy (PF) in the first-line treatment of locoregionally advanced HNSCC, as well as in recurrent/metastatic disease. In a study conducted by Bonner et al. cetuximab was demonstrated to increase overall survival and locoregional disease control, when administered concurrently with radiation therapy, compared to the efficacy of radiation alone [8]. However, later studies showed that the addition of cetuximab to chemoradiation regimens does not significantly improve progression-free survival or overall survival rates [9]. Thus, the feasibility of using cetuximab in patients with locally advanced HNSCC remains uncertain. It is, however, widely used in the palliative treatment of metastatic HNSCC where it has been shown to improve survival rates without a significant increase in toxicity, compared with PF chemotherapy.

Below, a case of a patient who was diagnosed with four different histological types of carcinoma: mucoepidermoid carcinoma, adenoid cystic carcinoma, undifferentiated cancer cells and squamous cell carcinoma is presented. The patient also experienced rare metastases of the cancer to the subcutaneous tissue and underwent combined treatment.

Case Presentation

Case report

A 45-year-old female was referred to the Oncology Department with a suspicion of oropharyngeal carcinoma. The patient was not previously exposed to any carcinogens, had no history of smoking, her BMI was within normal range and she only had one sexual partner in her life. Pathological examination of the tumour fragment obtained by an incisional biopsy revealed G2 mucoepidermoid carcinoma (Figure 1A). A contrast head and neck computed tomography (CT) examination showed a tumour of the left soft palate (21 \times 16 mm), constricting the lumen of the nasopharynx and choanae, situated adjacent to the medial pterygoid plate, with neither cervical lymph node enlargement nor bone/pterygoid muscle infiltration visible in the scans (Figure 2A). The diameter of the tumour was greater than 4 cm, which allowed the tumour to be staged as T3N0M0. The patient underwent surgical treatment. The tumour was removed with a portion of the left medial pterygoid plate, left maxillary tuberosity and left tonsillar bed. Left selective neck dissection (regions II-IV) was also performed. Due to advanced infiltration of surrounding tissues in the area of the pterygopalatine fossa, unseen on preoperative CT scans, negative macroscopic and microscopic resection margin was not achieved. Contrary to the pre-operative histopathology finding, postoperative pathology reports revealed squamous cell carcinoma (Figure 1B). The tumour was not tested for HPV presence, because

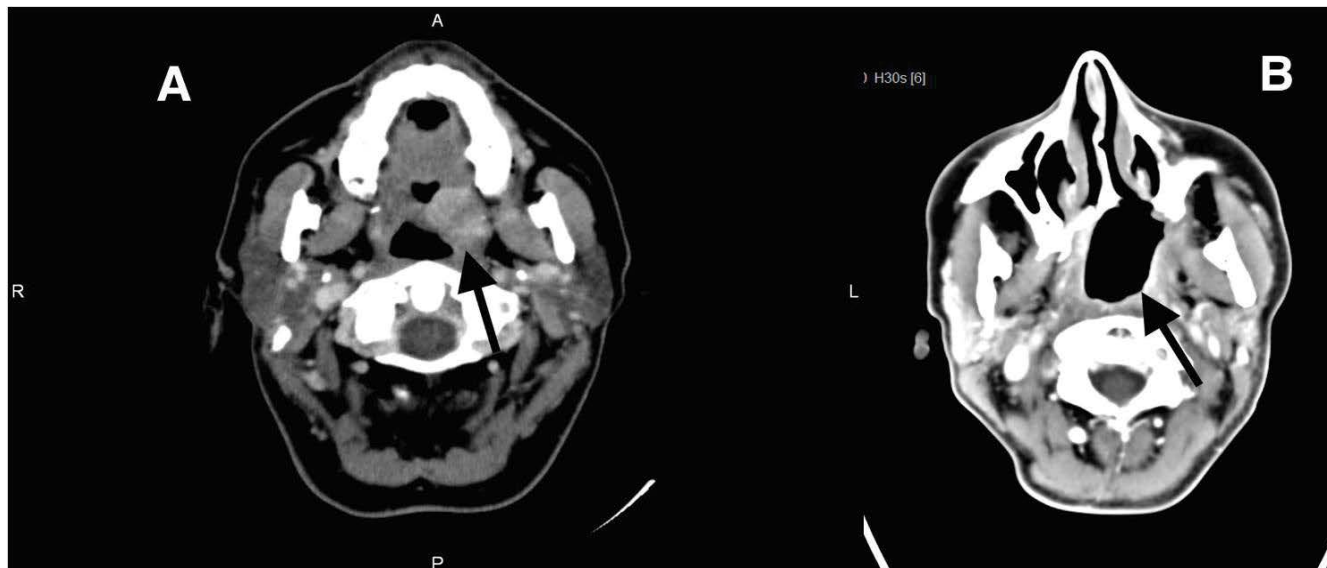


Figure 2: Axial contrast-enhanced CT images in the 45-year-old patient with the T3N0M0 carcinoma of the left soft palate. (A) Contrast-enhancing tumour of left soft palate (arrow); (B) Post-surgery CT image obtained 6 months after completion of radiochemotherapy. No evidence of locoregional recurrence is visible (arrow).

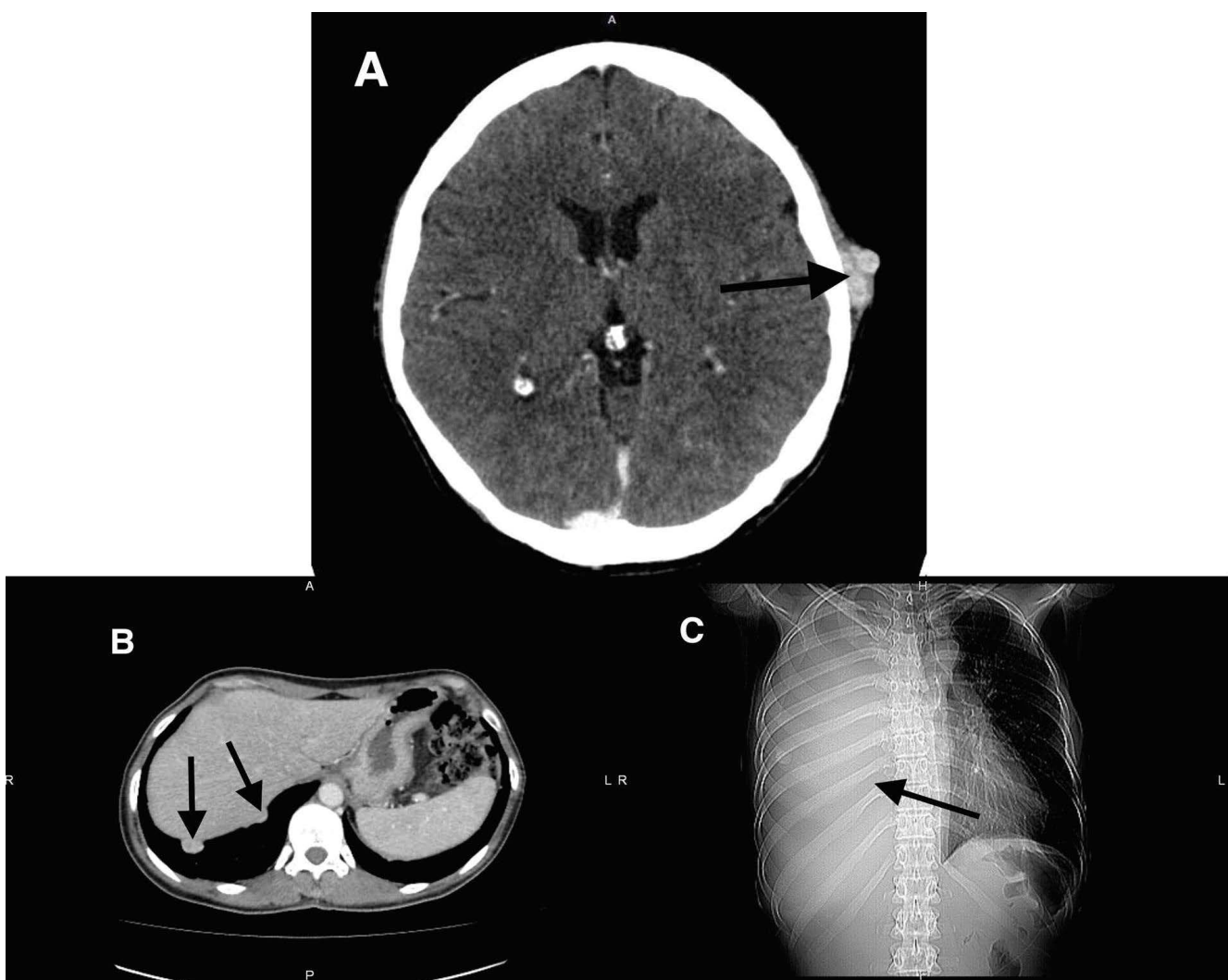


Figure 3: Diagnostic imaging showing metastatic masses: (A) Axial head CT scan showing a subcutaneous metastasis in the left temporal area (arrow). Pathology report concluded the mass consisted of undifferentiated cancer cells; (B) Axial contrast-enhanced abdominal CT scan showing subpleuritic masses, demonstrating strong contrast enhancement (arrows); (C) AP chest X-ray - massive right-sided pleural effusion, atelectasis, and displacement of the mediastinal structures to the left (arrow).

it was not a standard procedure at the time. For a month, the patient underwent bilateral adjuvant intensity modulated radiation therapy (IMRT) with X6MV photon beam applied to the area of the tumour

bed and level II - IV lymph nodes (total dose of 70 Gy in 35 fractions), given concurrently with chemotherapy (3 courses of cisplatin, 100 mg/m² each, every 21 days). The treatment was complicated by

anaemia, treated successfully with transfusion of two units of packed red blood cells. Head and neck CT examinations performed 3 and 6 months after chemoradiation cessation showed no evidence of locoregional disease (Figure 2B). Six months after the end of the treatment the patient reported a 4 mm subcutaneous atypical tumour in the left temporal area, above the ear (Figure 3A). A fine needle aspiration biopsy identified cutaneous adnexoma. Two months later similar lesions (2 cm in diameter) appeared in the right axilla and in the subcutaneous tissue of the right arm. Ultrasound examination suggested metastatic tumours. Excisional biopsy of the subcutaneous lesion in the left temporal area identified metastatic undifferentiated cancer cells (Figure 1C). Chest CT performed at the same time revealed subpleuritic masses showing strong contrast enhancement, the biggest of which was 9 mm in diameter (Figure 3B). A similar metastatic mass, 13 mm in diameter, was located in the subcutaneous tissue, anteriorly to the right deltoid muscle. One month later, the patient was administered palliative chemotherapy, consisting of cisplatin (100 mg/m² day 1) and 5-fluorouracil (5-FU) (1000 mg/m²/day, continuous infusion day 1-4). However, in the second and third course cisplatin dose was reduced by 20%, due to severe nausea and vomiting, uncontrolled with antiemetic medications. Follow-up CT after 3 courses of chemotherapy revealed progression of the disease, increase in size of several of the subpleural nodules and multiple new lesions, as well as further progression of the subcutaneous metastases. Targeted therapy with cetuximab was initiated. In total, the patient received 3 courses of cetuximab, combined with cisplatin and 5-FU and 7 courses of cetuximab in monotherapy, one with a slight delay, due to the patient having to undergo a minor surgical procedure to remove an ingrown toenail, which was a complication of the treatment. Head and neck CT scan, performed two months after initiation of the treatment with cetuximab, showed an increase in size of one of the subcutaneous lesions. A month later, new lesions of the scalp appeared, however a follow-up chest CT showed stabilisation of the disease, no new subpleural nodules were present. Surgical removal of the subcutaneous lesions of the head, right axilla and right shoulder was carried out and histopathological report identified metastatic sialogenic tumour (adenoid cystic carcinoma - tubular type) (Figure 1D). One month later, a follow-up chest CT demonstrated a progression of the lung metastases. Breast ultrasound examination performed the next month detected a solid lesion in the left axilla - 19 mm in diameter. The patient underwent the first course of second-line chemotherapy. It consisted of Vinblastine - 5 mg/m², Methotrexate - 25 mg/m², 5-fluorouracil - 500 mg/m² and Cyclophosphamide - 100 mg/m², administered every week. In total, the patient was administered 4 courses of the second-line chemotherapy. Two weeks later, an abdominal ultrasound revealed a mass in the pancreatic tail, measuring 15×12 mm (suspected metastasis), and right pleural effusion. A chest x-ray showed a significant amount of fluid within the right pleural space (Figure 3C). One week later, on physical examination, vesicular sounds over the right lung field were diminished and percussion note was dull on the

right side of the chest. X-ray confirmed right pleural effusion. The patient was immediately referred for thoracentesis and 800 cm³ of fluid was removed from the right pleural space. One week later, the patient reported steadily decreasing exercise tolerance. One month later chest CT showed a massive amount of fluid in the right pleural space, right-sided atelectasis, and displacement of the structures of the mediastinum to the left. Multiple nodules were present within the pleura. Mediastinal lymph nodes were enlarged. The patient was admitted to the hospital one week later in poor general condition, with exacerbation of dyspnoea at rest. Chest CT again revealed right pleural effusion; breath sounds were decreased over the affected area. The skin lesions had increased in size. Due to progression of the disease and no improvement following chemotherapy, the patient was taken off cytostatic drugs. She was then transferred to the pulmonology ward in order to undergo thoracentesis, where her condition rapidly deteriorated and she died a month later (Figure 4).

Discussion

The most frequent type of cancer diagnosed in the oropharyngeal region is squamous cell carcinoma (SCC). The results of treatment for SCC of the oropharynx remain satisfactory in most patients, particularly in patients with HPV-related malignancy.

Interestingly, the patient was diagnosed with four different histological types of the same cancer, indicating heterogeneity of the tumour. Each of the histological types of tumour, which were present throughout the patient's medical history, follows different patterns of spreading as distant metastases. The primary incisional biopsy showed mucoepidermoid carcinoma. Mucoepidermoid carcinoma (MEC) is most commonly a salivary gland malignancy although it can be found in other organs like lungs [10], maxilla, mandible, breast tissue and thymus [11]. MEC is diagnosed based on identification of three elements occurring at the same time: mucin-producing cells, intermediate and/or clear cells, and squamoid cells [12]. Generally, histologic grading is an important factor in appearance of distant metastases from this kind of tumour. Previous studies show that the incidence of distant metastases is much higher in cases of high-grade carcinoma than in the low-grade (3.2% vs. 0.2 %) [13,14]. Low-grade carcinoma is likely to be cured by appropriate surgery, if negative resection margin is achieved. As for the intermediate-grade carcinoma, some of the studies show that its behaviour is similar to the low-grade cases, and others show its similarity to the high-grade carcinoma [13]. However, even in the high-grade mucoepidermoid carcinoma the presence of a distant metastasis to the skin is a rare event [15].

Unexpectedly, postoperative pathology reports revealed SCC, the most common malignant tumour of the oropharynx. Tumours of this histological type usually grow fast and give metastases early, unlike mucoepidermoid carcinoma. In SCC cases, the risk of developing distant metastases increases with the advancement of the clinical stage of cancer [16]. Skin metastases account for less than 10% of the

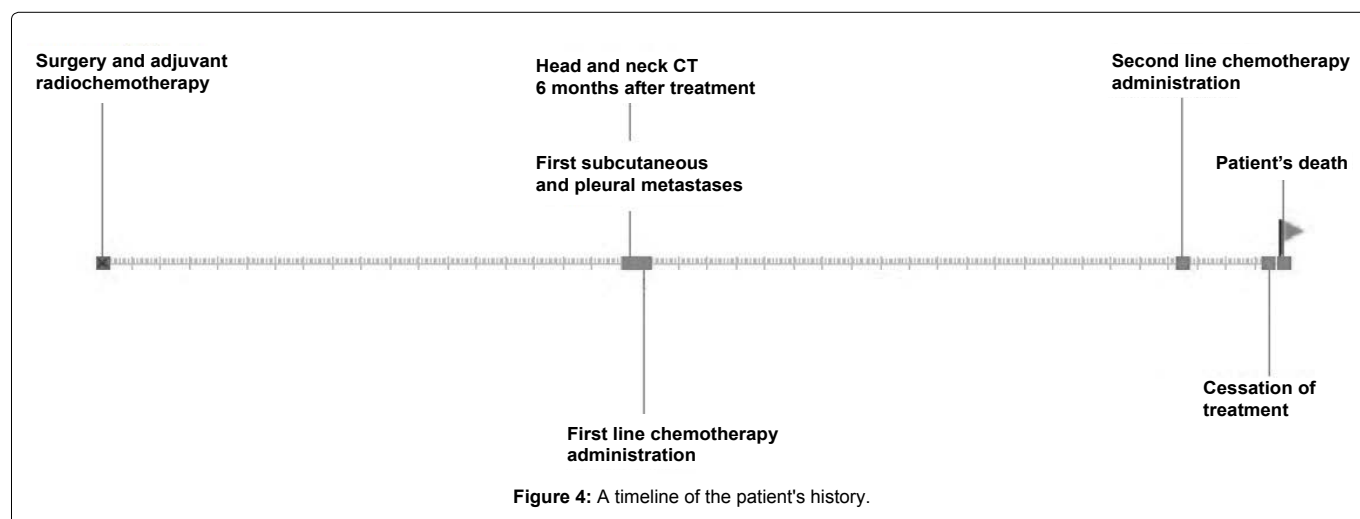


Figure 4: A timeline of the patient's history.

cases of the distant metastases in this type of tumour [17,18]. They are most frequently located above the diaphragm [18], which was also the case for the patient described above. The presence of skin metastases in this type of cancer may be associated with an advanced stage of illness [17], though some of the studies show that patients in all stages of the disease might develop skin metastases [19]. In the described case, skin metastases were the first manifestation of the disseminated disease. Distant metastases are usually associated with a poor prognosis; the median survival after diagnosis of skin metastases reported in literature varies between 3 months [18] and 17 weeks [17]. The 1-year survival rate after manifestation of skin metastases is low (from 0% [19] to 9.8% [17]). The patient in the case described above survived a relatively long time (16 months after the development of the first skin metastasis). She had no other metastatic foci present at the time when the skin metastases were first observed. However, three months later, subpleural metastases were diagnosed in the chest CT. The occurrence of distant metastases in a typical site, after the diagnosis of dermal metastases, is a rare event in late-stage HNSCC. Namely, in a previous study 21% of patients with skin metastases developed concurrent distant metastases to other sites, and 31.6% of the patients had no other present sites of disease during a median of 6 months follow-up [18]. In another study, none of the patients who initially presented with skin metastases alone, developed metastases in the most common sites for this kind of tumour [19]. In fact, in the presented patient, subpleural but not interstitial lung metastases were diagnosed, while the typical case is the appearance of interstitial lung metastases.

The excisional biopsy of the lesion in the left temporal area revealed undifferentiated carcinoma, proving the theory of heterogeneity of the tumour and more frequent distant spreading of high grade carcinoma cells compartment to low grade compartment of the carcinoma.

Subsequent histopathology reports of some of the other subcutaneous metastatic masses showed adenoid cystic carcinoma (ACC). This kind of carcinoma usually affects major and minor salivary glands, lacrimal glands, ceruminous glands, and occasionally excretory glands of the female genital tract [20]. Histopathologically, ACC is formed by basaloid cells with sparse cytoplasm and hyperchromatic nuclei, which create cords, tubules or solid areas, all of them embedded in mucinous or sclerotic stroma. Previous studies show that distant metastases appear frequently in this type of cancer (38% of cases) [21], with the lungs being the most common site [21]. However, it is very rarely a primary malignancy of the skin (60 reported cases) and skin is not a common site of distant metastases from this kind of tumour. Because of the rare incidence of dermal manifestation of ACC and possibility of confusion with other primary tumours of the skin [22], very few cases of skin metastases in this type of tumour were described (8 cases published so far) [23]. In the cases described to date in literature, the skin metastases appeared in such sites as the scalp and the back [23], the upper lip [24], the abdomen and the preauricular area [25], shoulder, elbow and the mental region [26]. In the described patient, the metastases appeared in similar regions. In ACC, the cutaneous metastases are also associated with a poor general prognosis, because they usually indicate an advanced stage of the disease. Compared to the previously published cases, the patient described above survived a shorter period of time after the development of distant metastases.

Head and neck cancer patients often develop another primary cancer (incidence of 2-3%/year of either synchronous or metachronous lesions - of these metachronous malignancies are much more frequent, occurring in 20-30% of HNSCC patients, while synchronous malignancies are present in 1-6%), which strongly suggests the same aetiology of both tumours [27,28]. Taking that into consideration, we can assume that the primary tumour developed, in fact, from two different histological types of cancer, SCC and MEC. Co-occurrence of different histological types was also described in the oesophagus (3 described cases) [29] and was associated with a poor prognosis. This hypothesis could also explain the presence of yet another, different histological type of cancer in metastases.

It should be mentioned, however, that MEC and SCC are often confused due to squamoid component of MEC. Especially when content of mucosa producing cells is low and extreme nuclear pleomorphism is present there is a slight possibility of misdiagnosis in the results of biopsy [30], if the tumour occurs in a non-characteristic localisation [30].

In recurrent or metastatic HNSCC PF-based chemotherapy has been the standard of care for the past 30 years, which, despite having high response rates in comparison to other regimens (31-32%, vs. 10-17% with single-agent chemotherapy), does not significantly improve progression-free or overall survival [31]. In metastatic HNSCC prognosis is usually extremely unfavourable, with median overall survival of 6-8 months, despite administered treatment. Because in the recent years no real progress has been made towards improving the treatment options for patients with recurrent/metastatic HNSCC, this group can potentially benefit the most from the development of new molecular therapies targeting the EGFR [32]. Recently, novel molecular therapies targeting the EGFR were introduced for the treatment of recurrent/metastatic HNSCC.

The epidermal growth factor receptor belongs to the receptor tyrosine kinases (RTKs) family. Like all RTKs, it is a transmembrane protein which, when activated, phosphorylates tyrosine residues in various proteins, initiating intracellular signal transduction pathways (such as the RAS/RAF/MAPK and PI3K/AKT/mTOR pathways). EGFR is activated by a ligand (EGF or TGF alpha) binding to its extracellular domain, which results in receptor dimerisation and autophosphorylation, and activation of effector proteins, leading to increased cell proliferation and angiogenesis, as well as inhibition of apoptotic signalling. EGFR is expressed in nearly all cases of HNSCC. Overexpression of EGFR in HNSCC is usually a poor prognostic factor [33].

Cetuximab is a chimeric (mouse/human) monoclonal IgG1 antibody against the EGFR. It targets the extracellular domain of the EGFR, binding to it with higher affinity than the native ligand and blocking the tyrosine - kinase mediated signalling pathways. While there is some evidence that cetuximab facilitates the killing of cancer cells by mobilising natural killer cells and macrophages and inducing antibody - dependent cellular cytotoxicity [34] studies are ongoing to assess the interaction of cetuximab with immunity.

In a 2005 study Burtneš et al. proved that the addition of cetuximab to platinum based chemotherapy improved response rates (26% v. 10%) and progression free survival (4.2 v. 2.7 months) in patients with metastatic HNSCC. There was no significant improvement in median overall survival rates [35]. However, a randomised phase III EXTREME trial recruiting 422 patients, published in 2008 by Vermorken et al. combination of cetuximab with PF chemotherapy resulted in longer overall median survival (10.1 months in the experimental arm v. 7.4 in the control arm; hazard ratio for death, 0.80; 95% confidence interval, 0.64 to 0.99; P = 0.04). Response rates and progression free survival were also improved in the cetuximab arm. The results of this trial led the FDA and the EAMA to approve cetuximab for the first-line treatment of recurrent/metastatic HNSCC, in combination with PF chemotherapy [36,37]. Another study, published in 2005, suggests that in HNC patients with recurrent or metastatic disease, not responding to standard chemotherapy, the inclusion of cetuximab improved the response rates and median survival. Vermorken, Herbst, and Baselga conducted a retrospective cohort study, comparing the survival rates of 151 patients who had progressed on a first-line chemotherapy regimen, and received chemotherapy, radiotherapy or chemoradiation as second-line treatment, with patients receiving cetuximab (in monotherapy or combined with cisplatin), and found that cetuximab improved median survival in this group by more than 50% (5.2 - 6.1 months v. 3.4 months). Moreover, the response rates were similar in patients treated with cetuximab/cisplatin and cetuximab in monotherapy, which suggests that in the second-line treatment of metastatic HNSCC cetuximab, can be used as a single agent, thus reducing the adverse effects [38].

The described patient developed distant metastases to the subcutaneous tissue 9 months after RT-CT cessation. Cetuximab combined with PF chemotherapy for the first-line treatment of metastatic HNSCC is the current standard of care in Poland. However, at the time when the patient was treated, cetuximab-based therapy was novel and expensive, thus special consent from health service reinforcement institution had to be obtained. It was the reason for the delay of cetuximab administration. After the initiation of cetuximab therapy, the patient survived almost 9 months, which, considering the poor prognosis associated with subcutaneous metastases, supports the effectiveness of cetuximab in similar cases.

Conclusions

The most typical oropharyngeal cancer is squamous cell carcinoma. Methods of treatment in this type of cancer are standardised for typical cases, and include primary surgery, followed by radiation/chemoradiation, primary chemoradiation, induction chemotherapy followed by chemoradiation or radiotherapy combined with cetuximab. Introducing molecular targeted therapy has brought a significant improvement to the treatment of oropharyngeal squamous cell carcinoma, and can be considered a success in prolonging the survival of patients suffering from HNSCC. However, there are still remarkably few viable treatment options for patients with recurrent or metastatic disease and survival rates continue to be very low. Moreover, currently used standardised regimens may fail to elicit a response in patients with heterogenic or non-SCC tumours, like mucoepidermoid carcinoma or adenoid cystic carcinoma. Therefore, it is essential to continue research on rare cases of oropharyngeal carcinoma, in order to determine new therapeutic options. The search for new solutions should be focused, in particular, around molecular targeted therapy, as it has immense potential and one day might bring new possibilities of managing atypical cases of oropharyngeal cancer.

Competing Interests

The authors declare that they have no competing interests.

Authors' Contributions

ES, MW supervised and coordinated the study, assisted with analyses and revised the manuscript. AM, JM, AF and AD carried out the acquisition of data, literature review and prepared the drafts of the manuscript. All authors read and approved the final manuscript.

Acknowledgements

The authors would like to extend their gratitude to the patient's family for giving consent, to Professor Lech Zimnoch, MD, Department of Pathomorphology, Medical University of Białystok, for preparing histopathology reports, and to Dr. Luiza Kańczuga-Koda, MD, Department of Pathology, Białystok Oncology Centre, for her help in assessment of histopathology reports. The authors also would like to thank to Professor Eugeniusz Tarsów, MD, Department of Radiology, Medical University of Białystok, for his assistance in preparing the radiological images for publication, and Dr. Stefan Jelski, MD, Department of Diagnostic Imaging, Białystok Oncology Centre, for his help in preparing the radiological images for publication.

References

1. Wojciechowska U, Didkowska J Malignant neoplasms in Poland - incidence and mortality. National Cancer Registry, Cancer Center, M Skłodowska-Curie Institute.
2. Galbiatti ALS, Padovani-Junior JA, Maniglia JV, Rodrigues CDS, Pavarino EC, et al. (2013) Head and neck cancer: causes, prevention and treatment. *Braz J Otorhinolaryngol* 79: 239-247.
3. Cripps C, Winquist E, Devries MC, Stys-Norman D, Gilbert R, et al. (2010) Epidermal growth factor receptor targeted therapy in stages III and IV head and neck cancer. *Curr Oncol* 17: 37-48.
4. Halperin EC, Wazer DE, Perez CA, Brady LW (2013) *Perez and Brady's principles and practice of radiation oncology*. (6th edn), Lippincott Williams & Wilkins.

5. Jung AC, Job S, Ledrappier S, Macabre C, Abecassis J, et al. (2013) A poor prognosis subtype of HNSCC is consistently observed across methylome, transcriptome, and miRNome analysis. *Clin Cancer Res* 19: 4174-4184.
6. Ferlito A, Shaha AR, Silver CE, Rinaldo A, Mondin V (2001) Incidence and sites of distant metastases from head and neck cancer. *ORL J Otorhinolaryngol Relat Spec* 63: 202-207.
7. Siddiqui F, Gwede CK (2012) Head and neck cancer in the elderly population. *Semin Radiat Oncol* 22: 321-333.
8. Specenier P, Vermorken JB (2013) Cetuximab: its unique place in head and neck cancer treatment. *Biologicsv* 7: 77-90.
9. Bonner JA, Harari PM, Giralt J, Azarnia N, Shin DM, et al. (2006) Radiotherapy plus cetuximab for squamous-cell carcinoma of the head and neck. *N Engl J Med* 354: 567-578.
10. Green LK, Gallion TL, Gyorkey F (1991) Peripheral mucoepidermoid tumor of the lung. *Thorax* 46: 65-66.
11. Jarvis SJ, Giangrande V, Brennan PA (2013) Mucoepidermoid carcinoma of the tonsil: a very rare presentation. *Acta Otorhinolaryngol Ital* 33: 286-288.
12. Bai S, Clubwala R, Adler E, Sarta C, Schiff B, et al. (2013) Salivary mucoepidermoid carcinoma: a multi-institutional review of 76 patient. *Head Neck Pathol* 7: 105-112.
13. Chen MM, Roman SA, Sosa JA, Judson BL (2014) Histologic grade as prognostic indicator for mucoepidermoid carcinoma: A population-level analysis of 2400 patients. *Head Neck* 36: 158-163.
14. Aro K, Leivo I, Mäkitie AA (2008) Management and outcome of patients with mucoepidermoid carcinoma of major salivary gland origin: a single institution's 30-year experience. *Laryngoscope* 118: 258-262.
15. Yen A, Sanchez RL, Fearneyhough P, Tschen J, Wagner Jr RF (1997) Mucoepidermoid carcinoma with cutaneous presentation. *J Am Acad Dermatol* 37: 340-342.
16. Alvi, A, Johnson JT (1997) Development of distant metastasis after treatment of advanced-stage head and neck cancer. *Head Neck* 19: 500-505.
17. Sesterhenn AM, Albers MB, Timmesfeld N, Werner JA, Wiegand S (2013) Dermal metastases in squamous cell carcinomas of the head and neck. *Head Neck* 35: 767-771.
18. Pitman KT, Johnson JT (1999) Skin metastases from head and neck squamous cell carcinoma: Incidence and impact. *Head Neck* 21: 560-565.
19. Yoskovitch A, Hier MP, Okrainec A, Black MJ, Rochon L (2001) Skin metastases in squamous cell carcinoma of the head and neck. *Otolaryngol Head Neck Surg* 124: 248-252.
20. Fordice J, Kershaw C, El-Naggar A, Goepfert H (1999) Adenoid cystic carcinoma of the head and neck predictors of morbidity and mortality. *Arch Otolaryngol Head Neck Surg* 125: 149-152.
21. Spiro RH (1997) Distant metastasis in adenoid cystic carcinoma of salivary origin. *Am J Surg* 174: 495-498.
22. Di Palma S, Fehr A, Danford M, Smith C, Stenman G (2014) Primary sinonasal adenoid cystic carcinoma presenting with skin metastases-genomic profile and expression of the MYB-NFIB fusion biomarker. *Histopathology* 64: 453-455.
23. Jedrych J, Galan A (2013) Multiple cutaneous metastases: a rare and late sequelae of lacrimal gland adenoid cystic carcinoma. *J Cultan Pathol* 40: 341-345.
24. Nakamura M, Miyachi Y (1999) Cutaneous metastasis from an adenoid cystic carcinoma of the lacrimal gland. *Br J Dermatol* 141: 373-374.
25. Chang CH, Liao YL, Hong HS (2003) Cutaneous metastasis from adenoid cystic carcinoma of the parotid gland. *Dermatol Surg* 29: 775-779.
26. Perez DE, Magrin J, de Almeida OP, Kowalski LP (2007) Multiple cutaneous metastases from a parotid adenoid cystic carcinoma. *Pathol Oncol Res* 13: 167-169.
27. Bedi GC, Westra WH, Gabrielson E, Koch W, Sidransky D (1996) Multiple head and neck tumors: evidence for a common clonal origin. *Cancer Res* 56: 2484-2487.
28. Jain KS, Sikora AG, Baxi SS, Morris LG (2013) Synchronous cancers in patients with head and neck cancer: risks in the era of human papillomavirus-associated oropharyngeal cancer. *Cancer* 119: 1832-1837.
29. Koide N, Hamanaka K, Igarashi J, Hanazaki K, Adachi W, et al. (2000) Co-occurrence of mucoepidermoid carcinoma and squamous cell carcinoma of the esophagus: report of a case. *Surg Today* 30: 636-642.
30. Guo X, Li B, Li Y, Tian X, Li Z (2014) Unusual mucoepidermoid carcinoma of the liver misdiagnosed as squamous cell carcinoma by intraoperative histological examination. *Diagn Pathol* 9: 24.
31. Patel AN, Mehnert JM, Kim S (2012) Treatment of recurrent metastatic head and neck cancer: focus on cetuximab. *Clin Med Insights Ear Nose Throat* 5: 1-16.

-
32. Langer CJ (2008) Targeted therapy in head and neck cancer: state of the art 2007 and review of clinical applications. *Cancer* 112: 2635-2645.
 33. Hubbard SR, Miller TW (2007) Receptor tyrosine kinases: mechanisms of activation and signaling. *Curr Opin Cell Biol* 19: 117-123.
 34. Vermorken JB, Specenier P (2010) Optimal treatment for recurrent/metastatic head and neck cancer. *Ann Oncol* 7: 252-261.
 35. Burtneß B, Goldwasser MA, Flood W, Mattar B, Forastiere AA (2005) Phase III randomized trial of cisplatin plus placebo compared with cisplatin plus cetuximab in metastatic/recurrent head and neck cancer: an Eastern Cooperative Oncology Group study. *J Clin Oncol* 23: 8646-8654.
 36. Russell JS, Colevas AD (2012) The use of epidermal growth factor receptor monoclonal antibodies in squamous cell carcinoma of the head and neck. *Chemother Res Pract* 2012: 761518.
 37. Vermorken JB, Mesia R, Rivera F, Remenar E, Kaweckí A, et al. (2008) Platinum-Based Chemotherapy plus Cetuximab in Head and Neck Cancer. *N Engl J Med* 359: 1116-1127.
 38. Vermorken JB, Herbst RS, Leon X, Amellal N, Baselga J (2008) Overview of the efficacy of cetuximab in recurrent and/or metastatic squamous cell carcinoma of the head and neck in patients who previously failed platinum-based therapies. *Cancer* 112: 2710-2719.