



CASE REPORT

Methotrexate Induced Stevens-Johnson Syndrome: Two Cases Reports

I. Masmoudi¹, F. Baklouti^{1*}, N. Siala¹, YO. Yaye¹, A. Masmoudi² and A. Khanfir¹

¹Department of oncology, Habib Bourghuiba Hospital, Sfax, Tunisia

²Department of dermatology, Hedi Chaker Hospital, Sfax, Tunisia

*Corresponding author: F. Baklouti, Department of oncology, Habib Bourghuiba Hospital, Sfax, Tunisia



Abstract

Methotrexate induced Stevens-Johnson syndrome (SJS) is rare but life-threatening cutaneous reaction. This is a case report of two 14-year-old girls with methotrexate (MTX)-induced Stevens-Johnson syndrome (SJS). Both girls received chemotherapy with MTX in the treatment of osteosarcoma and then developed SJS. They showed cutaneous and mucosal erosions, macular and purplish rash, and ulceration in the cutaneous and mucosal areas. The full spectrum of all mucous membranes involved is less than 10% of the body surface area in the two patients.

The diagnosis of SJS is based on clinical features and there are no universally accepted diagnostic criteria. Prompt withdrawal of causative drugs should be a priority and the re-exposure of culprit drug is not recommended.

Corticosteroid at a dose of 1 mg / kg / day was administered to them and they both recovered from SJS. MTX is known as a drug that can induce SJS. So, it is rare but is not extremely rare.

Keywords

Stevens-Johnson Syndrome, Osteosarcoma, Methotrexate

Introduction

Methotrexate is a folic acid antagonist that inhibits the reduction in folate supply and the proliferation of tissue cells [1]. Since the proliferation of malignant cells is greater than that of normal cells, Methotrexate can slow their proliferation without causing irreversible damage to healthy tissue hence the interest of its use in the treatment of several neoplasms.

Methotrexate is a drug that must be used with caution due to its possible side effects such as inflammation of

the oral mucosa, blood-toxicity and disturbance of liver and kidney function [2]. Although its side effects are generally benign, there are some severe adverse effects such as Stevens-Johnson-Syndrome (SJS) which is a life-threatening mucocutaneous reaction rarely complicating Methotrexate administration [3,4]. We reported two cases of Steven-Johnson Syndrome induced by high dose Methotrexate as neoadjuvant chemotherapy for a high-grade osteosarcoma treated at the medical oncology department at CHU Habib Bourguiba Sfax, Tunisia. The two patients were treated according to the OS 2006 protocol. The treatment is based on high-dose Methotrexate cures (12 g/m²), each injection is followed by rescue treatment with folic acid and alkaline hyper hydration at weeks 1,2,3,7,8,12, and 13 and courses of Etoposide and Ifosfamide at weeks 4 and 9.

Case Report 1

The first patient is a 14-year-old girl, with no medico-surgical history; She is followed for an osteosarcoma of the upper extremity of the right humerus with pulmonary metastasis.

On the 7th day of the 7th week, the patient consulted with, plantar erythema grade 1 (Figure 1); grade 2 mucositis and periorbital erythema without conjunctival involvement (Figure 2). The biology exams noted 32 time's normalcytotoxicity and acute kidney failure. Methotrexate toxicity was suspected. The patient was treated with alkaline hyper hydration, rescue treatment with folic acid, and Fluconazole for her mucositis.

The evolution was marked by the aggravation of

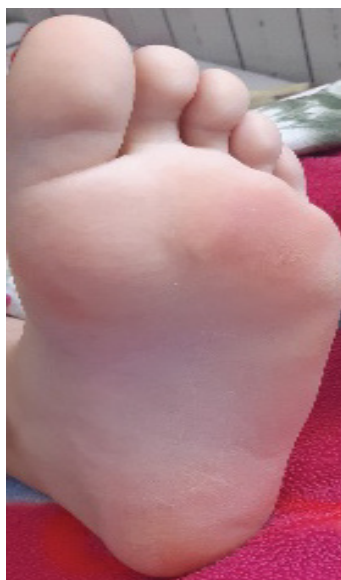


Figure 1: Planter erythema.

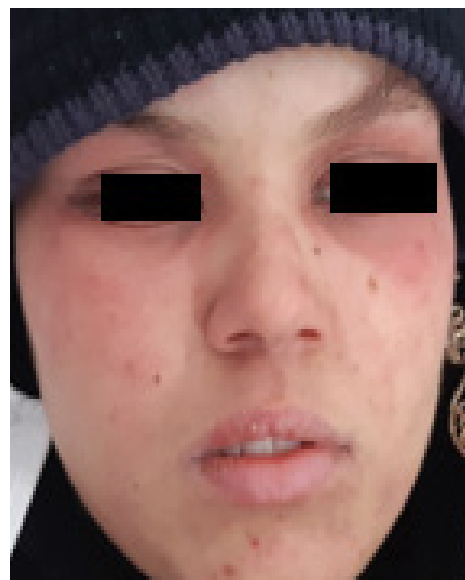
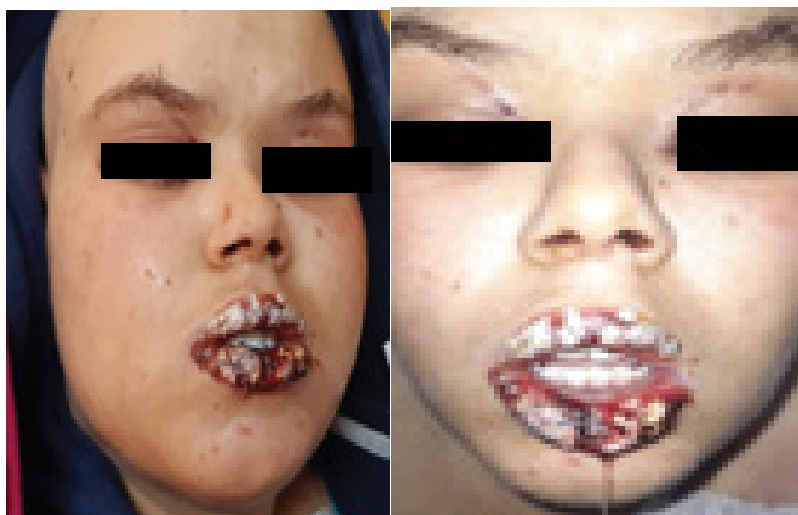
Figure 2: Periorbital erythema.



A

B

Figure 3: Erosive hemorrhagic cheilitis (a,b).

the symptoms. At the 12th day of chemotherapy, she presented erosive hemorrhagic cheilitis with multiple intraoral erosion (Figure 3), peri and endo-mammary erosions and crusts, a slight macular rash in the trunk (Figure 4), lesions cockade on the level of the backs of the hands (Figure 5) and painful perianal ulceration (Figure 6). At biology exams, we noted severe pancytopenia and a slight improvement in hepatic cytolysis.

The diagnosis of SJS was suspected and the contraindication to re-administration of Methotrexate has been decided. The patient received systemic corticosteroid therapy at a dose of 1 mg/kg/day with mouthwashes. Improvement of the symptomatology and a complete disappearance of the lesions 15 days after corticosteroid therapy initiation were noted.

Case Report 2

She is a 14-year-old girl with no medico-surgical history; she is followed for a localized osteosarcoma of the right femur. At the 10th day of the first cycle of high-dose Methotrexate, the patient consulted for fever, sore in the mouth and throat and cutaneous reaction. The clinical exam noted grade IV mucositis, skin erosion especially in the elbows (Figure 7), an ulceration in the lining of the mouth (Figure 8), a purplish rash in the limbs (Figure 9) and squamous lesions in the extremities (Figure 10). The biological exam showed grade IV neutropenia, hepatic cytolysis 9 times normal value and an acute renal failure.

The diagnosis of SJS was suspected associated with febrile neutropenia, hepatic, and renal toxicity due to

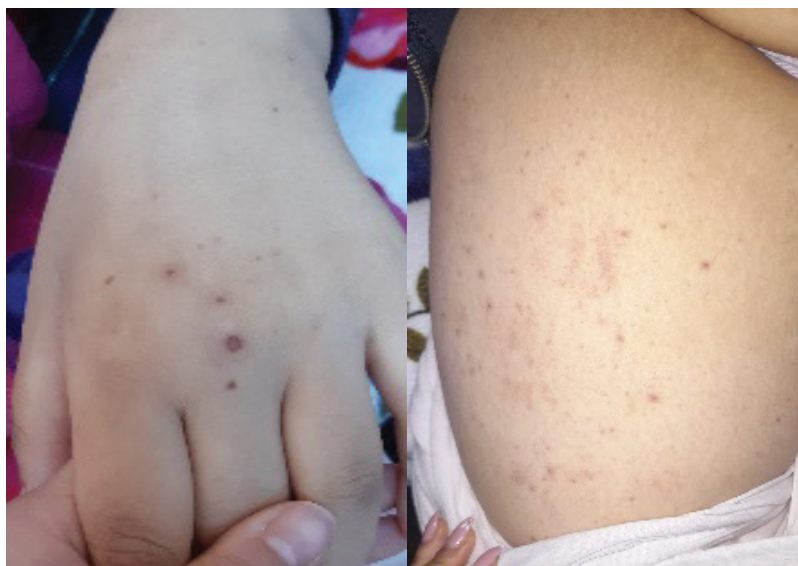

Figure 4: Lesions cockade on the level of the backs of the hands.

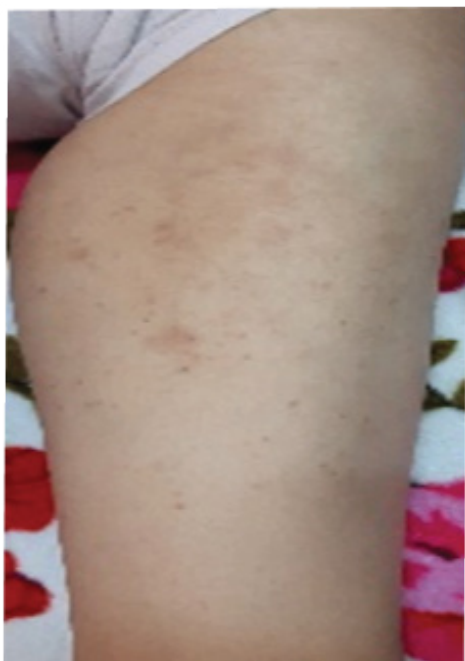

Figure 5: Macular rash.

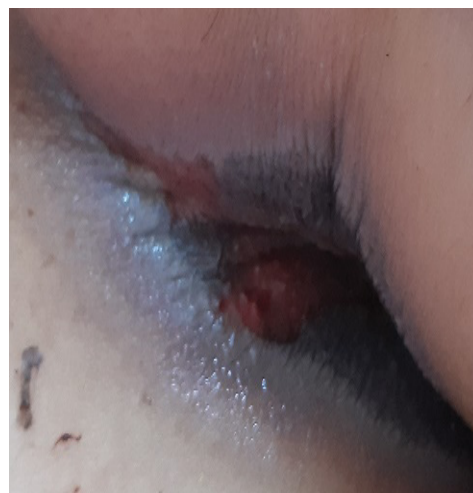

Figure 6: Perianal ulceration.

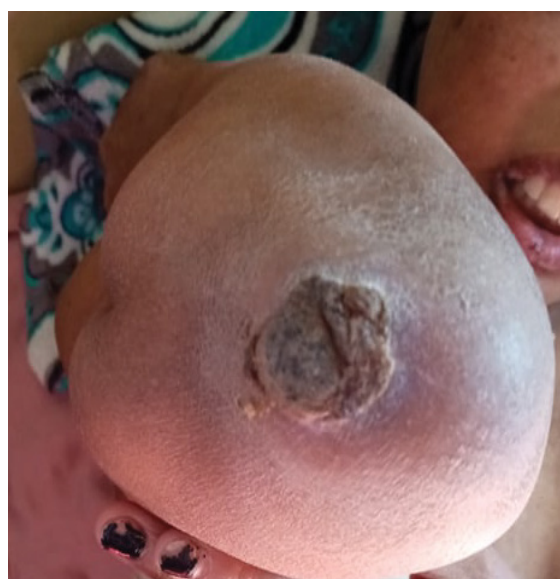

Figure 7: Elbow erosion.

Methotrexate chemotherapy. The patient was treated with broad spectrum antibiotherapy, corticosteroid at the dose of 1 mg/kg, mouth wash, alkaline hyperhydration and rescue with folic acid.

The evolution was characterized by the resolution of the lesions and the decision was to avoid the re-administration of Methotrexate and then the patient was referred for surgery of the primary tumor.

Discussion

Steven-Johnson Syndrome is a rare but life-threatening mucocutaneous reactions [5]. Recently, there is an increased number of reports being published on Methotrexate (MTX) related SJS. We report some of

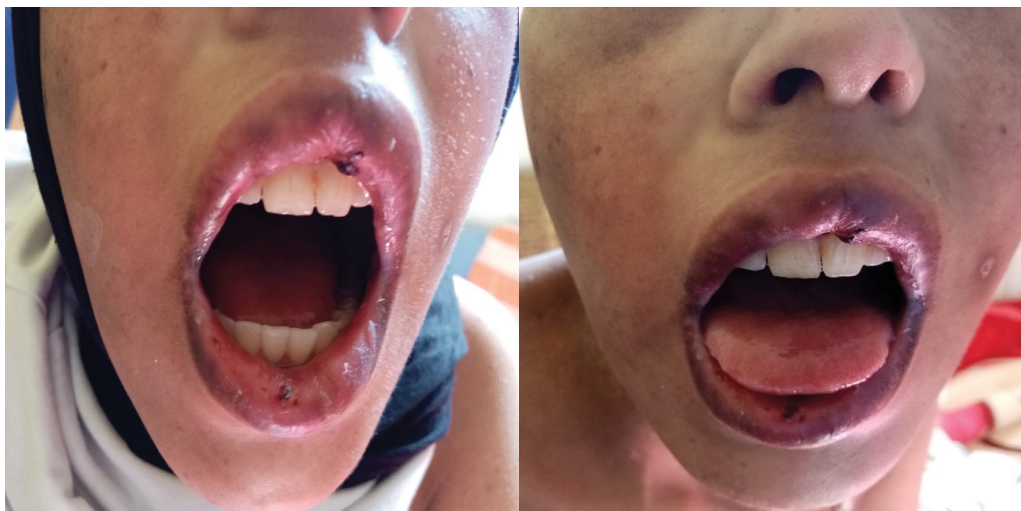

Figure 8: Ulceration in the mouth.

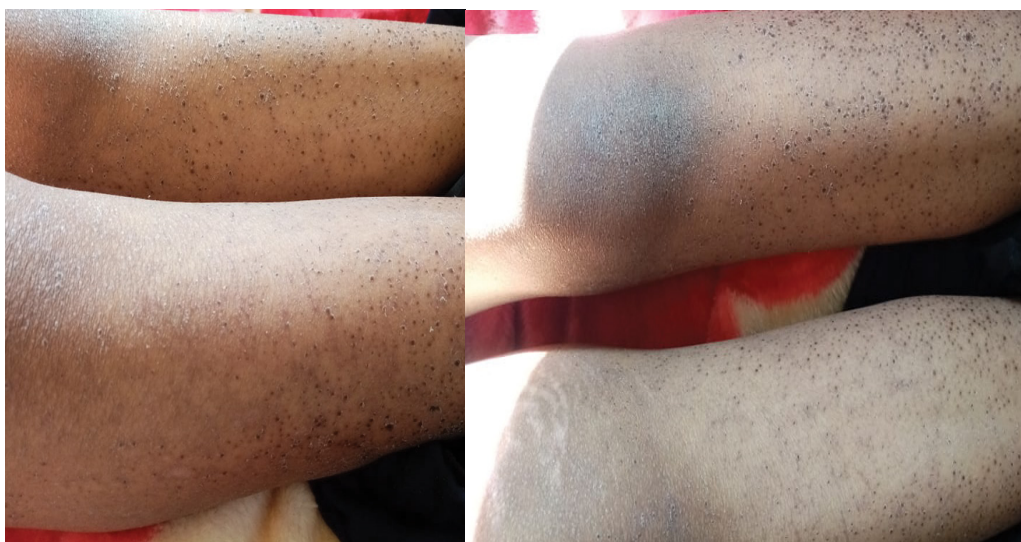

Figure 9: Purplish rash in the limb.

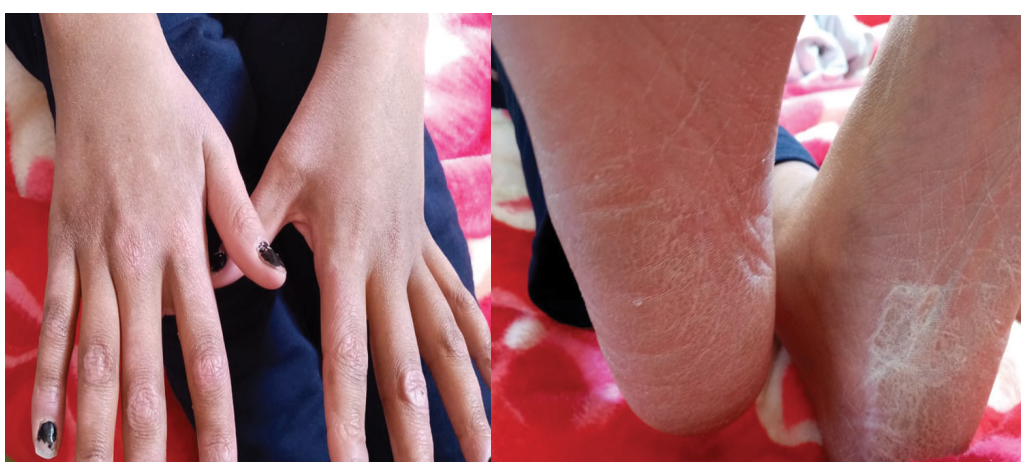

Figure 10: Squamous lesion in the extremities.

Table 1: Cases report of SJS related to MTX.

| Authors' name | Years of publication | The pathology treated by MTX |
|------------------------|----------------------|------------------------------|
| Chen, et al. [3] | 2017 | Psoriasis |
| Elboukhari, et al. [7] | 2018 | Hydatiforme mole |
| Akinci, et al. [6] | 2018 | Acute lymphoblastic leukemia |
| Arora, et al. [1] | 2018 | - |
| Cardon, et al. [8] | 2019 | Psoriasis |

these cases [1,3] [6-8] (Table 1).

Clinically, this syndrome is characterized by acute skin blisters, scalding of the skin, and mucous membrane erosions [6] [9-12]. The detachment spectrum is considered to be < 10% [13] in the SJS. The skin is often tender to the touch, with lateral pressure producing shedding of the epidermis from the dermis which is called as the Nikolsky's sign. Multiple organ systems such as cardiovascular, pulmonary, gastrointestinal, and urinary systems may be affected [1,3,6] [14-16].

Because of the mechanism of action of MTX, these cases are different than that of the "traditional" SJS. This syndrome is usually considered a hypersensitivity reaction [9,15,16], but with MTX it might be due to the fact that the actual cells in the basal layer are unable to reproduce at an adequate rate. Thus, widespread epidermal necrosis occurs as a result of keratinocytes' apoptosis. This apoptosis is caused by the binding of FAS (CD95), a membrane receptor present in keratinocytes, with its FAS ligand (CD95L) [9].

Drug exposure is the cause of large majority of cases. The most commonly implicated drugs are Allopurinol, Trimethoprim-Sulfamethoxazole and other Sulfonamide-antibiotics, Aminopenicillins, Cephalosporins, Quinolones, Carbamazepine, Phenytoin, non-steroidal anti-inflammatory drugs, and phenobarbital anticonvulsants [9,11,16,17].

Our two cases developed the full spectrum of the disease with involvement of all mucous membranes. The skin is involved in less than 10% of the body surface area. Steven-Johnson Syndrome-like exanthema in our two patients was related to Methotrexate administration. It occurred after fourth exposure to the drug in the first patient and the first exposure to the drug in the second one.

The severe cutaneous manifestations of this disease spectrum may often lead to overlooking of the ocular sequelae, which are very common and may lead to loss of visual acuity [18]. Fortunately, both patients had no symptoms of the eye (conjunctivitis). Diagnosis of Steven-Johnson Syndrome is based on clinical features and there are no universally accepted diagnostic criteria.

Prompt withdrawal of causative drugs should be a priority with early initiation of supportive treatment which includes monitoring of fluids and electrolytes, barrier nursing care, nutritional support and control

of infection [6]. Corticosteroids has been proposed as a treatment strategy [9,19,20]. The main mechanism of intended action is the modification of almost all components of the inflammatory and immune response. But the timing, corticosteroid type dosage and duration remain unclear. Our patients were treated with intravenous corticosteroids successfully.

Conclusion

Steven-Johnson Syndrome is rare clinical conditions with high mortality and morbidity rate. Early diagnosis and administering appropriate treatment may improve the prognosis. Although the re-exposure of culprit drug after SJS is not recommended. The main intention of these cases report of Methotrexate induced Steven-Johnson Syndrome is to make the clinicians as aware of this occurrence.

References

- Arora S, Abidi A, Fatima F, Hasan R, Rizvi D, et al. (2018) Methotrexate induced stevens johnson syndrome: A rare case report. *Eras J Med Res*.
- Howard SC, McCormick J, Pui CH, Buddington RK, Harvey RD (2016) Preventing and managing toxicities of high-dose methotrexate. *Oncologist* 21: 1471-1482.
- Chen TJ, Chung WH, Chen CB, Hui RY, Huang YH, et al. (2017) Methotrexate-induced epidermal necrosis: A case series of 24 patients. *J Am Acad Dermatol* 77: 247.e1-255.e2.
- Fouchard N, Bertocchi M, Roujeau JC, Revuz J, Wolkenstein P, et al. (2000) Scorten: A severity-of-illness score for toxic epidermal necrolysis. *J Invest Dermatol* 115: 149-153.
- Yang MS, Lee JY, Kim J, Kim GW, Kim BK, et al. (2016) Incidence of stevens-johnson syndrome and toxic epidermal necrolysis: A nationwide population-based study using national health insurance database in korea. *PLoS One* 11: e0165933.
- Akinci B, Sivis Z, Sahin A, Karapinar DY, Balkan C, et al. (2018) Stevens-johnson syndrome associated with methotrexate treatment for acute lymphoblastic leukemia: A case report. *Arch Argent Pediatr* 116: e459-e462.
- Elboukhari K, Rasso A, Bay Bay H, Elloudi S, Mernissi FZ (2018) Syndrome de stevens-johnson secondaire au méthotrexate : Une récidence accidentelle. *Ann Dermatol Vénérologie* 145: S144- S145.
- (2019) A case of methotrexate-induced epidermal necrosis. *J Am Acad Dermatol* 81: AB152.
- Harr T, French LE (2010) Toxic epidermal necrolysis and stevens-johnson syndrome. *Orphanet J Rare Dis* 5: 39.
- Tyagi S, Kumar S, Kumar A, Singla M, Singh A, et al. (2010)

- Stevens-johnson syndrome-a life threatening skin disorder: A review. *J Chem Pharm Res* 2 : 618-626.
11. Rachana PR, Anuradha HV, Mounika R (2015) Stevens johnson syndrome-toxic epidermal necrolysis overlap secondary to interaction between methotrexate and etoricoxib: A case report. *J Clin Diagn Res* 9: FD01- FD03.
 12. Schwartz RA, McDonough PH, Lee BW (2013) Toxic epidermal necrolysis: Part II. Prognosis, sequelae, diagnosis, differential diagnosis, prevention, and treatment. *J Am Acad Dermatol* 69: 187.e1-187.e16.
 13. Nowsheen S, Lehman JS, El-Azhary RA (2021) Differences between stevens-johnson syndrome versus toxic epidermal necrolysis. *Int J Dermatol* 60: 53-59.
 14. Dutt J, Sapra A, Sheth-Dutt P, Bhandari P, Gupta S (2020) Stevens-johnson syndrome: A Perplexing Diagnosis. *Cureus* 12: e7374.
 15. Lebrun-Vignes B, Bachelez H, Chosidow O (1999) Methotrexate and dermatology: Pharmacology, indication and practical use. *La Revue de Médecine Interne* 20: 384-392.
 16. Gerull R, Nelle M, Schaible T (2011) Toxic epidermal necrolysis and stevens-johnson syndrome: A review. *Crit Care Med* 39: 1521-1532.
 17. Mockenhaupt M, Viboud C, Dunant A, Naldi L, Halevy S, et al. (2008) Stevens-johnson syndrome and toxic epidermal necrolysis: Assessment of medication risks with emphasis on recently marketed drugs. The EuroSCAR-study. *J Invest Dermatol* 128: 35-44.
 18. Abrol A, Gulanikar A, Thakre S, Patel A (2020) Study of ocular manifestations of stevens-johnson syndrome/toxic epidermal necrolysis. *Indian Dermatol Online J* 11: 570-574.
 19. Yang Y, Xu J, Li F, Zhu X (2009) Combination therapy of intravenous immunoglobulin and corticosteroid in the treatment of toxic epidermal necrolysis and stevens-johnson syndrome: A retrospective comparative study in china. *Int J Dermatol* 48: 1122-1128.
 20. Dermatoigy BJ, Departmetit U, Fp F, Oe A, Fa R caro, et al. (1987). *British Jourmi of Dermatoigy* 128 : 357-360.