



CASE REPORT

Anesthesia and Multidisciplinary Team Management throughout the Exit Procedure and Excision of a Huge Congenital Cervical Teratoma: A Case Report


Turki Almalki¹, Muteb AlOtaibi², Mohamed A Daabiss^{1*}  Sohil Imran¹ and Basmah kaabi³

¹Consultant Neonatal Anesthetist, Prince Sultan Military Medical City, Riyadh, Saudi Arabia

Consultant Anesthetist, Prince Sultan Military Medical City, Riyadh, Saudi Arabia

³Anaesthesia Technologist at Prince Sultan Military Medical City, Riyadh City, Saudi Arabia

*Corresponding author: Dr. Mohamed A Daabiss, Department of Anesthesia, Prince Sultan Military Medical City, Riyadh, Saudi Arabia, Tel: +966508979594



Abstract

Background: The EXIT procedure, or Ex-Utero intrapartum treatment, is a specialized intervention conducted alongside a cesarean section. This approach aims to maintain fetal-placental circulation, ensuring secure management of fetal airways and minimizing the risk of airway obstruction during delivery.

Case presentation: A 33-year-old woman, her regular Prenatal Ultrasound at 29th-week gestation showed a fetus with a huge left neck mass. Ex-Utero intrapartum treatment (EXIT) procedure to the airway was the choice as a treatment that required multidisciplinary team support. Subsequently, the surgical excision of the infant neck teratoma was performed after three months with the same multiple subspecialties team. Intraoperatively, the procedures were carried out smoothly and uneventfully under multidisciplinary care. In the postoperative phase, the patients recovered in good condition and were afterward discharged with routine follow-up. This report details the unique cooperation of a multidisciplinary team throughout the EXIT procedure for airway and neck teratoma excision.

Conclusion: The EXIT procedure is conducted for cases involving fetal congenital malformation. The anesthetic management for this procedure presents heightened challenges, as it requires achieving profound uterine relaxation, ensuring the maintenance of uteroplacental blood flow, and providing fetal anesthesia.

Keywords

EXIT procedure, Neck teratoma, Multidisciplinary team, Airway management

Abbreviations

EXIT: The Ex-Utero Intrapartum Treatment Procedure;
MRI: Magnetic Resonance Imaging

Background

The EXIT procedure is a rare surgical technique employed for the management of fetal airway anomalies. Its initial description in 1989 involved addressing complete tracheal obstruction caused by a prenatally diagnosed cervical teratoma [1]. The main purpose of the EXIT procedure is to ensure a safe and stable maternal clinical condition during the procedure while preserving foetal-maternal circulation [2]. The implementation of the EXIT procedure has led to a reduced mortality rate, with an overall survival rate of 83% [3].

Case Presentation

During a routine prenatal ultrasound examination, a huge fetal neck mass was detected in a 33-year-old woman who is currently in the 29th week of gestation. Further evaluation through Magnetic Resonance Imaging revealed the size of this mass to be 9.7 × 9 × 10.5 cm. The mass extends upward and downward, causing significant airway constriction due to external compression. This results in the displacement of the airway towards the right side, leading to the reshaping of the mandible and facial bone.

A team of specialists including neonatal and obstetric anesthesiologists, obstetricians, an otolaryngologist, a neonatologist, and a radiologist convenes an urgent meeting to strategize and coordinate the best management before unexpected labor. An EXIT-to-airway procedure was scheduled, with direct laryngoscopy as the initial approach for intubation to obtain airway patency. An algorithm for intubation was drawn in the meeting by an anesthesiologist and otolaryngologist.

During the 36th week of pregnancy, the mother and her fetus were scheduled for a cesarean section and an Exit procedure. Once Informed Consent was obtained, a simulation exercise involving the procedure team was conducted in the operating room. The team leader, who was the neonatal anesthesiologist, assigned specific roles to each team member.

For the EXIT procedure to be successful, a large multidisciplinary team of around twenty people is required. To accommodate this, two separate teams were formed for each patient, each with their anesthesiologist, surgeons, anesthesia technician, and circulating and scrub nurses. During the anesthesia phase, the mother was fully monitored (invasive and non-invasive). Additionally, warm fluid was administered through a large peripheral venous line to maintain the mother's body temperature, and 2 units of RBC were prepared for potential use. The obstetric anesthesiologist premedicated the mother with Metoclopramide 10 mg IV, and Pantoprazole 40 mg IV. The patient was pre-oxygenated with FiO₂ 100% for 3 minutes. Induction of general anesthesia using intravenous medication; fentanyl 1 mcg/kg, propofol 2 mg/kg, and rocuronium 0.6 mg/kg in a rapid sequence manner with cricoid pressure technique. The addition of remifentanyl infusion (0.1-0.3 mcg/kg/min) reduced the necessary minimum alveolar concentration (MAC) of sevoflurane. The combination of medications and techniques ensured adequate depth of anesthesia and uterine relaxation for the mother. Subsequently, the administration of nitroglycerine began with an intravenous bolus of 100 mcg given twice, followed by a continuous infusion of 1 mcg/kg/min. Continuous administration of phenylephrine was utilized to maintain the mother's blood pressure. The placement of a central venous line is considered safe to facilitate the administration of vasoactive drugs and blood transfusions.

After the Lower uterine segment incision only the infant's head and neck were pulled out carefully with the right arm. During the procedure, the rest of the infant's body remained inside the uterus. The anesthesia team applied a sterile pulse oximeter device to the dorsum of the infant's right hand, and the neonatal anesthetist administered atropine 100 mcg and ketamine 4 mg intramuscularly to facilitate intubation before clamping the cord. On the other hand, the neonatal anesthetist,

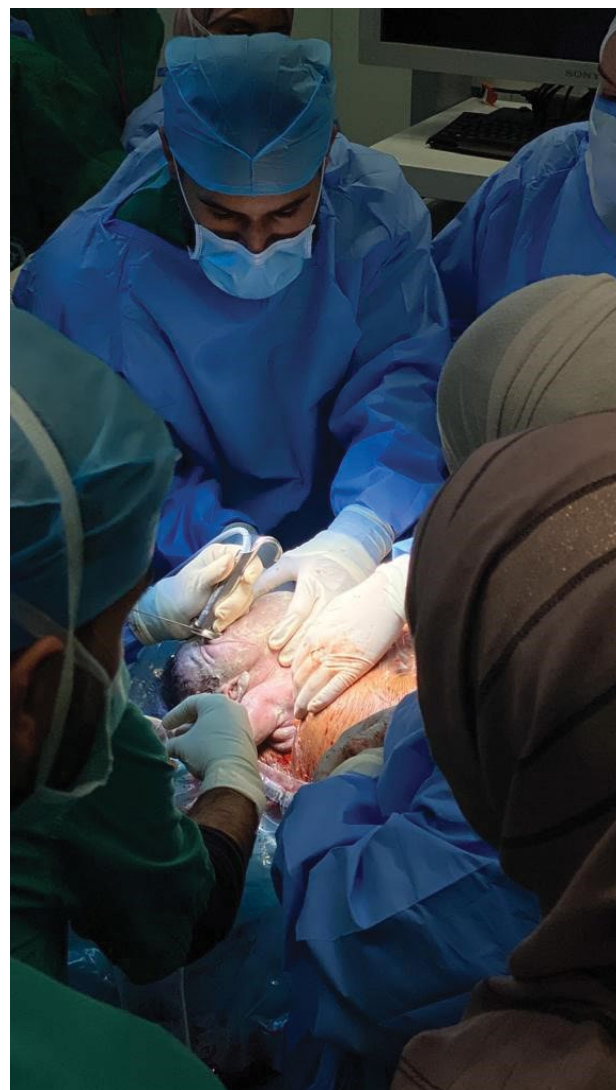

Figure 1: Intubating the baby while the head, neck, and right arm were extracted from the uterus.

the neonatologist, and the otolaryngologist prepared a rigid scope size 2.7 mm and ETT size 3.0 shaped with stylite, with different types of intubation devices ready if rigid scope intubation failed. However, the ETT was inserted smoothly, followed by ambo-bag ventilation (Figure 1).

After clamping the cord, the infant was completely delivered outside the mother's uterus. While the baby was being continuously ventilated, the neonatologist examined and transferred the baby to the NICU unit using sedation infusions (fentanyl 5 mcg/kg/hr + midazolam 100 mcg/kg/hr), inotropes (epinephrine 0.03 mcg/kg/hr + dobutamine 4 mcg/kg/min), and ventilation on AC mode with rate = 55, PIP 17/6, and FIO₂ 25% (Figure 2). The entire process, commencing with the extraction of the head, was efficiently concluded within 12 minutes. Following the confirmation of the correct placement of the endotracheal tube, the umbilical cord was clamped, and the anesthesiologist's attention shifted from uterine relaxation to uterine tone. To ensure proper uterine tone, the administration of nitroglycerine and phenylephrine was discontinued,

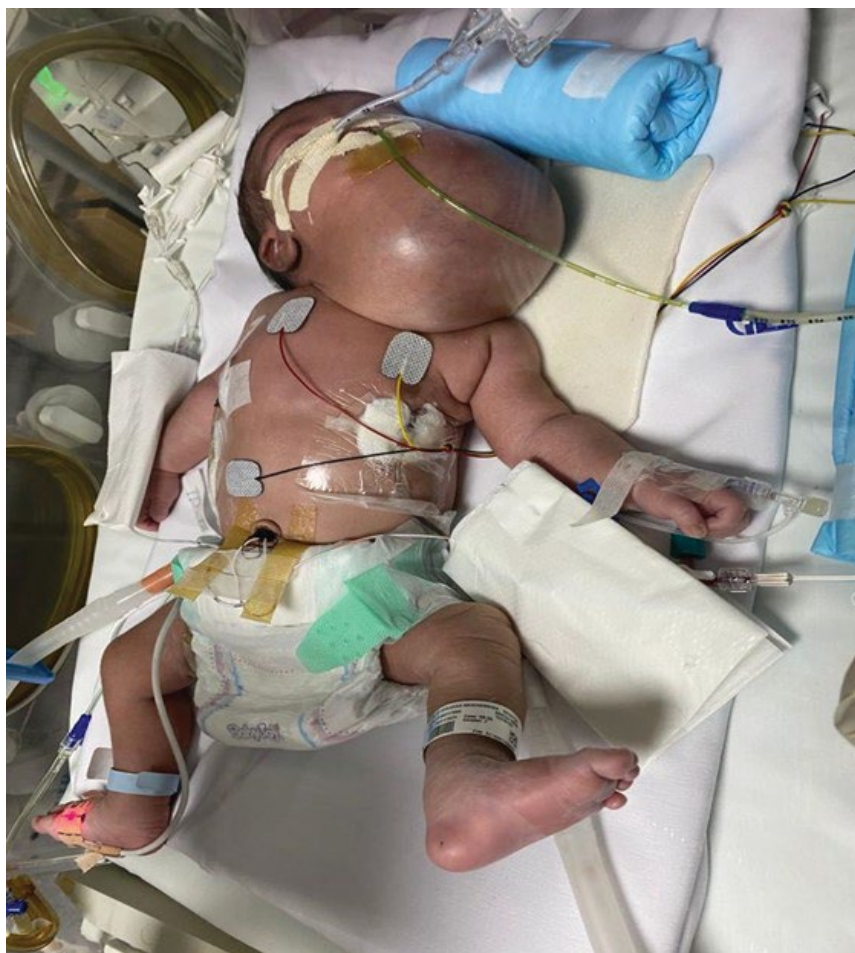

Figure 2: The baby in the NICU incubator after delivery.

and oxytocin and postoperative nausea and vomiting prophylaxis (PONV) were initiated. The placenta was then removed, and the cesarean section was completed without any complications. The estimated total blood loss was approximately 600 ml, and the postpartum period progressed without any notable incidents.

The same team that performed the EXIT procedure held a meeting three months later to plan the scheduling of neck teratoma dissection surgery. On the day of the procedure, the operating team received the patient already intubated and ventilated from the NICU. The anesthesia team prepared the anesthesia workplace and inserted invasive monitors for femoral arterial blood pressure, central venous pressure, and core temperature monitoring. The mass was dissected smoothly in a subcapsular manner, and the left Recurrent Laryngeal Nerve was identified and preserved, as was the common carotid artery. After the surgery, the anesthesia team reintubated the patient using a video laryngoscope with an ETT size of 3.5, and the patient was then transferred to the NICU in a well-ventilated condition.

Discussion

The EXIT procedure requires comprehensive preparation and coordination. The initial task of the medical team is to precisely describe the issue and

identify any malformations that may be associated with the condition.

In the 36th week of gestation, a cesarean section and an EXIT procedure were planned for the mother. The EXIT procedure is typically performed between 33 and 39 weeks of gestation, depending on the fetal indications and the gestational age required for delivery.

The surgical approach involves partially delivering the fetus during a cesarean section to secure the fetal airway while maintaining fetal oxygenation through placental perfusion. It has also been referred to as "operation on a placental support (OOPS)" [4].

The anesthetic management required for the EXIT procedure presents unique and significant challenges compared to a standard cesarean section. It involves achieving profound uterine relaxation, preserving uteroplacental blood flow, and administering anesthesia specifically tailored for the fetus [4,5].

In the majority of EXIT procedures, general anesthesia with a volatile anesthetic agent is typically employed during cesarean sections. However, it is crucial to balance this with the need to maintain normal maternal blood pressure and avoid compromising uterine blood flow. While both ephedrine and phenylephrine can be used for this purpose, recent studies suggest a

preference for phenylephrine due to its lower placental transfer than ephedrine [6].

While inhalational anesthetics can effectively provide fetal anesthesia through placental transfer, researchers have explored other methods as well. These include the use of intramuscular injections of anesthetics, opioids, muscle relaxants, and atropine as premedication to optimize fetal anesthesia conditions [7]. For instance, in the study conducted by George, et al., intramuscular ketamine was administered for fetal anesthesia [8]. Furthermore, remifentanyl rapidly traverses the placenta, ensuring effective fetal immobilization, and is swiftly metabolized by fetal nonspecific blood and tissue esterase [5].

Doctors' familiarity with airway equipment is crucial, and it is essential to discuss the scenario in advance. Advanced airway interventions, including rigid bronchoscopy, retrograde intubation, and tracheostomy, have been reported as feasible options [9]. In our case, the intubation strategy was based on the otolaryngologist's familiarity and experience. Additionally, alternative intubation devices were prepared as backups in case the rigid scope intubation was unsuccessful. During the EXIT procedure, it is essential to monitor fetal pulse oximetry. Although measuring it can be challenging, one approach is to wrap the pulse oximeter in foil and place it on either fetal hand. This helps minimize interference from bright lights in the operating room and allows for continuous monitoring of oxygen saturation levels.

In the event of possible fetal distress, the anesthesiologist should notify the surgeon and take several steps to address the situation. These include increasing maternal inspired oxygen, optimizing uteroplacental circulation by maintaining maternal blood pressure and heart rate, ruling out aortocaval compression, and achieving uterine relaxation despite uterine contractions. Surgeons should also consider repositioning the fetus to alleviate potential umbilical cord compression and ruling out placental abruption. If fetal distress persists, fetal resuscitation measures must be initiated.

Traditional techniques to maintain anesthesia and adequate uterine relaxation require the administration of 2-3 MAC of volatile agents, which may cause maternal hypotension and placental hypoperfusion, as well as direct fetal cardiovascular depression. The EXIT procedure requires a unique anesthetic management approach that presents significant challenges compared to a standard cesarean section. The procedure involves achieving profound uterine relaxation, preserving uteroplacental blood flow, and administering anesthesia tailored specifically for the fetus [10]. Alternative techniques, such as propofol and remifentanyl intravenous infusions in combination with lower doses of volatile agents, have been explored for the EXIT

procedure. Nitroglycerine is an effective medication for maintaining uterine relaxation and placental perfusion and preventing placental separation during the EXIT procedure [11].

Conclusion

The EXIT procedure is a valuable intervention for a fetus diagnosed with cervical teratoma, requiring early and accurate prenatal diagnosis and an experienced multidisciplinary team. Anesthesia management is challenging and requires an individualized selection of techniques to ensure the best outcome for both the fetus and the mother.

Declarations

Ethics approval and consent to participate

Written informed consent was obtained from the patient to publish this case report and accompanying images.

Consent for publication

All authors agreed to publish this article once the review was approved.

Availability of data and material

All data and materials are available in the repository upon request.

Competing interests

None.

Funding

None.

Authors' contributions

M AlOtaibi, T Almalki, and S Imran analyzed and prepared the patient data. M Daabiss was the major contributor to writing the manuscript. All authors read and approved the final manuscript.

Acknowledgement

We want to convey our sincere gratitude to Basmah Kaabi, anesthesia technologist for her active participation and contribution to data gathering for this case report.

References

1. Woosuk C, Chaeseong L (2021) Intraoperative management for ex-utero intrapartum treatment: Focusing on the fetus. *Anesth Pain Med (Seoul)* 16: 329-337.
2. García-Díaz L, Chimenea A, de Agustín JC, Pavón A, Antiñolo G (2020) Ex-utero intrapartum treatment (EXIT): Indications and outcome in fetal cervical and oropharyngeal masses. *BMC Pregnancy Childbirth* 20: 598.
3. Marina S, Simone G, Ricciarda R, Roberto D, Mariachiara B, et al. (2021) The ex-utero intrapartum treatment (EXIT) procedure: Case report of a multidisciplinary team approach. *Acta Biomed* 92: e2021142.

4. Rajkumar S, Pallavi M, Rajeshwari S, Sumit B (2018) Role of anesthesiologist in ex utero intrapartum treatment procedure: A case and review of anesthetic management. *J Anaesthesiol Clin Pharmacol* 34: 148-154.
5. Kumar K, Miron C, Singh SI (2019) Maternal anesthesia for EXIT procedure. A systematic review of literature. *J Anaesthesiol Clin Pharmacol* 35: 19-24.
6. Chooi C, Cox JJ, Lumb RS, Philippa M, Mark C, et al. (2020) Techniques for preventing hypotension during spinal anaesthesia for caesarean section. *Cochrane Database Syst Rev* 7: CD002251.
7. Chinnappa V, Halpern SH (2007) The ex utero intrapartum treatment (EXIT) procedure: Maternal and fetal considerations. *Can J Anaesth* 54: 171-175.
8. George RB, Melnick AH, Rose EC, Ashraf SH (2007) Case series: Combined spinal epidural anesthesia for cesarean delivery and ex utero intrapartum treatment procedure. *Can J Anaesth* 54: 218-222.
9. Chatterjee D, Arendt KW, Moldenhauer JS, Olutoyin A O, Jagroop M, et al. (2021) Anesthesia for maternal-fetal interventions: A consensus statement from the American Society of Anesthesiologists Committees on Obstetric and Pediatric Anesthesiology and the North American Fetal Therapy Network. *Anesth Analg* 132: 1164-1173.
10. Ngamprasertwong P, Vinks AA, Boat A (2012) Update in fetal anesthesia for the ex utero intrapartum treatment (EXIT) procedure. *Int Anesthesiol Clin* 50: 26-40.
11. Dinges E, Heier J, Delgado C, Bollag L (2019) Multimodal general anesthesia approach for ex utero intrapartum therapy (EXIT) procedures: Two case reports. *Int J Obstet Anesth* 38: 142-145.