



An Uncommon Cause of Skin Discoloration: Purpura Pigmentosa Progressiva

Charles Joseph Haddad*, Judella Haddad Lacle and Charles Michael Haddad

Department of Community Health and Family Medicine, University of Florida, USA

*Corresponding author: Charles Joseph Haddad M.D, Associate Professor, University of Florida, Department of Community Health and Family Medicine, USA, E-mail: chaddad2@bellsouth.net

Abstract

Purpura Pigmentosa Progressiva is also known as Progressive Pigmentary Dermatitis or Schamberg's Disease. It is a disorder causing skin discoloration on the trunk and extremities, and is a lymphocytic capillaritis of unknown etiology. The disease can occur at any age. It is important to be aware of this disorder since it can mimic other diseases and problems including child and elder abuse, thrombocytopenia purpura. The etiology of the disorder is unknown but there appears to be cell mediated immune mechanism. Diagnosis of this disorder is through normal platelet and clotting studies with definitive diagnosis being made by biopsy revealing a typical histological pattern.

There is no cure for Purpura Pigmentosa Progressiva and treatment is based on the severity of symptoms and may include watchful waiting, topical corticosteroids, as well as other systemic therapies. This case describes a 61 years old female with recurring purple lesions lasting for months and resolving spontaneously.

Keywords

Purpura Pigmentosa Progressiva, Progressive Pigmentary Dermatitis, Schamberg's Disease, Lymphocytic Capillaritis

Introduction

Purpura Pigmentosa Progressiva is a disorder causing skin discoloration especially of the trunk and extremities. It is caused by lymphatic capillarities of unknown etiology. The diagnosis is made by historical characteristics, lack of trauma, normal clinical laboratory testing and vascular changes on biopsy.

Case Report

A 61-year-old white female presented to our primary care office with recurring purple lesions occurring on the arms, legs, and occasionally the trunk. The lesions usually occurred in these areas at different time periods. The discoloration lasted from several weeks to months and eventually resolved spontaneously.

At the time of presentation, skin exam revealed purpuric patches on the forearms bilaterally (Figure 1) that were non-palpable, non-tender, and did not blanch with pressure.

The patient denied trauma to the areas of discoloration and denied any other symptoms, except mild irritation, sensitivity, and itching of the areas affected. At the time of the biopsy, the patient

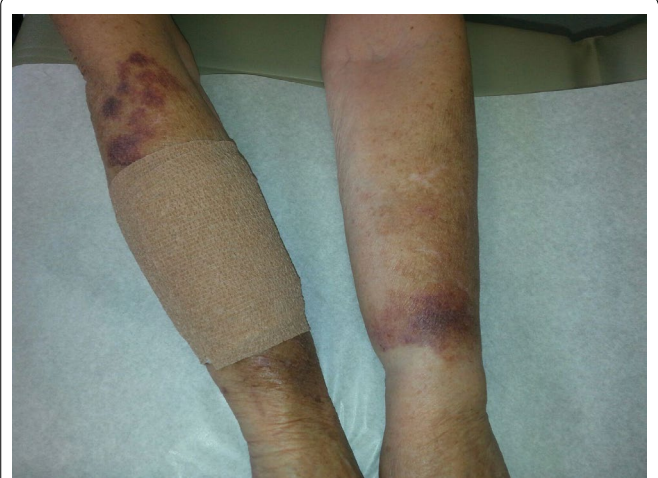

Figure 1: Purpuric patches on the forearm.

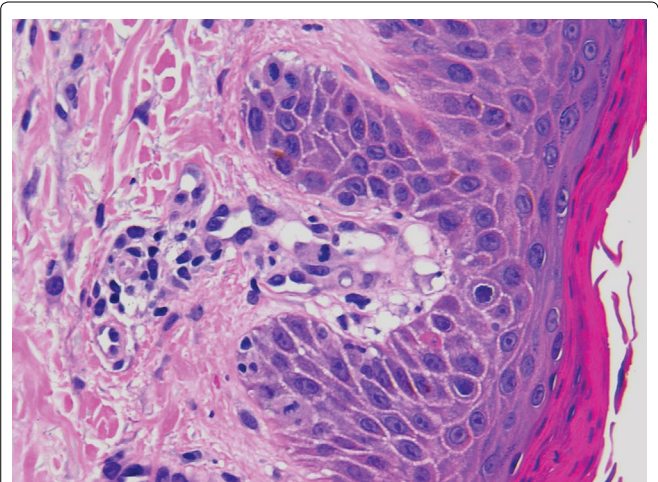


Figure 2: Histologic features suggesting the spongiotic stage of a purpuric dermatitis.

was taking levothyroxine, losartan, metoprolol, and simvastatin. She had no family history of similar disorders. Her laboratory studies, including complete blood count, platelet count, peripheral blood

smear, coagulation studies, as well as biochemical profile were normal.

A diagnosis of Purpura Pigmentosa Progressiva was made with biopsy of the affected areas showing typical histologic features suggesting the spongiotic stage of purpuric dermatitis (Figure 2).

A trial of topical corticosteroids was started, which slightly improved the symptoms of itching, but had little effect on the discoloration. Since her symptoms were mild she decided to forgo any further treatment, and opted for watchful waiting. After years of monitoring, there were periods of waxing and waning symptoms. The symptoms had no significant progression, and the disorder caused mainly cosmetic concerns.

Discussion

Purpura Pigmentosa Progressiva is a skin disorder causing discoloration of the dermis of the trunk and upper and lower extremities. It is also known as Progressive Pigmentary Dermatitis or Schamberg's Disease. The etiology of the disorder is unknown but is caused by a lymphatic capillaritis [1].

The disease can occur at any age. The importance of knowledge of this disorder is to help distinguish it from other diseases and problems that could mimic it. The disease involves skin changes that can be confused with child abuse [2], elder abuse, thrombocytopenia purpura, trauma, as well as other clotting disorders. Although much less common, the lesions can mimic scurvy. The skin lesions can be differentiated clinically from ecchymosis and bruising by the rate of resolution; ecchymosis and bruising will usually resolve in one to two weeks while Purpura Pigmentosa Progressiva may take several weeks to months to resolve. Historical information, including previous similar skin lesions in other areas and lack of trauma help to support the diagnosis. Laboratory testing in patients with Purpura Pigmentosa Progressiva shows a normal complete blood count, including platelet count, protime, and prothrombin time. This helps to exclude other bleeding disorders that may cause purpura. The definitive diagnosis is made by biopsy of the purpuric skin lesions; these typically show vascular changes with fibrinoid degeneration, occlusive damage occasioned by a hyalinized substance and swollen endothelium [3,4]. Direct immunofluorescence studies demonstrates depositions of C3 or C1q with or without immunoglobulins, and of fibrin in papillary vessels [3].

Electron microscopic investigation shows typical lymphocytes and two distinct types of dendritic cells [1]. In the early phase adhesion receptors were expressed by infiltrating cells; other adhesion receptors were expressed by endothelial cells [1].

Purpura Pigmentosa Progressiva differs from other forms of pigmented dermatosis by laboratory testing and the pattern of lesions. Majocchi disease or Purpura annularis telangiectodes also is nonblanching purpuric lesions, but these appear more frequently in an annular pattern and may have atrophy in the center of the lesion [5].

Purpura Pigmentosa Progressiva may resemble Kaposi's Sarcoma and is differentiated by biopsy and negative HIV testing. It can also mimic Eczematid like purpura of Doucas and Kapetanakis and can be distinguished by the eczematous features in this disorder.

Treatment

Treatment is based on the severity of the disorder. Frequently symptoms are mild and the disorder causes only cosmetic or aesthetic disturbance. In these cases, no treatment is needed. There is no cure for Purpura Pigmentosa Progressiva but mild symptoms such as itching can be improved with mild to moderate potency steroid Creams [4]. For more severe symptoms, an eight-week course of pentoxifylline 400 mg daily has shown symptomatic relief [4]. Psoralen plus ultraviolet light therapy has shown some promise [4]. Some encouraging results in treating this disorder have been achieved using aminaphtone 75 mg twice daily for one month with the purpuric lesions disappearing within about one week and no relapse occurring after suspending the medication for one year [6,7]. Aminaphtone is not available in the United States, but is used in Germany, Brazil, Italy as well as other countries.

Supplementary File

([link](#))

References

1. Ghersetich L, Lotti T, Bacci S, Comacchi C, Campanille G, et al. (1995) Cell infiltrate in progressive pigmented purpura (Schamberg's disease): immunophenotype, adhesion receptors, and intercellular relationships. *Int J Dermatology* 34: 846-850.
2. AlJasser M, Al-Khenaizan S (2008) Cutaneous mimickers of child abuse: a primer for pediatricians. *Eur J Pediatr* 167: 1221-1230.
3. Iwatsuki K, Aoshima T, Tagami H, Ohi M, Yamada M (1980) Immunofluorescence study in purpura pigmentosa chronica. *Acta Derm Venereol* 60: 341-345.
4. Szeles J, Cook J, Sammons D, Shubrook J (2011) Chronic lesions on legs. See comment in PubMed Commons below *J Fam Pract* 60: 427-429.
5. Garg A (2015) Pigmented purpuric dermatoses (capillaritis).
6. Torrelo A, Requena C, Mediero IG, Zambrano A (2003) Schamberg's purpura in children: a review of 13 cases. *J Am Acad Dermatol* 48: 31-33.
7. de Godoy JM, Batigália F (2009) Aminaphtone in the control of Schamberg's disease. *Thromb J* 7: 8.