




ORIGINAL ARTICLE

Anatomical Changes of Brain of Amyotrophic Lateral Sclerosis Patients: Viewed from MRI

Bárbara Aymeé Hernández Hernández, MD, PhD* 

Clinical Neurophysiology Department, Cuban Neuroscience Centre, Havana, Cuba



***Corresponding author:** *Bárbara Aymeé Hernández Hernández, Clinical Neurophysiology Department, Cuban Neuroscience Centre, 190 street #19818 between 25 and 27, Cubanacán, Playa, Havana, 11300, Cuba, Tel: 5372637100; 5353609952*

Abstract

Introduction: Amyotrophic Lateral Sclerosis (ALS) is a neurodegenerative disease, which signs of motor neuron dysfunction in one or more anatomic regions. New image processing methods have showed degeneration on grey and white matter of different cortical and subcortical brain structures.

Objective: Describe brain changes in a group of ALS patients through post-processing MRI techniques and correlate it with clinic abnormalities.

Method: Thirty sporadic ALS patients and thirty healthy subjects were recruited, they were paired in age and sex. T1 and T2 weighted, FLAIR and DTI3T MRI scans were acquired. Tractography, Voxel Based Morphometry (VBM) and cortical thickness processing analysis were done.

Results: In relation of ALS patients, tractography revealed that corticospinal tract number of fibers and diameter were lower than healthy subjects ($p = 0.03$); while optic radiation showed diminish of RD and increase of MD ($p = 0.03$). The number of fibers of evaluated tracts diminishes when disease duration increasing ($p = 0.00$) and when ALSFRS score is worse ($p = 0.04$). VBM revealed brain atrophy on cortical areas, cerebellum, brainstem, deep gray nuclei, corpus callosum, corticospinal tract, internal and external capsule, lower and middle longitudinal fascicle and optical radiation of ALS patients. Cortical thickness analysis showed diminish of thickness on bilaterally pre-central gyrus and parietal posterior areas ($p = 0.03$) on ALS patients. It diminishes when disease duration increase ($p = 0.00$) and when ALSFRS score is worse ($p = 0.00$).

Conclusion: In our ALS patient's series was demonstrated morphologic abnormalities of grey and white matter of cortex, subcortical structures, cerebellum and brainstem. These abnormalities increase when clinical aspects get worse.

Keywords

ALS, Tractography, Voxel based morphometry, Cortical thickness

Introduction

According to the ICD-11, Amyotrophic Lateral Sclerosis (ALS, code: 8B60.0) is a progressive, fatal disorder in which signs of lower and upper motor neuron degeneration are seen in one or more regions: bulbar, cervical, thoracic or lumbosacral [1]. Median survival time is 2-4 years from onset of symptoms and it is the third more frequent neurodegenerative disease [2,3].

Electrophysiological studies should be required to confirm it. MRI, may be performed to exclude other causes that might explain clinical and electrophysiological features [2-5].

Incidence rate have been reported 2-3 per 100,000 person-years in European population, 0.7-0.8 in Asian population and 0.55 in Cuba, for that reason it is considered as a rare disease, but the number of patients is increasing [6].

Recently have changed the widely held belief that ALS affects only the motor neuron system, because evidence of new images methods suggest that ALS is a multisystem neurodegenerative disease that involves further sensory and extrapyramidal systems [1-3].

With this research we intend to describe the brain structural changes in a group of ALS patients through post-processing MRI studies and we propose correlate these changes with clinic abnormalities.

Methods

Subjects

A total of 30 consecutive sporadic ALS patients were recruited between 2018 and 2020, according to the revised *El Escorial* criteria for clinically definite or probable [7]. The control group consisted of 30 healthy subjects.

No clinical diagnosis of frontotemporal dementia (FTD) and no cognitive impairment symptoms were found in these patients.

Ethical considerations

The study protocol was approved by Ethical Committee of Cuban Neuroscience Centre and all of patients and healthy subjects were agree with the evaluation and signed informed consent. All procedures of the study were in accordance with the ethical standards of the institution and with the 1964 Helsinki declaration.

Exclusion criteria

Persons with contraindication for MRI and who deny participating.

Clinical measurements

ALS Functional Rating Scale Reviewed (ALSFRS-R) was used to evaluate the functional status of ALS patients. It is based on 12 items; scores range from 0 (maximum disability) to 48 (normal) points.

Image acquisition

MRI was carried out using a 3T Allegra system scanner (Siemens) device with a standard quadrature head coil.

High-resolution three-dimensional whole-brain T1-weighted MRI scans were acquired using a volumetric three-dimensional spoiled fast gradient echo with the following parameters: Repetition time (TR) = 2000 ms, echo time (TE) = 2.6 ms, inversion time (TI) = 900 ms, slice thickness = 1.0 mm; flip angle = 9°, field of view (FOV) = 230 × 230 mm, 1 × 1 × 1 mm³ voxel size. The volume consisted of 192 contiguous coronal sections covering the entire brain, acquisition matrix: 256 × 256.

T2-weighted MRI scans were acquired with TR = 3500 ms, TE = 354 ms.

FLAIR MRI scans were acquired with TR = 5000 ms, TE = 353 ms, TI = 1800 ms.

DWI data were acquired using a diffusion weighted spin echo imaging sequence with the following parameters: 80 volumes, slice thickness 1.0 mm, representing 80 gradient directions, FOV = 230 mm, TR = 86 ms, TE = 8000 ms; flip angle = 90°, b = 1000 s/mm² and two scan with gradient 0 (b = 0), resolution was 1 × 1 × 1.

Image processing

DICOM to nifty image format was convert with dcm2nii tool, Chris Rorden's dcm2nii:4AUGUST2014 32bit (<https://www.nitrc.org/projects/dcm2nii/>).

DTI processing: DTI images were processed using DSI Studio software tool (<https://dsi-studio.labsolver.org/>).

Images were reoriented into oblique axial, slices were aligned parallel to the anterior-posterior commissural axis with the origin set to the anterior commissure, Eddy currents distortions were corrected, diffusion tensor was estimated, scalar maps were constructed, fibre tracking was done, tensor were visualized and tractography based analysis (automatic) was done.

Based on Montreal neurologic Institute (MNI) maps, ROIs was placed at left (cortico spinal tract, arcuate fascicle and optic radiation) with a volume size of 2.7e+04 mm cubic. An ROI was placed at right (cortico spinal tract, arcuate fascicle and optic radiation) with a volume size of 2.9e+04 mm cubic. A seeding region was placed at whole brain. The anisotropy threshold was randomly selected. The change threshold was 20%. The angular threshold was randomly selected from 15 degrees to 90 degrees. The step size was randomly selected from 0.5 voxel to 1.5 voxels. Tracks with length shorter than 26.9531 or longer than 269.531 mm were discarded. A total of 50000 seeds were placed.

Once tracts were constructed, the following quantitative metrics were calculated automatically:

- Number of tracts (called too number of fibres or count of fibres): It is the number of streamlines generated by the algorithm (n).
- Tract length or mean longitude: It was calculated by multiplying number of coordinates in the streamlines with the distance between the coordinates. It was calculated trough the following equation:

$$\frac{1}{n} \sum_{i=1}^{i=n} \sum_{t=1}^{t=mi-1} \|vi(t) - vi(t+1)\|_2$$

n is the total number of tracks, **vi(t)** is a sequence of 3D coordinates representing the trajectory of a track, **t** is a discrete variable from 1 to **mi**, where **mi** is the number of the coordinates.

Diameter (in mm): It was calculated trough the following equation: $2 \sqrt{\frac{\text{volume}}{\pi \times \text{length}}}$

Irregularity: Is conceptually similar to convexity and concavity. It is the opposite of compactness or roundness defined in computer vision. It was calculated trough the following equation: $\frac{\text{surface area}}{\pi \times \text{diameter} \times \text{length}}$

Fractional Anisotropy (FA): It is a scalar measure of the preferential axis of diffusion motion. It is related to the integrity of the myelin, the density and the

parallelism of the fibres, it has a value ranged from 0 (isotropic) to 1 (totally anisotropic).

Mean Diffusivity (MD): It is the average displacement of water within a voxel in the main axes.

Axial Diffusivity (AD): It quantifies how fast water diffuses along the axonal fibres. It is low on axonal damage.

Radial Diffusivity (RD): It evaluates the perpendicular component of water diffusion to axons [8].

Voxel based morphometry (VBM) analysis

VBM was a fully automated, whole-brain technique that enables measurement of regional brain volumes based on voxel-wise comparison of grey and white matter volumes and the DARTEL registration method; it was done using Statistical Parametric Mapping8 software, running on Matlab 2017a.

Grey (GM) and white matter (WM) of ALS patients and healthy subjects were compared using t-test statistical analysis, with $p < 0.05$.

Cortical thickness processing

Computational Anatomy Toolbox (CAT), version CAT12.6-rc1 (1430) was used, it runs within SPM12. This software tools are freely available at <http://dbm.neuro.uni-jena.de/cat/>.

CAT uses a fully automated method that allows the measurement of cortical thickness and reconstruction of the central surface. It uses a tissue segmentation to estimate the WM distance and then projects the local maxima onto other GM voxels using a neighbouring relationship described by the WM distance [9,10].

Statistical analysis

Descriptive statistical measures were applied.

Between groups mean comparison (t-test) was done to compare mean parameters of tractography of ALS and healthy subjects.

Regression analysis was done in order to evaluate the relation of number of fibres of all of analysed tracts and mean cortical thickness value with disease duration and with ALSFRS-R score in ALS patients.

By group automated analysis (based on t-test) was done for VBM and cortical thickness, maps of signification were construed.

We applied a statistical threshold of $p < 0.05$ in all statistical analysis.

Results

Clinical characteristics

Clinic details of all of participants could be seen on [Table 1](#).

Tractography

Comparison of tractography parameters between groups (ALS patients and healthy subjects): Corticospinal Tract (CST) statistical analysis

It showed diminish of mean number of tracts ($p = 0.03$) and diameter ($p = 0.03$) of ALS patients in relation with healthy subjects (See [Table 2](#) and [Figure 1](#)).

Arcuate Fascicle (AF) statistical analysis

It showed that any mean parameters were

Table 1: Clinic characteristics of ALS patients and healthy subjects.

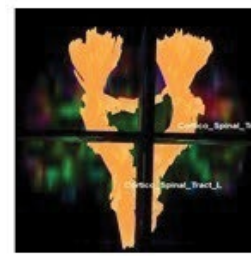
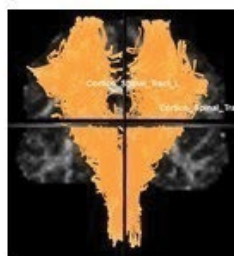	ALS patients (n = 30)	Healthy subjects (n = 30)	t/X ²	p-value
Age mean and SD in years (range)	53.83 ± 10.54 (34-66)	50.60 ± 12.31 (32-64)	1.443	0.165
Sex (M/F)	16/14	15/15	0.895	0.370
Disease duration mean and SD in months (range)	12.00 ± 2.17 (2-24)	NA	NA	NA
Score of ALSFRS-R mean and SD (range)	39.60 ± 5.59 (32-47)	NA	NA	NA
Spinal/Bulbar/Both onset	20/10/0	NA	NA	NA
Laterality onset R/L	15/15	NA	NA	NA
Diagnostic category Definite/Probable	20/10	NA	NA	NA

Table 2: Mean comparison of CST parameters between healthy subjects and ALS patients.

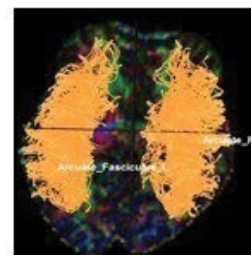
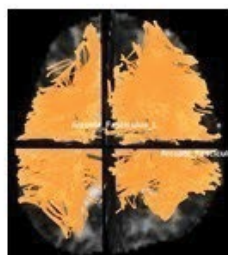Variable	Healthy subjects	ALS	T	P
Number of fibres	1638.5	1118.0	2.46107	0.03*
Mean longitude	67.1	66.6	0.14549	0.88
Diameter	65007.4	40077.3	2.32762	0.03*
Irregularity	14.6	17.0	0.55733	0.58
FA	0.4	0.4	-0.96036	0.35
MD	0.9	0.9	-0.38089	0.71
AD	1.3	1.3	-0.59265	0.56
RD	0.7	0.6	0.45364	0.65

TRACTOGRAPHY

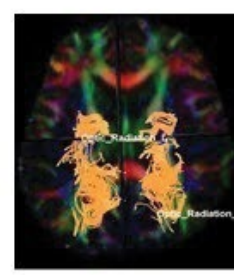
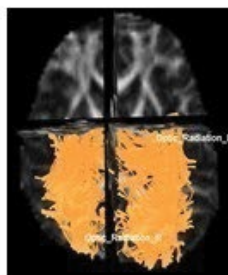
CORTICO-SPINAL TRACT



ARCUATE FASCICLE



OPTIC RADIATION



HEALTHY SUBJECTS

ALS PATIENTS

Figure 1: Tractography.

Note diminish of fibres number apparent on cortico-spinal tract and optic radiation on ALS patients in relation with healthy subjects.

Table 3: Mean comparison of OR parameters between healthy subjects and ALS patients.

Variable	Healthy subjects	ALS	T	P
Number of fibres	703.50	466.6	1.48414	0.16
Mean longitude	67.95	66.4	0.33832	0.74
Diameter	24.49	21.3	0.98534	0.34
Irregularity	15.71	15.0	0.21240	0.83
FA	0.39	0.4	0.01145	0.99
MD	0.90	1.0	-2.42499	0.03*
AD	1.28	1.4	-2.14382	0.05
RD	0.8	0.71	-2.23692	0.04*

statistically significant to comparison between ALS patients in relation with healthy subjects.

Optic Radiation (OR) statistical analysis

It showed diminish of RD ($p = 0.03$) and increase of MD ($p = 0.03$) of ALS patients in relation with healthy subjects (See [Table 3](#)).

Regression analysis

Analysis of number of tracts in relation with disease duration

It showed that number of tracts of CST, OR and AF diminishes when disease duration increasing ($p = 0.00$) (See [Table 4a](#)).

The rest of parameters of tractography of all evaluated tracts were not statistically significant in relation with the increase of the disease duration.

Table 4a: Regression summary for dependent variable: Number of tract on ALS patients in relation with (a) disease duration.

Left corticospinal tract	R = 0.15505220 R ² = 0.02404119 Adjusted R ² = ----- F (1,17) = 0.41877 p < 0.52619 Std Error of estimate: 430.80				
		b	Std Error	t	P
	Disease duration	-1322.98	142.76	9.26	0.00*
Right corticospinal tract	R = 0.30777864 R ² = 0.04426524 Adjusted R ² = ----- F (1,17) = 0.78736 p < 0.38728 Std Error of estimate: 459.87				
		B	Std Error	T	P
	Disease duration	-1311.22	152.40	8.60	0.00*
Left arcuate fascicle	R = 0.14774127 R ² = 0.02182748 Adjusted R ² = ----- F (1,17) = 0.37935 p < 0.546111 Std Error of estimate: 376.19				
		B	Std Error	T	p
	Disease duration	-1328.48	124.67	10.65	0.00*
Right arcuate fascicle	R = 0.37274846 R ² = 0.13894141 Adjusted R ² = 0.8829091 F (1,17) = 2.7431 p < 0.11601 Std Error of estimate: 309.99				
		b	Std Error	T	p
	Disease duration	-959.78	102.73	9.34	0.00*
Left optic radiation	R = 0.02291464 R ² = 0.00052508 Adjusted R ² = ----- F (1,17) = 0.00893 p < 0.92581 Std Error of estimate: 307.28				
		b	Std Error	t	p
	Disease duration	-453.41	101.83	4.45	0.00*
Right optic radiation	R = 0.02291464 R ² = 0.00052508 Adjusted R ² = ----- F (1,17) = 0.00893 p < 0.92581 Std Error of estimate: 307.28				
		b	Std Error	t	p
	Disease duration	-398.53	75.46	5.28	0.00*

Notice it diminishes as disease duration increase

Table 4b: Regression summary for dependent variable: Number of tract on ALS patients in relation with (b) ALSFRS-R score.

Left corticospinal tract	R = 0.48232575 R ² = 0.23263813 Adjusted R ² = ----- F (1,3) = 0.90950 p < 0.41060 Std Error of estimate: 352.86				
		b	Std Error	t	P
	ALSFRS-R score	382.22	1258.75	0.30	0.78
Right corticospinal tract	R = 0.68003288 R ² = 0.046244472 Adjusted R ² = 0.28325963 F (1,3) = 2.5808 p < 0.20652 Std Error of estimate: 222.95				
		b	Std Error	t	p
	ALSFRS-R score	5578	17.00	3.27	0.04*
Left Arcuate fascicle	R = 0.34705073 R ² = 0.12044421 Adjusted R ² = ----- F (1,3) = 0.41081 p < 0.56716 Std Error of estimate: 292.37				
		b	Std Error	t	p
	ALSFRS-R score	846.19	1042.95	0.81	0.47
Right Arcuate fascicle	R = 0.47990701 R ² = 0.23031073 Adjusted R ² = ----- F (1,3) = 0.89768 p < 0.41330 Std Error of estimate: 264.55				
		b	Std Error	t	p
	ALSFRS-R score	71.77	795.30	-0.09	0.93
Left optic radiation	R = 0.06038905 R ² = 0.00364684 Adjusted R ² = ----- F (1,3) = 0.01098 p < 0.92316 Std Error of estimate: 485.29				
		b	Std Error	t	p
	ALSFRS-R score	572.02	1731.13	0.33	0.76
Right optic radiation	R = 0.47990701 R ² = 0.23031073 Adjusted R ² = ----- F (1,3) = 0.89768 p < 0.41330 Std Error of estimate: 264.55				
		b	Std Error	t	p
	ALSFRS-R score	1520.27	943.71	1.61	0.20

Notice it diminishes when ALSFRS-R score is worse on right cortico-spinal tract. It is not significant on the rest of evaluated tracts

Analysis of number of tracts in relation with ALSFRS score

It showed that number of tracts of CST diminishes when ALSFRS score is worse ($p = 0.04$) See [Table 4b](#).

The rest of parameters of tractography of CST tracts were not statistically significant in relation with ALSFRS score.

Any parameters of tractography of OR and AF were statistically significant in relation with ALSFRS score.

Voxel based morphometry

Patterns of brain atrophy in grey matter: We observed reduced grey matter density on ALS patients in relation with healthy subjects on cingulate gyrus, anterior portion of occipital lobe, paracentral lobe, precuneus, cerebellum, uncus, gyrus parahipocampallis, gyrus lingual, medulla oblongata, tectum mesencephalic, frontal and parietal lobes, insula, claustrum, thalamic nucleus, globepallidum and putamen nucleus and amygdalin nucleus ([Figure 2](#)).

Patterns of brain atrophy in white matter: We observed reduced white matter density in ALS patients in relation with healthy subjects on corpus callosum, corticospinal tract (at midbrain, pons and medulla oblongata), internal capsule and external capsule, optical radiation, lower and middle longitudinal fascicle, white matter of frontal, parietal and occipital areas ([Figure 3](#)).

Cortical thickness

Comparison between groups (ALS patients and healthy subjects): ALS patients showed diminish of mean thickness on bilaterally pre-central gyrus and parietal posterior areas ($p = 0.03$) See [Figure 4](#).

Group statistical analysis of cortical thickness showed differences between ALS and healthy subjects: ALS patients had diminished of cortical thickness on parietal area and posterior and superior sites of frontal lobe in relation with healthy subjects, surface-based statistical maps showing clusters of significant ($p < 0.05$) (See [Figure 5](#)).

Regression analysis

Analysis of cortical thickness in relation with disease duration

It showed that mean cortical thickness diminishes when disease duration increasing ($p = 0.00$) See [Table 5a](#).

Analysis of cortical thickness in relation with ALSFRS score

It showed that mean cortical thickness diminishes when ALSFRS score is worse ($p = 0.00$) See [Table 5b](#).

Discussion

Great number of studies have reported abnormalities of brain of ALS patients. Some of these have reported abnormalities on cortex and deep nuclei, others have

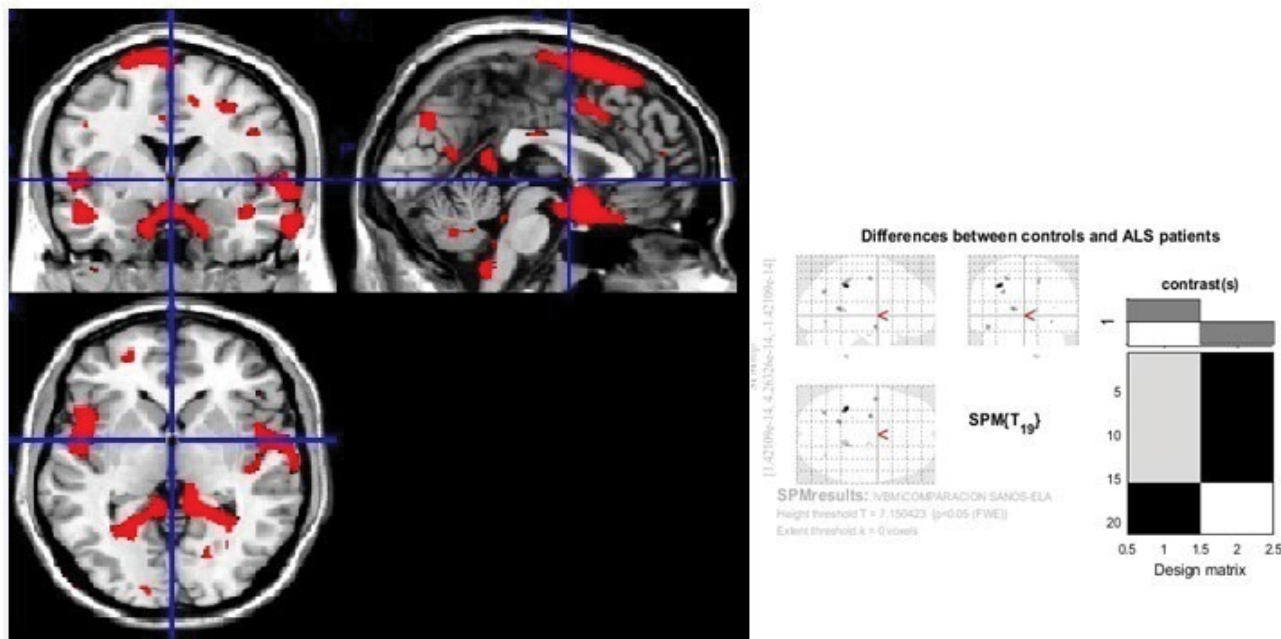


Figure 2: Generic MRI brain slices with superimposed areas showing statistically regions of grey matter atrophy ($p < 0.05$, corrected for multiple comparisons) in a group of 30 ALS patients compared with 30 healthy agematched subjects using voxel-based morphometry.

It shows grey matter atrophy on cingulate gyrus, anterior portion of occipital lobe, paracentral lobe, precuneus, occipital areas, cerebellum, uncus, gyrus parahipocampallis, gyrus lingual, medulla oblongata, tectum mesencephalic, frontal and parietal lobes, insula, claustrum, thalamic nucleus, globe palladium, putamen and amygdalin nucleus. The colored bar represents the T score.

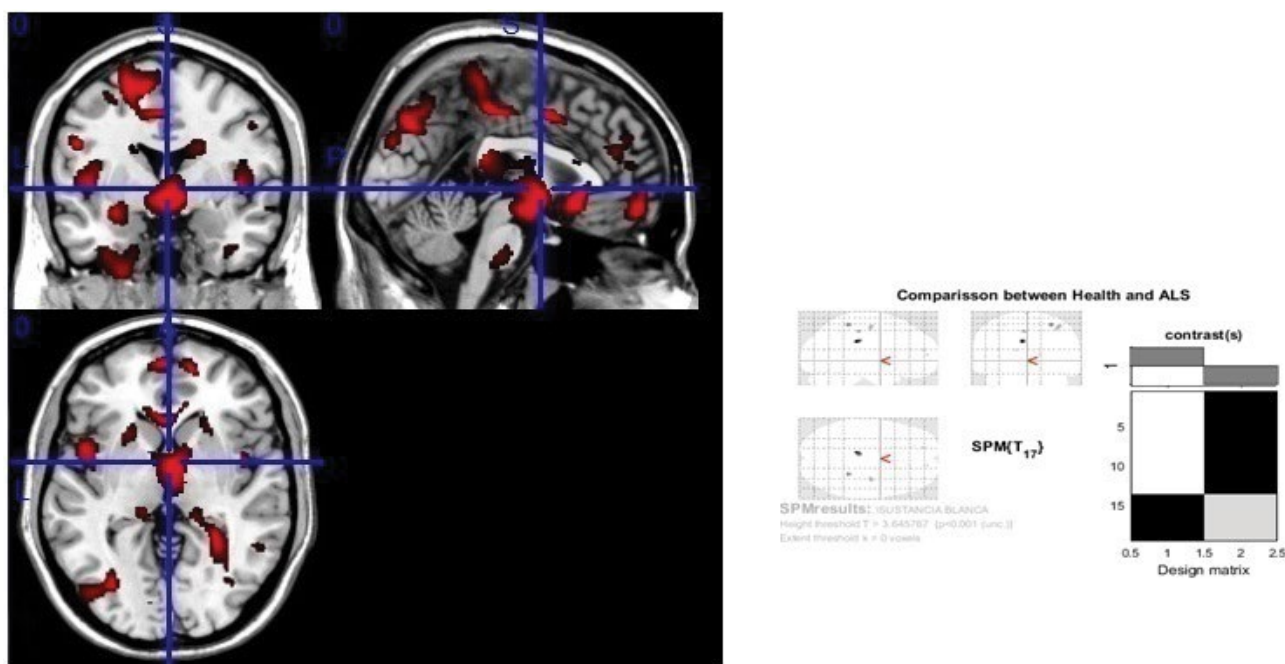


Figure 3: Generic MRI brain slices with superimposed areas showing statistically significant regions of white matter atrophy ($p < 0.05$, corrected for multiple comparisons) in a group of 30 ALS patients compared with 30 healthy agematched subjects, using voxel-based morphometry.

It shows white matter atrophy on corpus callosum, corticospinal tract (at midbrain, pons and medulla oblongata), internal and external capsule, optical radiation, lower and middle longitudinal fascicle, white matter of frontal, parietal and occipital areas. The colored bar represents the T score.

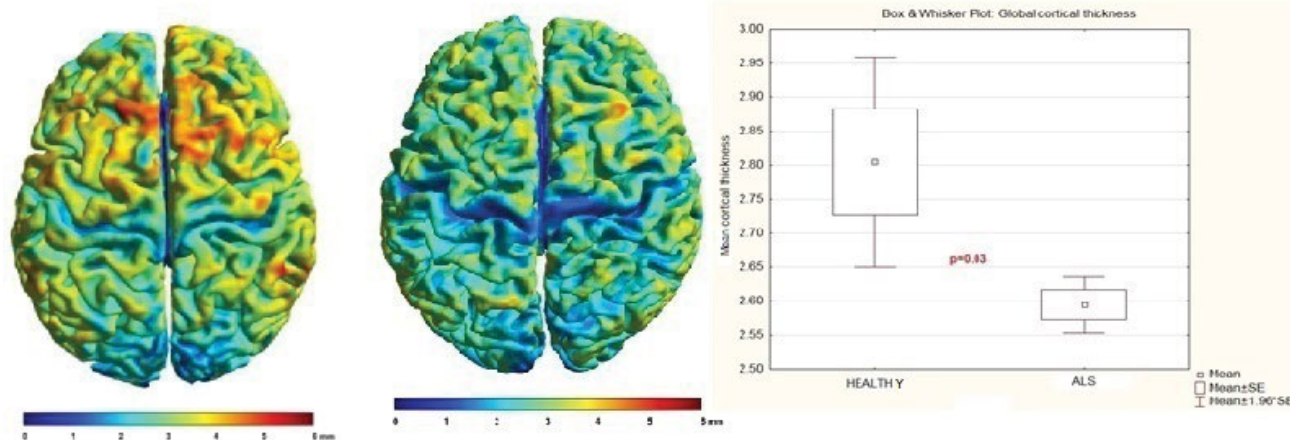


Figure 4: Comparison of individual mean cortical thickness between healthy subjects and ALS patients.

Notice it is diminished in ALS patients. $p = 0.03$

showed abnormalities on different motor and not motor tract, including sensory tracts, which has revolutionized the concept of ALS is a pure motor disease. Nevertheless, some of these abnormalities are not related with any clinical sign. This particular aspect remains unclear.

Stämpfli in 2018 demonstrated a significant deterioration of the white matter integrity in ALS patients, as reflected by reduced fibre density (FD) or fibre number and mean diffusion signal (MDS) values. Significant decreases of both parameters were found along CST and thalamic radiation, body of the corpus callosum as well as the forceps, uncinated fasciculus,

superior longitudinal fasciculus, inferior longitudinal fasciculus, and inferior fronto-occipital fasciculus [11].

Geraldo in 2018 demonstrated that MD and AD maps showed significant differences between ALS patients and healthy controls in the CST and in the prefrontal white matter in the right cerebral hemisphere ($p < 0.05$). They also found increased of MD, AD, and RD in extra-motor frontal areas in ALS patients relative to controls [12].

Verber in 2019 demonstrated that MD elevation has to be considered as a marker in ALS diagnosis [13].

Table 5a: Regression summary for dependent variable: Mean cortical thickness over the entire brain surface on ALS patients in relation with: (a) disease duration.

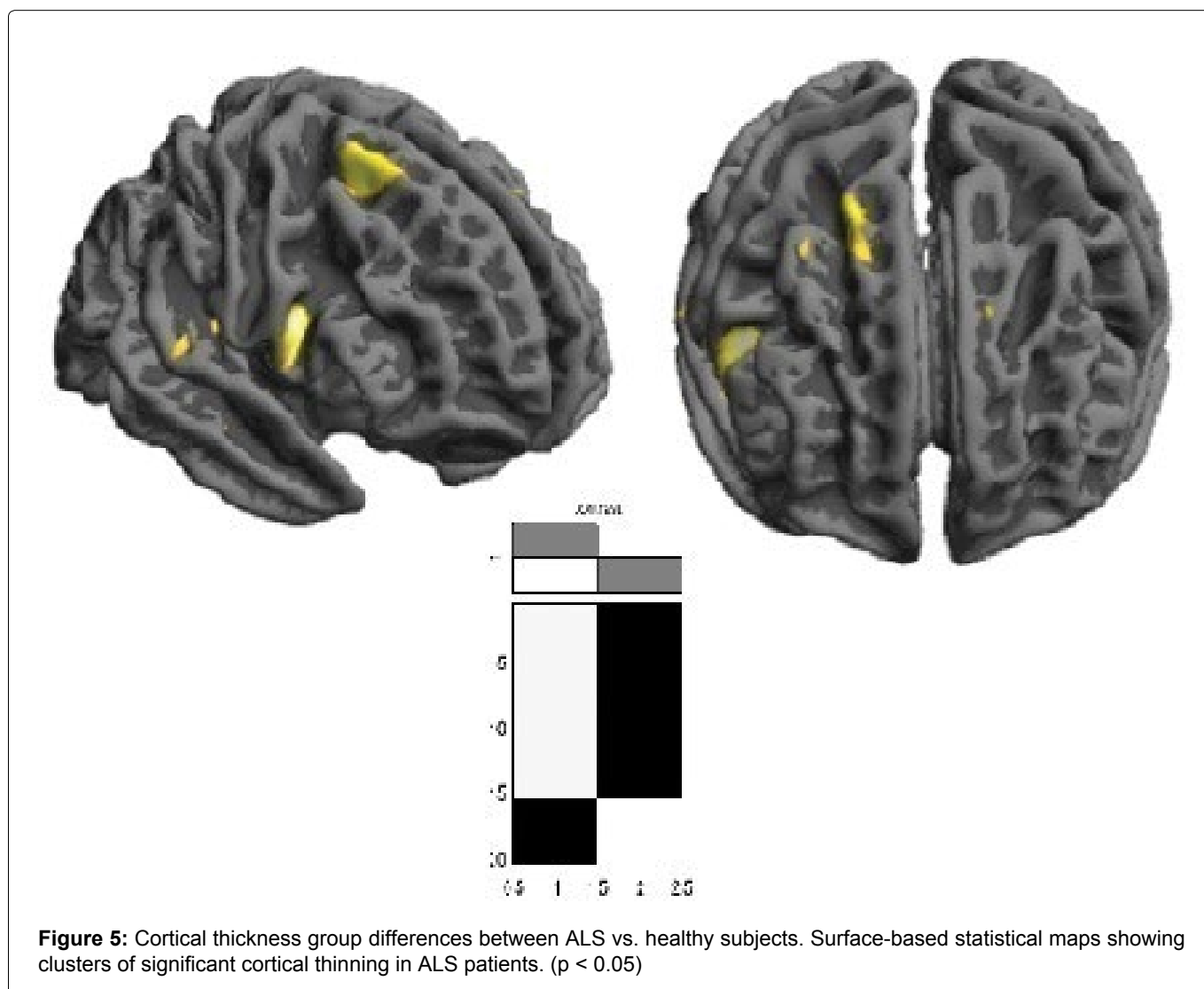
R = 0.30777864 R2 = 0.9472769 Adjusted R2 = ----- F (1,3 = 0.31392 p < 61440 Std Error of estimate: 0.12565				
	B	Std Error	t	p
Disease duration	-2.47	0.08	28.85	0.00*

Notice it diminishes when disease duration increase

Table 5b: Regression summary for dependent variable: Mean cortical thickness over the entire brain surface on ALS patients in relation with: (b) ALSFRS-R score.

R = 0.37587119 R2 = 0.14127915 Adjusted R2 = ----- F (1,3 = 0.49357 p < 53295 Std Error of estimate: 0.12265				
	b	Std Error	t	p
ALSFRS-R score	2.81	0.43	6.45	0.00*

Notice it is better when ALSFRS-R score is better



In ALS, FA reduction in the corticospinal tracts and corpus callosum is a consistent finding [14], which correlates with clinical measures of disease progression [15]. Nevertheless in our cases it was not significant in any of the evaluated tracts.

Bao in 2018 showed significant increased RD in premotor, primary motor, primary and secondary somatosensory cortical regions, corticospinal tract, superior corona radiata, posterior limb of internal

capsule and cerebral peduncle; body of corpus callosum and part of bilateral external capsule. They found significant correlations between ALSFRS-R scores and the values of RD indicating that this DTI index might serve as imaging biomarker in evaluating the disease severity of ALS, and that the CST could be a reliable region for clinical monitoring [16]. Diagnostic sensitivity and specificity were 68 and 73%, respectively [17-19]. Previous studies have consistently demonstrated

significant changes of the CST in ALS patients compared with healthy volunteers [20-29].

According to Pallebage-Gamarallage in 2018: DTI showed significant degree of white matter damage to the uncinated fasciculus, inferior and superior longitudinal fasciculus, arcuate fascicle, genu of corpus callosum, forceps minor and cingulum bundle [28]. For this reason, we decided add another non-motor tract like arcuate fascicle and optic radiation in our analysis.

In post-mortem studies, through the structural MRI, some authors showed lateral corticospinal tract hyperintensity along the scanned segment of the spinal cord, quantitative evaluation of the same region on the corresponding MRI plane demonstrated significant decrease in average FA value ($p < 0.01$) and significant increase in average MD values ($p < 0.01$) in comparison to the normal appearing white matter region [27,28].

Other post-mortem studies have demonstrated absence of Betz cells from Layer V of the precentral gyrus in patients with ALS and that the remaining pyramidal cells were significantly smaller than those seen in healthy controls [29,30].

Stämpfli showed significant changes in the fibre density values with disease progression. The fibre density values were decreased in parts of the CST, the thalamic radiation, the body of the corpus callosum, arcuate and uncinated fasciculus and in various association fibers [11]. Our results are according with Stämpfli's results.

Stämpfli explained that fibre density may be more sensitive to white matter changes than the FA value and may permit evaluating pathological processes at an earlier stage of the disease [11].

In our opinion number of tracts or fibre density is a robust parameter to evaluate neurodegenerative diseases, at the beginning and in the diseases progress.

In relation to correlation with clinic abnormalities, Bao showed there was a negative correlation between the mean RD values and ALSFRS-R scores ($r = -0.439$, $p = 0.011$) on the left CST of ALS patients [16].

Stämpfli's analysis did not reveal significant correlations of the diffusion parameters with disease severity as measured by the ALSFRS-R [11].

Sarsilmaz in 2018 demonstrated that there was a significant correlation between FA abnormalities with symptoms/disease duration and upper and lower motor neuron scores ($p < 0.05$). Statistical analysis indicated a strong correlation with *El Escorial* criteria, r-ALSFRS, and disease duration ($p < 0.01$) [31].

Qiu in 2019 found focal grey matter atrophy in the left precentral gyrus in patients with ALS in VBM analysis [29].

Steinbach in 2020 showed that ALS patients had significantly decreased of GM density in the medial, inferior-frontal, and temporal lobes; in the parietal,

occipital and cerebellar and sub-cortical regions ($p < 0.01$). WM density was decreased in patients primarily in the bilateral frontal and parietal regions, extending down to the brainstem; in the bilateral temporal lobes, but not within cerebellar projections ($p < 0.01$) [32].

Trojsi in 2020 demonstrated GM atrophy ($p < 0.05$) in left precentral gyri, left frontal pole, right supramarginal gyrus, right inferior temporal gyrus and putamen [33].

In recent years imaging in ALS confirmed extensive extra-motor pathology in cerebellar, extrapyramidal, subcortical, hippocampal hypothalamic, brainstem, and frontotemporal involvement. Compared to HCs, patients with ALS showed at baseline regional [34-40].

Our results are according with other author's results. And we consider future connectivity studies will clarify the significance of non-motor structures abnormalities.

Nijboer and previously other authors reported posterior cortical atrophy in some phenotype of ALS patients, thought conventional and post-processing MRI images. This pathological finding has been observed in Alzheimer disease too [41-44]. In our patients, posterior areas were very affected, it was demonstrated by different techniques.

Wirth in 2018 had done a cortical thickness analysis focused on precentral and postcentral regions of interest. They showed cortical thickness was not significantly different between ALS patients and healthy controls ($p = 0.258$) [45].

Meyer and other authors have done post-mortem and MRI studies and they have showed approximately 1.5 times greater cortical thickness of the precentral compared to the postcentral cortex in ALS patients [46-48].

Meadowcroft in 2015 observed cortical thinning in ALS patients with faster progression or advanced stage of disease [49].

Kropf and another authors have demonstrated that the significant cortical thinning of the postcentral gyrus occurring in ALS, and it is correlated with disease severity [50,51].

Abidi in 2019 described the right paracentral gyrus exhibited volumetric ($p = 0.05$) and thickness ($p = 0.049$) reduction in the upper motor neuron predominant cohort compared to the lower motor neuron predominant group [52].

Wirth in 2018 showed that ALSFRS-R sum scores correlated with cortical thickness of the precentral ventral cortex ($p = 0.009$) and the postcentral ventral region ($p = 0.032$) [45].

In summary

In our analysis different brain structures were observed affected in ALS patients:

Grey matter:

Motor structures: Frontal and parietal lobes, cerebellum, medulla oblongata, tectum mesencephalic, claustrum, globe pallidum, putamen and amygdalin nucleus.

Non-motor structures: Occipital lobe, cingulate gyrus, paracentral lobe, precuneus, uncus, gyrus parahipocampalis, gyrus lingual, insula, thalamic nucleus.

White matter:

Motor structures: Corticospinal tract at midbrain, pons and medulla oblongata, internal capsule, white matter of frontal and parietal areas.

Non-motor structures: corpus callosum, external capsule, optical radiation, lower and middle longitudinal fascicle, white matter of occipital areas.

Axonal degeneration seems to be the primary abnormality of main tracts, they show diminish of fibre numbers, diameter, RD and increase of MD. The tracts appear more affected when disease duration increase and when ALSFRS score gets worse.

Cortical thickness was diminished in ALS patients on pre-central gyrus, parietal posterior areas and postero-superior part of frontal lobe. It is more affected with the disease duration increase and when ALSFRS score gets worse.

Conclusion

In our ALS patient's series was demonstrated morphologic abnormalities of grey and white matter of cortex, subcortical structures, cerebellum and brainstem. These abnormalities increase when clinical aspects get worse.

Declaration of Interest

The authors report no conflicts of interest.

The author reports there are no competing interests to declare.

References

- (2022) International classification of diseases 11th revision (ICD-11).
- Kiernan MC, Vucic S, Cheah BC, Turner MR, Eisen A, et al. (2011) Amyotrophic lateral sclerosis. *Lancet* 377: 942-955.
- Hernández AH (2016) ALS diagnostic in the electrodiagnostic department of an orthopedic hospital during 2014-2015. Clinical and electrophysiological characteristics. *Open Access J Neurol Neurosurg* 1: 1-8.
- Lorena RRA, Dianney CG, Ramón MO, Miguel R, Ananías GC, et al. (2006) Bases biológicas y patobiológicas humanas de la esclerosis lateral amiotrófica. *Universitas Médica* 47: 35-54.
- Hernandez BA (2018) Finding markers in amyotrophic lateral sclerosis diagnosis. *J Neurol Neurosci* 9: 239.
- Hardiman O (2018) Global burden of motor neuron diseases: Mind the gaps. *Lancet Neurol* 17: 1030-1031.
- de Carvalho M, Dengler R, Eisen A, England JD, Kaji R, et al. (2008) Electrodiagnostic criteria for diagnosis of ALS. *Clin Neurophysiol* 119: 497-503.
- Yeh FC (2020) Shape analysis of the human association pathways. *Neuroimage* 223.
- Dahnke R, Yotter RA, Gaser C (2012) Cortical thickness and central surface estimation. *Neuroimage* 65: 336-348.
- Dahnke R, Ziegler G, Gaser C (2012) Local adaptive segmentation. *HBM*.
- Stämpfli P, Sommer S, Czell D, Kozerke S, Neuwirth C, et al. (2018) Investigation of neurodegenerative processes in amyotrophic lateral sclerosis using white matter fiber density. *Clin Neuroradiol* 29: 493-503.
- Geraldo AF, Pereira J, Nunes P, Reimão S, Sousa R, et al. (2018) Beyond fractional anisotropy in amyotrophic lateral sclerosis: The value of mean, axial, and radial diffusivity and its correlation with electrophysiological conductivity changes. *Neuroradiology* 60: 505-515.
- Verber NS, Shephard SR, Sassani M, McDonough HE, Moore SA, et al. (2019) Biomarkers in motor neuron disease: A state of the art review. *Front Neurol* 10: 291.
- Tang M, Chen X, Zhou Q, Liu B, Liu Y, et al. (2015) Quantitative assessment of amyotrophic lateral sclerosis with diffusion tensor imaging in 3.0T magnetic resonance. *Int J Clin Exp Med* 8: 8295-8303.
- Grolez G, Kyheng M, Lopes R, Moreau C, Timmerman K, et al. (2018) MRI of the cervical spinal cord predicts respiratory dysfunction in ALS. *Scientific Reports* 8: 1828.
- Bao Y, Yang L, Chen Y, Zhang B, Li H, et al. (2018) Radial diffusivity as an imaging biomarker for early diagnosis of non-demented amyotrophic lateral sclerosis. *Eur Radiol* 28: 4940-4948.
- Chen QF, Zhang XH, Huang NX, Chen HJ (2020) Identification of amyotrophic lateral sclerosis based on diffusion tensor imaging and support vector machine. *Front Neurol* 11: 275.
- Foerster BR, Dwamena BA, Petrou M, Carlos RC, Callaghan BC, et al. (2013) Diagnostic accuracy of diffusion tensor imaging in amyotrophic lateral sclerosis: A systematic review and individual patient data meta-analysis. *Acad Radiol* 20: 1099-1106.
- Menke RAL, Körner S, Filippini N, Douaud G, Knight S, et al. (2014) Widespread grey matter pathology dominates the longitudinal cerebral MRI and clinical landscape of amyotrophic lateral sclerosis. *Brain* 137: 2546-2555.
- Cardenas-Blanco A, Machts J, Acosta-Cabronero J, Kaufmann J, Abdulla S, et al. (2016) Structural and diffusion imaging versus clinical assessment to monitor amyotrophic lateral sclerosis. *Neuroimage Clin* 11: 408-414.
- Sarica A, Cerasa A, Valentino P, Yeatman J, Trotta M, et al. (2016) The corticospinal tract profile in amyotrophic lateral sclerosis. *Human Brain Mapping* 38: 727-739.
- Alruwaili AR, Pannek K, Coulthard A, Henderson R, Kurniawan ND, et al. (2018) A combined tract-based spatial statistics and voxel-based morphometry study of the first MRI scan after diagnosis of amyotrophic lateral sclerosis with subgroup analysis. *J Neuroradiol* 45: 41-48.
- Christidi F, Karavasilis E, Riederer F, Zalonis I, Ferentinos P, et al. (2017) Gray matter and white matter changes in

- non-demented amyotrophic lateral sclerosis patients with or without cognitive impairment: A combined voxel-based morphometry and tract-based spatial statistics whole-brain analysis. *Brain Imaging Behav* 35: 2639-2617.
24. Verstraete E, Polders DL, Mandl RCW, Van Den Heuvel MP, Veldink JH, et al. (2014) Multimodal tract-based analysis in ALS patients at 7T: A specific white matter profile? *Amyotroph Lateral Scler Frontotemporal Degener* 15: 84-92.
 25. Sach M, Winkler G, Glauche V, Liepert J, Heimbach B, et al. (2004) Diffusion tensor MRI of early upper motor neuron involvement in amyotrophic lateral sclerosis. *Brain* 127: 340-350.
 26. Sage CA, Van Hecke W, Peeters R, Sijbers J, Robberecht W, et al. (2009) Quantitative diffusion tensor imaging in amyotrophic lateral sclerosis: Revisited. *Hum Brain Mapp* 30: 3657-3675.
 27. Cosottini M, Giannelli M, Siciliano G, Lazzarotti G, Michelassi MC, et al. (2005) Diffusion-tensor MR imaging of corticospinal tract in amyotrophic lateral sclerosis and progressive muscular atrophy. *Radiology* 237: 258-264.
 28. Pallebage-Gamarallage M, Foxley S, Menke RAL, Huszar IN, Jenkinson M, et al. (2018) Dissecting the pathobiology of altered MRI signal in amyotrophic lateral sclerosis: A post mortem whole brain sampling strategy for the integration of ultra-high-field MRI and quantitative neuropathology. *BMC Neurosci* 19: 11.
 29. Qiu T, Zhang Y, Tang X, Liu X, Wang Y, et al. (2019) Precentral degeneration and cerebellar compensation in amyotrophic lateral sclerosis: A multimodal MRI analysis. *Hum Brain Mapp* 40: 3464-3474.
 30. Eisen A, Weber M (2001) The motor cortex and amyotrophic lateral sclerosis. *Muscle Nerve* 24: 564-573.
 31. Sarsilmaz A, Fırat Z, Uluğ AM, Karlıkaya G, Bingöl CA, et al. (2018) Diffusion tensor imaging in early amyotrophic lateral sclerosis using 3T magnetic resonance imaging. *Neurol Sci Neurophysiol* 35: 102-107.
 32. Steinbach R, Batyrbekova M, Gaur N, Voss A, Stubendorff B, et al. (2020) Applying the D50 disease progression model to gray and white matter pathology in amyotrophic lateral sclerosis. *Neuroimage Clin* 25: 102094.
 33. Trojsi F, Di Nardo F, Siciliano M, Caiazzo G, Femiano C, et al. (2020) Frontotemporal degeneration in amyotrophic lateral sclerosis (ALS): A longitudinal MRI one-year study. *CNS Spectrums* 26: 258-267.
 34. Bede P, Pradat PF (2019) Editorial: Biomarkers and clinical indicators in motor neuron disease. *Front Neurol* 10: 1318.
 35. Feron M, Couillandre A, Mseddi E, Termoz N, Abidi M, et al. (2018) Extrapyrmidal deficits in ALS: A combined biomechanical and neuroimaging study. *J Neurol* 265: 2125-2136.
 36. Machts J, Loewe K, Kaufmann J, Jakubiczka S, Abdulla S, et al. (2015) Basal ganglia pathology in ALS is associated with neuropsychological deficits. *Neurology* 85: 1301-1309.
 37. Gorges M, Vercruyssen P, Muller HP, Huppertz HJ, Rosenbohm A, et al. (2017) Hypothalamic atrophy is related to body mass index and age at onset in amyotrophic lateral sclerosis. *J Neurol Neurosurg Psychiatry* 88: 1033-1041.
 38. Finegan E, Shing SLH, Chipika RH, Doherty MA, Hengeveld JC, et al. (2019) Widespread subcortical grey matter degeneration in primary lateral sclerosis: A multimodal imaging study with genetic profiling. *Neuroimage Clin* 24: 102089.
 39. Christidi F, Karavasilis E, Rentzos M, Velonakis G, Zouvelou V, et al. (2019) Hippocampal pathology in Amyotrophic Lateral Sclerosis: Selective vulnerability of subfields and their associated projections. *Neurobiol Aging* 84: 178-188.
 40. Bede P, Chipika RH, Finegan E, Shing SLH, Doherty MA, et al. (2019) Brainstem pathology in amyotrophic lateral sclerosis and primary lateral sclerosis: A longitudinal neuroimaging study. *Neuroimage Clin* 24: 102054.
 41. Nijboer TCW, Nitert B, Westeneng HJ, Van Den Berg LH, van Es MA (2019) A case of ALS with posterior cortical atrophy. *Amyotroph Lateral Scler Frontotemporal Degener* 20: 506-510.
 42. Floeter MK, Gendron TF (2018) Biomarkers for amyotrophic lateral sclerosis and frontotemporal dementia associated with hexanucleotide expansion mutations in C9orf72. *Front Neurol* 9: 1063.
 43. Westeneng HJ, Walhout R, Straathof M, Schmidt R, Hendrikse J, et al. (2016) Widespread structural brain involvement in ALS is not limited to the C9orf72 repeat expansion. *J Neurol Neurosurg Psychiatry* 87: 1354-1360.
 44. Walhout R, Schmidt R, Westeneng HJ, Verstraete E, Seelen M, et al. (2015) Brain morphologic changes in asymptomatic C9orf72 repeat expansion carriers. *Neurology* 85: 1780-1788.
 45. Wirth AM, Khomenko A, Baldaranov D, Kobor I, Hsam O, et al. (2018) Combinatory biomarker use of cortical thickness, MUNIX, and ALSFRS-R at baseline and in longitudinal courses of individual patients with amyotrophic lateral sclerosis. *Front Neurol* 9: 614.
 46. Meyer JR, Roychowdhury S, Russell EJ, Callahan C, Gitelman D, et al. (1996) Location of the central sulcus via cortical thickness of the precentral and postcentral gyri on MRI. *AJNR Am J Neuroradiol* 17: 1699-1706.
 47. Fischl B, Dale AM (2000) Measuring the thickness of the human cerebral cortex from magnetic resonance images. *Proc Natl Acad Sci U S A* 97: 11050-11055.
 48. Sahin N, Mohan S, Maralani PJ, Duddukuri S, O'Rourke DM, et al. (2016) Assignment confidence in localization of the hand motor cortex: Comparison of structural imaging with functional MRI. *AJR Am J Roentgenol* 207: 1263-1270.
 49. Meadowcroft MD, Mutic NJ, Bigler DC, Wang JL, Simmons Z, et al. (2015) Histological-MRI correlation in the primary motor cortex of patients with amyotrophic lateral sclerosis. *J Magn Reson Imaging* 41: 665-675.
 50. Kropf E, Syan SK, Minuzzi L, Frey BN (2019) From anatomy to function: The role of the somatosensory cortex in emotional regulation. *Braz J Psychiatry* 41: 261-269.
 51. Thorns J, Jansma H, Peschel T, Grosskreutz J, Mohammadi B, et al. (2013) Extent of cortical involvement in amyotrophic lateral sclerosis--an analysis based on cortical thickness. *BMC Neurol* 13: 148.
 52. Abidi M, de Marco G, Couillandre A, Feron M, Mseddi E, et al. (2019) Adaptive functional reorganization in amyotrophic lateral sclerosis: Coexisting degenerative and compensatory changes. *Eur J Neurol* 27: 121-128.