



CASE REPORT

Clinical Expressions of Herniosis: Report of a Case

Jesús Andrés Montero-Puga^{1*}, Guillermo Padrón-Arredondo² and Adriana Teresa Cruz-Méndez²

¹General Surgery Resident, Clínica-Hospital Mérida APP del ISSSTE, Mexico

²General Surgeons, Clínica-Hospital Mérida APP del ISSSTE, Mexico



*Corresponding author: Jesús Andrés Montero-Puga, General Surgery Resident, Facultad de Medicina-UADY, Clínica-Hospital Mérida APP del ISSSTE, Street 21 s/n Comisaría de Susulá, Mérida Yucatán, PC: 97314, México, Tel: +52-9991046660

Summary

Introduction: The etiology of hernias involves changes in the expression of different components of the extracellular matrix, which especially affect the fascia transversalis (FT), such as collagen, the elastic component and metalloproteinases (MMP). On the other hand, there is an overexpression of MMP-2 in the FT of young patients with direct inguinal hernia, correlated with an increase in TGF-beta1 that shows an attempt to counteract an increased process of degradation of the extracellular matrix in these patients.

Clinical case: A 63-year-old female with a family history of maternal grandmother with bilateral and umbilical inguinal hernia, father with retinal detachment and inguinal hernia, pathological personal history of essential arterial hypertension, dyslipidemia, and multiple hemangiomas distributed throughout the body. She comes to consult due to increased volume in the right inguinal region for 3 years, in the left inguinal region for two years, both without treatment, which increased with the Valsalva maneuver and currently one in the umbilical region, denying nausea, vomiting, fever, pain or constipation. Physical examination, skin color unchanged, reducible, not incarcerated, not strangled. The diagnostic protocol was started where the presence of bilateral inguinal and umbilical hernia was evidenced, for which a surgical programming was decided to perform abdominal wall plasty. Right and left inguinal plasty with mesh and umbilical plasty without mesh were performed.

Discussion: In the last 30 years, research on the etiopathogenesis of abdominal wall hernias has revealed that one of the causes is due to multifactorial systemic tissue disease, currently known as herniosis.

Keywords

Hernia, Abdominal wall, Metalloproteins, Collagen, Elastin

Introduction

The etiology of hernias involves changes in the expression of different components of the extracellular matrix, which especially affect the fascia transversalis (FT), such as collagen, the elastic component and metalloproteinases (MMP). On the other hand, there is an overexpression of MMP-2 in the FT of young patients with direct inguinal hernia, correlated with an increase in TGF-beta1 that shows an attempt to counteract an increased process of degradation of the extracellular matrix in these patients. At the level of the elastic tissue of the FT, patients with hernia show lower levels of tropoelastin (TE), monomers that make up elastin, and lysyloxidase like-1 (LOXL-1), an enzyme involved in elastin crosslinking. All this is accompanied by a significantly higher expression of elastase, the main enzyme involved in the process of elastin degradation. In cell cultures from FT, the levels of mRNA encoding LOXL-1 were also found to be significantly lower in patients with direct inguinal hernia.

All these alterations highlight a disorder at the level of the extracellular matrix of the connective tissue in patients with inguinal hernias, which together with other exogenous factors (smoking, mechanical stress, tissue aging, etc.) would partly explain the genesis of this pathology [1,2].

Clinical Case

A 63-year-old female with a family history of maternal grandmother with bilateral and umbilical inguinal hernia, father with retinal detachment and inguinal hernia, pathological personal history of essential arterial hypertension, dyslipidemia, and

multiple hemangiomas distributed throughout the body. She comes to consult due to increased volume in the right inguinal region for 3 years, in the left inguinal region for two years, both without treatment, which increased with the Valsalva maneuver and currently one

in the umbilical region, denying nausea, vomiting, fever, pain or constipation. Physical examination, skin color unchanged, reducible, not incarcerated, not strangled. The diagnostic protocol was started where the presence of bilateral inguinal and umbilical hernia was evidenced,

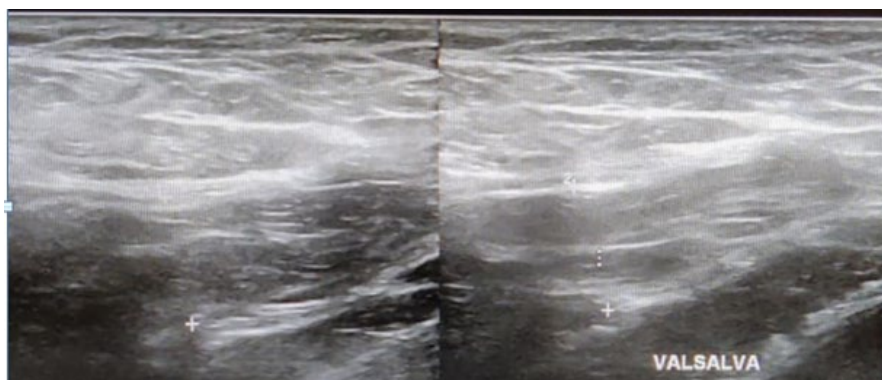


Figure 1

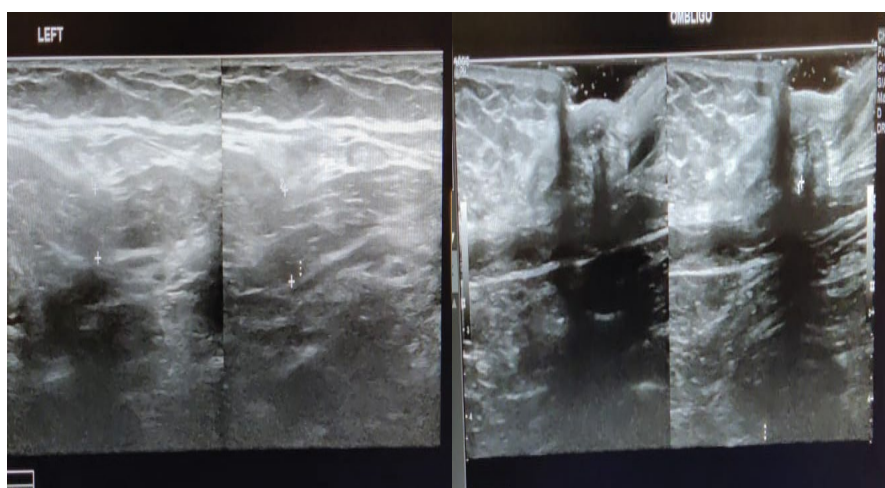


Figure 2

Figure 3

Figure 1, Figure 2 and Figure 3: The diagnostic protocol was started where the presence of bilateral inguinal and umbilical hernia was evidenced, for which a surgical programming was decided to perform abdominal wall plasty.

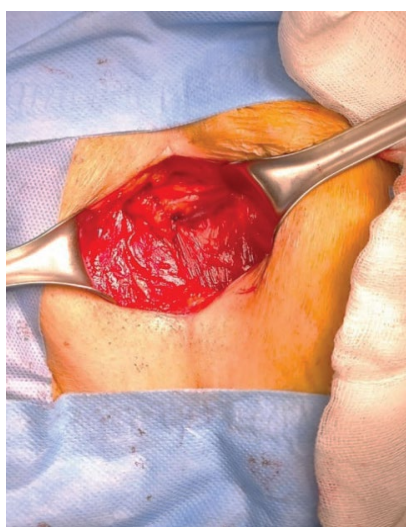


Figure 4

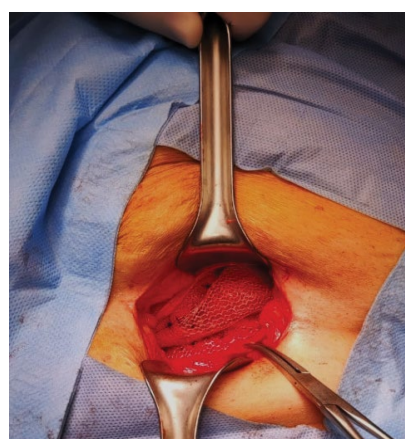


Figure 5

Figure 4 and Figure 5: Right and left inguinal plasty with mesh and umbilical plasty without mesh were performed.

for which a surgical programming was decided to perform abdominal wall plasty (Figure 1, Figure 2 and Figure 3). Right and left inguinal plasty with mesh and umbilical plasty without mesh were performed (Figure 4 and Figure 5). The patient is discharged 24 hours after the procedures were performed. In her follow-up, the patient is asymptomatic and incorporated into her daily activities.

Discussion

In the last 30 years, research on the etiopathogenesis of abdominal wall hernias has revealed that one of the causes is due to multifactorial systemic tissue disease, currently known as herniosis [1]. Defined as a systemic disease of the connective tissue originating in the extracellular matrix and related to a deficient or abnormal production of collagen (collagenosis), or with its accelerated or increased degradation, mediated by proteolytic enzymatic processes [2] and linked to hereditary and environmental factors. Herniosis carriers often have multiple hernias (primary, recurrent, and incisional) and a high recurrence rate when repaired. Abdominal wall hernias are the following: direct or indirect inguinal hernias; femoral hernia; umbilical hernia; epigastric or white line hernias; Spigel's hernia; athlete's hernia; traumatic hernia; obturator foramen hernia; intraparietales hernias [3-6].

In the muscular structures, thinning of the muscle fibers and separation of the bundles with herniation of the preperitoneal fat in their interstices are observed. These findings alone should alert about the coexistence of other pathologies. On the other hand, it is convenient to know that patients with herniosis (collagenosis) are prone to present higher rates of recurrence and complications when they undergo surgical procedures and, in addition, to have higher risks of complications.

Another aspect to consider is the fact of suspecting coexisting multiple pathologies, even in their asymptomatic form due to the predisposition conferred by collagenosis and which, when ignored, can be complicated by not being detected. Examples of this are the association of emphysema and chronic obstructive pulmonary disease, or herniated varicose veins,

which can increase the risk of serious complications in the postoperative period, such as pulmonary thromboembolism. These pathological conditions should be investigated in patients with hereditary collagen disorders, such as Ehlers-Danlos disease, Marfan syndrome in its incomplete or atypical forms [7,8].

Conclusion

Abdominal hernias have a multifactorial cause, such as the weakness of the wall that contains them due to a disease of the extracellular matrix with deficient collagen production, making carriers more susceptible to suffering from them and the appearance of recurrences, so that patients with multiple hernias should be studied looking for defects in the extracellular matrix.

References

1. López-Cano M, Fortuny G, Rodríguez-Navarro J, Armengol-Carrasco M, Susín A (2008) Read RC. Arthur Keith, the anatomist who envisioned herniosis. *Hernia* 11: 469-471. *Hernia* 12: 331.
2. Pascual-González G, Bellón-Caneiro JM (2013) Alteraciones de la matriz extracelular del tejido conectivo en el proceso de herniogénesis inguinal. *Rev Hispanoam Hernia* 1: 27-36.
3. Klinge U, Zheng H, Si ZY, Bhardwaj R, Klosterhalfen B, et al. (1999) Altered collagen synthesis in fascia transversalis of patients with inguinal hernia. *Hernia* 3: 181-187.
4. Klinge U, Junge K, Mertens PR (2004) Herniosis: a biological approach. *Hernia* 8: 300-301.
5. Ciuto-Varela P (2018) Hernias de la pared abdominal. *Clin Quir FM UdeLaR* 1-6.
6. Chica Alvarracin PA, Carrera Chinizaca VM, Sagñay Cujilema JC, Sinchiguano Chiluisa JY (2022) Hernia de pared abdominal, diagnóstico y tratamiento. *RECIMUNDO* 6: 128-135.
7. Ninos A (2006) The herniosis theory and the fate of a hernia following the removal of an infected mesh. *Hernia* 10: 449-450.
8. Cisneros-Muñoz HA, Mayagoitia-González JC, Cisneros-Rodríguez HM (2012) Otras manifestaciones o expresiones clínicas de herniosis (colagenosis) en adultos con hernia. *Cir Gen* 34: 43-47.