



## CASE REPORT

## Shiga Toxin 2 Mediated Hemolytic Uremic Syndrome Complicated By *Clostridium Septicum* Bacteremia in a 4-Year-Old

Peter Paul Lim, MD<sup>1\*</sup>, Christina Rae Nguyen, MD<sup>2</sup>, Daniel Rhoads, MD<sup>3,4</sup> and Arlene Dent, MD<sup>1</sup>

<sup>1</sup>Department of Pediatric Infectious Diseases, University Hospitals Cleveland Medical Center-Rainbow Babies and Children's Hospital, USA

<sup>2</sup>Department of Pediatric Nephrology, University Hospitals Cleveland Medical Center-Rainbow Babies and Children's Hospital, USA

<sup>3</sup>Department of Pathology, University Hospitals Cleveland Medical Center, USA

<sup>4</sup>Department of Pathology, Case Western Reserve University School of Medicine, USA

\*Corresponding author: Peter Paul Lim, MD, Department of Pediatric Infectious Diseases, University Hospitals Cleveland Medical Center-Rainbow Babies and Children's Hospital, Cleveland, Ohio, USA, Tel: 216-844-3282; 216-844-3645



### Abstract

Shiga toxin 2 (Stx2) is a potent toxin produced by shiga toxin-producing *E. coli* (STEC) that is commonly linked to development of hemolytic uremic syndrome (HUS). An extremely rare complication of shiga toxin associated (STEC) hemolytic uremic syndrome is concomitant infection with *Clostridium septicum*. The majority of pediatric patients with HUS complicated by *C. septicum* infection had complications including CNS involvement, severe renal insult often requiring hemodialysis, and myonecrosis warranting invasive surgical intervention, and prolonged administration of multiple antimicrobial agents. To date, there are 12 reported pediatric cases of HUS with concomitant *C. septicum* infection. Of the 12 reported cases, only 6 survived - all of whom warranted either surgical intervention, hemodialysis and prolonged antibiotic therapy, or both. We report a case of a 4-year-old female who presented with bloody diarrhea, emesis and fever with STEC HUS complicated by *C. septicum* bacteremia who was successfully treated with a short course of metronidazole without hemodialysis or surgical intervention.

### Keywords

HUS, *C. septicum*, Bacteremia, Shiga toxin

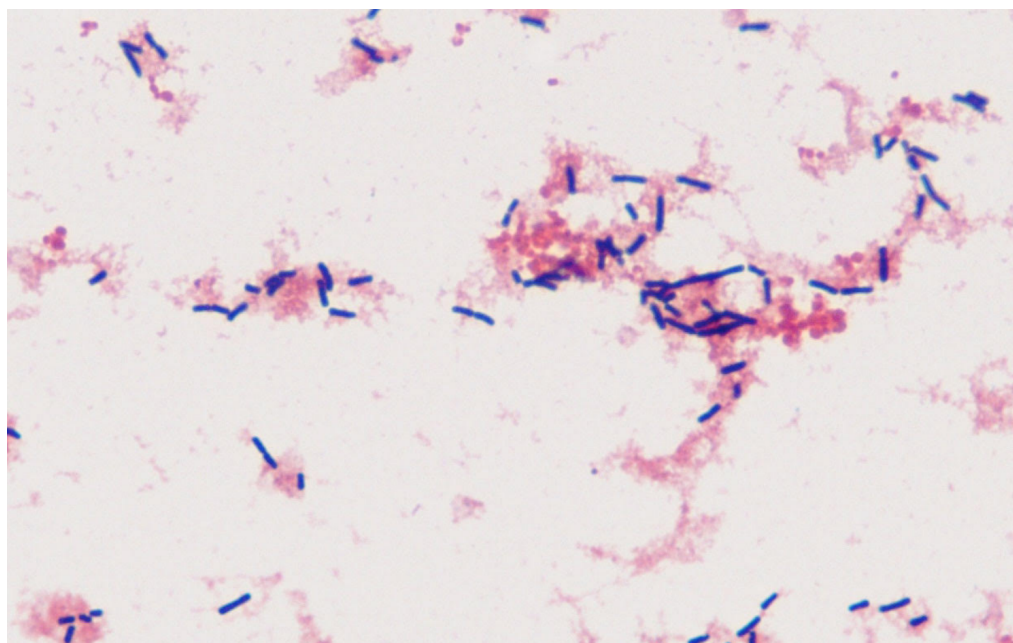
### Abbreviations

HUS: Hemolytic Uremic Syndrome; STEC: Shiga Toxin-producing *Escherichia coli*; Stx2: Shiga toxin 2; MIC: Minimum Inhibitory Concentration

### Case

A 4-year-old Caucasian female with developmental delay and cerebral palsy presented with profuse bloody diarrhea, abdominal pain and non-bilious, non-bloody emesis one day prior to admission. There was no identified potential exposure or sick contact other than a class zoo trip without her two weeks prior to presentation. Nucleic acid amplification testing for common enteric pathogens was performed on admission and Stx2 was detected. Leukocytosis (WBC  $20.8 \times 10^9/L$ ) with neutrophil predominance (ANC  $15.76 \times 10^9/L$ ) was identified. Other routine blood count and chemistry tests were within normal ranges. She was initially managed with intravenous fluid replacement.

On hospital day 2, an isolated fever of (38.4 °C) was recognized and resolved without intervention, but day 3 of hospitalization included intermittent bouts of fever (Tmax = 39.6 °C), leukocytosis (WBC  $30.3 \times 10^9/L$ ) and neutrophilia (ANC  $23.51 \times 10^9/L$ ) had increased, haptoglobin was low (< 30 mg/dL) and lactate dehydrogenase was elevated (430 U/L). Blood and urine cultures were obtained, and ceftriaxone 50 mg/kg was empirically started for a possible urinary tract infection based on urinalysis which showed leukocyturia of 51-100/HPF and large leukocyte esterase. Three hours following initial ceftriaxone administration, the patient's condition



**Figure 1:** Box-car shaped Gram-positive bacilli (*Clostridium septicum*) seen on Gram stain of the patient's blood culture under 1000x magnification.

worsened with increased fever (40.1 °C), tachycardia (139/min), tachypnea (30/min) and hypotension (94/50 mmHg). Hemoglobin and platelets had fallen below the reference range (8.6 g/dL &  $81 \times 10^9/L$ , respectively), and lactate dehydrogenase had markedly increased (1108 U/L). The patient developed acute hemolytic anemia and acute kidney injury consistent with hemolytic uremic syndrome (HUS). Ceftriaxone was held due to concern that it could potentially advance hemolysis and worsen renal function.

Serial labs showed nadir hemoglobin of 3.51 g/dL and a platelet count of  $6.1 \times 10^9/L$  on hospital day 4. The patient developed oliguric acute kidney injury with peak serum creatinine of 2.1 mg/dL on the same day. These findings further supported the diagnosis of HUS with its associated acute hemolysis and deteriorating renal function. Urine culture grew 20,000-80,000 CFU/ml of *Escherichia coli*. After 28 hours of incubation, the anaerobic blood culture bottle became positive with box-car-shaped gram-positive bacilli (Figure 1), which was later identified as *Clostridium septicum* by MALDI-TOF mass spectrometry. The patient received multiple blood transfusions on hospital days 6, 11, 13 and received platelet transfusion on hospital day 11.

The patient continued to have intermittent bloody diarrhea and tarry stools during her course of admission in the pediatric intensive care unit. Stooling returned to normal baseline on hospital day 9. She completed 7-day course of metronidazole for the *C. septicum* bacteremia per susceptibility result (MIC 0.125 to metronidazole). She was discharged on hospital day 15, and at discharge her lab results were normalizing with serum creatinine 0.57 mg/dL, hemoglobin 7.8 g/dL, and a platelet count  $179 \times 10^9/L$ .

## Discussion

*C. septicum* is a strictly anaerobic, gram-positive, alpha-toxin-producing bacillus that causes atraumatic, rapidly-progressive gas gangrene that is often precipitated by bacteremia from gut translocation secondary to compromised gastrointestinal mucosal surface from inflammation, neutropenic colitis, leukemia or diabetes [1,2]. Only about 2% of humans carry this bacterium in their gut microbiota [3]. Anaerobic blood culture is an absolute requirement if *C. septicum* is to be isolated as a cause of bacteremia. The etiology of the bacteremia is thought to be due to a compromised blood-gut barrier during colitis [1]. Twelve cases of *E. coli* HUS complicated by *C. septicum* bacteremia have been reported to date. Common presenting symptoms include bloody diarrhea, abdominal pain and fever. Clinical courses and treatment responses have been variable (Table 1) [2,4-13].

Many of these pediatric cases describe involvement of the CNS and soft tissues warranting surgical interventions in addition to antibiotics [5-7,9-12]. Of the patients with CNS involvement, only two patients survived despite prompt antibiotic therapy, hemodialysis, and neurosurgical intervention [6,9]. One patient received penicillin and metronidazole with emergent ventriculostomy but succumbed 6 hours after admission [10]. All three patients who neither received prompt medical nor surgical therapy did not survive [5,7,11]. One patient described without CNS involvement developed ecchymotic necrosis of right arm survived after antibiotic therapy and amputation of the ischemic extremity [2].

Iddings, et al. describes a 5-year-old male with newly diagnosed type 1 diabetes mellitus who initially presented in DKA and loose non-bloody stools who developed

**Table 1:** Review of reported cases of HUS with concomitant *C. septicum* infection.

Patient	Presentation	Exposure	Diagnostic culture	Antibiotic/HD/surgery	Outcome	Reference
5 y/F	Fever, abdominal pain, emesis, weight loss, T1DM in DKA	No known exposure	Blood	Piperacillin-tazobactam, Ampicillin, Fluconazole x 21 days/HD/+ sigmoid colectomy, colon resection, ostomy placement	Survived, discharged hospital day 80	Iddings AC, et al. [4]
3 y/F	Fever, bloody diarrhea, abdominal pain, neurologic deterioration	Cattle farm	Brain, colon biopsy	None	Death at 36 hours of admission	Engen RM, et al. [5]
4 y/F	Fever, bloody diarrhea, abdominal pain	Petting zoo	Blood culture	Metronidazole 4 mg/kg q6h, Clindamycin 10 mg/kg q8h, Meropenem 20 mg/kg q24h x 14 days/HD/-	Survived, discharged hospital day 19	Engen RM, et al. [5]
6 y/F	Fever, bloody diarrhea, abdominal pain, irritability	No known exposure	Blood culture	Penicillin G 20, 000 U/kg IV q6h x 7 days/HD/-	Survived, discharged hospital day 21	Engen RM, et al. [5]
2 y/M	Bloody diarrhea, lethargy, pallor, oliguria	Dairy farm	Brain biopsy, cranial burr hole drain culture	Meropenem, Metronidazole, Clindamycin, Linezolid x several months/HD/+ craniectomy	Survived, repeat MRI day +462 with no residual abscess	Williams EJ, et al. [6]
2 y/M	Bloody diarrhea, anuria, acute respiratory failure	Unknown	Blood culture, brain, lung, kidney, liver, bowel autopsy	None	Death at 14 hours of admission	Martin SE, et al. [7]
19 m/M	Bloody diarrhea, anuria, facial and leg edema, R arm ecchymosis	No known exposure	R arm wound culture	Penicillin, Clindamycin x 14 days/-/+ amputation	Survived, discharged at hospital day 22	Hunley TE, et al. [2]
2 y/M	Bloody diarrhea, vomiting, fever, petechial rash, fasciitis	Unknown	Blood culture	Cefuroxime, metronidazole/PD/-	Death at 8 hours of admission	Barnham M, et al. [8]
2 y/M	Bloody diarrhea, emesis, abdominal cramping, lethargy	Unknown	Brain abscess culture	Penicillin, Metronidazole x 6 weeks/HD/+ craniotomy	Survived	Chiang V, et al. [9]
2 y/F	Bloody diarrhea, fever, vomiting, L sided focal seizure, acute neurologic demise	Unknown	CSF and blood cultures, autopsy of colon	Penicillin 75,000 U/kg, Metronidazole 7.5 mg/kg/-/+ emergent ventriculostomy	Death at 6 hours of admission	Broughton RA, et al. [10]
4 y/M	Bloody diarrhea, abdominal pain, seizures, acute neurologic demise	Unknown	Brain autopsy	None/PD/-	Death at ~50 hours of admission	Randall JM, et al. [11]
16 m/M	Bloody diarrhea, fever, seizures, abdominal rash, acute neurologic demise	Unknown	Skin culture, post-mortem blood culture, brain and colon autopsy	Ampicillin, clindamycin, gentamicin/-/-	Death at 2 days of admission	Riccio J, et al. [12]

HD: Hemodialysis; PD: Peritoneal dialysis; T1DM: Type 1 diabetes mellitus; DKA: Diabetic ketoacidosis.

HUS from Shiga-like toxin producing *E. coli* O157:H7 with concomitant *C. septicum* bacteremia [4]. He subsequently developed intestinal perforation warranting exploratory laparotomy, sigmoid colon resection and diverting loop ostomy placement. He developed high-output chronic kidney disease from HUS and needed hemo-

dialysis. The patient's course was further complicated by polymicrobial peritonitis. He was successfully treated with 21-day course of antibiotics.

The current case is the third pediatric uncomplicated case of *E. coli* HUS with *C. septicum* bacteremia that has been reported. Similar to the current case, the other

two cases were successfully managed with antibiotics and not surgical intervention, but temporary hemodialysis was required in the other two cases [5]. The first was a case of a 4-year-old female exposed to a petting zoo who presented with fever, bloody diarrhea and abdominal pain. She was treated with metronidazole, clindamycin and meropenem for 14 days. The other case was of a 6-year-old female without known exposure who presented similarly and who received 7 days of penicillin. Both patients survived without reported sequelae. Of the reported cases of *E. coli* HUS complicated by *C. septicum* bacteremia, half (7/13) of the patient died, and half (3/6) survivors required surgical intervention with most (5/6) requiring hemodialysis. To our knowledge, the current case is the only reported case of *E. coli* HUS complicated by *C. septicum* bacteremia to be successfully treated with only a short course of metronidazole and no hemodialysis or surgical intervention.

## Conclusion

This article presents a rare case of Stx2-mediated hemolytic uremic syndrome with *Clostridium septicum* bacteremia that was successfully treated with short course antibiotic without necessitating hemodialysis or surgical intervention.

## Authors Contribution

All authors equally contributed to the work of this manuscript.

## Conflicts of Interest

Authors declare no conflict of interest.

## References

- Kennedy CL, Krejany EO, Young LF, O'Connor JR, Awad MM, et al. (2005) The alpha-toxin of *Clostridium septicum* is essential for virulence. *Mol Microbiol* 57: 1357-1366.
- Hunley TE, Spring MD, Peters TR, Weikert DR, Jabs K (2008) *Clostridium septicum* myonecrosis complicating diarrhea-associated hemolytic uremic syndrome. *Pediatr Nephrol* 23: 1171-1175.
- King A, Wight DG (1987) *Clostridium septicum* and neutropenic enterocolitis. *Lancet* 2: 1279.
- Iddings AC, Shenoi AN, Pozzo AM, Kiessling SG (2017) Hemolytic uremic syndrome complicated by *Clostridium septicum* bacteremia and new-onset type 1 diabetes mellitus. Report of a case. *Clin Nephrol* 87: 207-211.
- Engen EM, Killien EY, Davis JL, Symons JM, Hartmann SM (2017) *C septicum* complicating hemolytic uremic syndrome: Survival without surgical intervention. *Pediatrics* 139: e20161362.
- Williams EJ, Mitchell P, Mitra D, Clark JE (2012) A microbiological hazard of rural living: *Clostridium septicum* brain abscess in a child with *E coli* 0157 associated haemolytic uraemic syndrome. *BMJ Case Rep* 2012.
- Martin SE, Allen SD, Faught P, Hawley DA, Bonnin JM, et al. (2012) A 2-year-old boy with hemolytic uremic syndrome and pneumocephalus. *Brain Pathol* 22: 121-124.
- Barnham M, Weightman N (1998) *Clostridium septicum* infection and hemolytic uremic syndrome. *Emerg Infect Dis* 4: 321-324.
- Chiang V, Adelson PD, Poussaint TY, Hand M, Churchwell KB (1995) Brain abscesses caused by *Clostridium septicum* as a complication of hemolytic-uremic syndrome. *Pediatr Infect Dis J* 14: 72-74.
- Broughton RA, Lee EY (1993) *Clostridium septicum* sepsis and meningitis as a complication of the hemolyticuremic syndrome. *Clin Pediatr (Phila)* 32: 750-752.
- Randall JM, Hall K, Coulthard MG (1993) Diffuse pneumocephalus due to *Clostridium septicum* cerebritis in haemolytic uraemic syndrome: CT demonstration. *Neuroradiology* 35: 218-220.
- Riccio JA, Oberkircher OR (1988) *Clostridium septicum* sepsis and cerebritis: A rare complication of the hemolyticuremic syndrome. *Pediatr Infect Dis J* 7: 342-345.
- Smith-Slatas CL, Bourque M, Salazar JC (2006) *Clostridium septicum* infections in children: A case report and review of the literature. *Pediatrics* 117: e796-e805.