



CASE REPORT

Abdominal Compartment Syndrome in a Patient Suspected of Coronavirus 2019 (COVID-19)

Rony Shah, MD*, Linda Klumpp, MD, Naeem Syed, DO, Parth Patel, MD and Jeffrey Jordan, MD



Healthcare/USF Morsani College of Medicine, GME Programs at Citrus Memorial Hospital, Inverness, Florida, USA

*Corresponding author: Rony Shah, MD, Healthcare/USF Morsani College of Medicine, GME Programs at Citrus Memorial Hospital, Inverness, Florida, USA

Abstract

Severe acute respiratory syndrome coronavirus (SARS-CoV-2) is a novel coronavirus which has become a worldwide pandemic, the other common coronaviruses to cause deadly respiratory disease are SARS-CoV and MERS-CoV. SARS-CoV-2, SARS-CoV, and MERS-CoV are commonly transmitted through respiratory droplets and direct contact. Patients with SARS-CoV-2 can present with varying severity from asymptomatic to multi-organ failure. We present a rare case of abdominal compartment syndrome in a patient suspected of coronavirus 2019 (COVID-19).

A 59-year-old male presented to the emergency room (ER) complaining of abdominal pain, urinary retention, and abdominal distension. He gave a past medical history of hypertension, nephrolithiasis, and recent outpatient treatment for acute bronchitis. The following day patient developed fever, altered mental status, and shortness of breath. Patient underwent surgery and was found to have abdominal compartment syndrome. Daily chest X-ray demonstrated worsening bilateral pulmonary infiltrates concerning for an underlying COVID-19 infection. Patient's wife was positive for COVID-19.

Coronaviruses are known to cause respiratory or intestinal infections in humans and animals. Patient's onset of symptoms is about four to five days after being infected. Our patient may have mistakenly been diagnosed with bronchitis instead of COVID-19 prior to his hospitalization. The combination of a COVID-19 infection with abdominal compartment syndrome gave our patient a poor prognosis. We are hoping our case report will be able to bring more awareness and highlight a rare presentation of COVID-19.

a worldwide pandemic with more than 2.5 million cases reported and more than 175,000 confirmed deaths [1]. The first case was reported in early December 2019 in Wuhan, China and the first case in the United States was reported on January, 22, 2019 in the state of Washington [2-4]. The coronaviruses are enveloped RNA viruses that are found in humans, mammals, and other birds and they can cause respiratory, hepatic, enteric, and neurologic diseases [3]. The other two strains of the coronavirus, severe acute respiratory syndrome coronavirus (SARS-CoV) and Middle East respiratory syndrome coronavirus (MERS-CoV) have been known to cause fatal disease as well [3]. SARS-CoV was responsible for the outbreaks in China in 2002 and 2003 [3]. MERS-CoV was the pathogen that caused severe respiratory disease in the Middle East in 2012 [3]. SARS-CoV-2, SARS-CoV, and MERS-CoV are commonly transmitted through respiratory droplets and direct contact [5]. We present a rare case of abdominal compartment syndrome in a patient suspected of coronavirus 2019 (COVID-19).

Case Description

A 59-year-old male presented to the emergency room (ER) complaining of abdominal pain, urinary retention, and abdominal distension. He gave a past medical history of hypertension and nephrolithiasis. Patient reported worsening abdominal distension with decreased urination and bowel movements over the past five days. He took over-the-counter laxatives to help with his constipation but had minor improvement in bowel movements, his last bowel movement was four days ago. Pa-

Introduction

Severe acute respiratory syndrome coronavirus (SARS-CoV-2) is a novel coronavirus which has become



Citation: Shah R, Klumpp L, Syed N, Patel P, Jordan J (2020) Abdominal Compartment Syndrome in a Patient Suspected of Coronavirus 2019 (COVID-19). J Infect Dis Epidemiol 6:139. doi.org/10.23937/2474-3658/1510139

Received: May 08, 2020; **Accepted:** July 01, 2020; **Published:** July 03, 2020

Copyright: © 2020 Shah R, et al. This is an open-access article distributed under the terms of the Creative Commons Attribution License, which permits unrestricted use, distribution, and reproduction in any medium, provided the original author and source are credited.

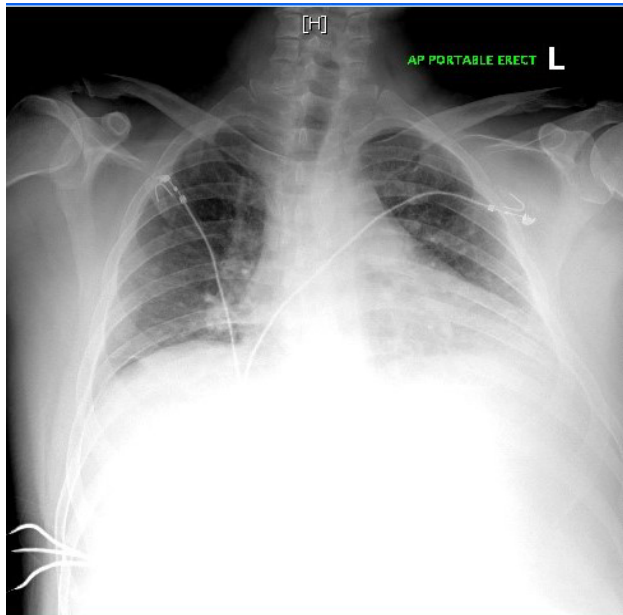


Figure 1: Chest X-ray revealed poor inspiratory effort with no evidence of acute pathology.

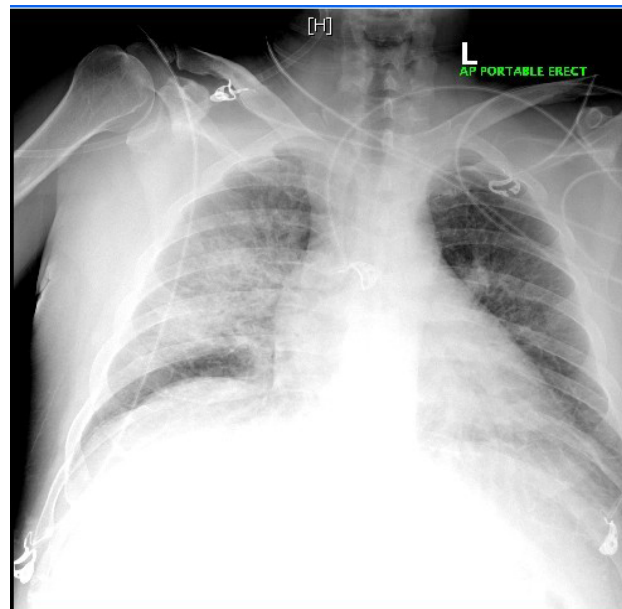


Figure 2: Chest X-ray demonstrated increased bilateral interstitial and alveolar opacities with findings suspicious for pneumonia or pulmonary edema.

tient went to his primary care physician two days prior to coming to the ER and was prescribed doxycycline for bronchitis. Vitals were temperature: 98.1 F, blood pressure: 151/88 mmHg, heart rate: 119 beats per minute, respiratory rate: 16 breaths per minute, oxygen saturation: 97%. Physical examination revealed a distended abdomen with diffuse tenderness. Laboratory results were significant for white blood count (WBC): 39.6, hemoglobin (Hg): 13.6, platelet: 16, blood urea nitrogen (BUN)/creatinine: 36 mg/dL/2.1 mg/dL, aspartate aminotransferase (AST): 137 U/L, alanine aminotransferase (ALT): 281 U/L, alkaline phosphatase: 121 U/L, amylase: 38 U/L, lipase: 25 U/L, lactic acid: 1.91 mmol/L. Urinalysis was negative. Chest X-ray revealed poor inspiratory effort with no evidence of acute pathology (Figure 1). Right upper quadrant ultrasound demonstrated hepatomegaly with fatty infiltration. Computed tomography (CT) of abdomen and pelvis revealed possible acute pancreatitis, a 5 mm calculus at the right ureteropelvic junction without any evidence of hydronephrosis. Patient was started on ceftriaxone and metronidazole for empiric coverage. The next day he developed fever, altered mental status, shortness of breath, worsening tachycardia, and severe abdominal distention with hyperactive bowel sounds. Patient was transferred to the medical intensive care unit (ICU) for closer monitoring. Patient was being treated for severe sepsis with aggressive fluid resuscitation and empiric antibiotic coverage. The source of infection was unknown but there was a high suspicion for intra-abdominal pathology. His antibiotic coverage was changed to meropenem and metronidazole for broader coverage. Patient was evaluated for his thrombocytopenia present since admission and it was believed to be secondary to early disseminated intravascular coagulation (DIC). Repeat CT abdomen/pelvis demonstrated development of bilateral pulmo-

nary edema or infiltrates, hepatic steatosis, mild splenomegaly, bilateral nonobstructing nephrolithiasis, and colonic diverticulosis. Chest X-ray demonstrated increased bilateral interstitial and alveolar opacities with findings suspicious for pneumonia or pulmonary edema (Figure 2). Patient underwent a diagnostic laparoscopy for suspected ischemic bowel which revealed a significant amount of pressure in the abdomen which limited visualization. There were no signs of necrotic bowel, perforation, abdominal fluid, or any other pathology. The peak airway pressure remained greater than 40 mmHg and the small bowel appeared pale on diagnostic laparoscopy so the surgery was converted to an exploratory laparotomy. The small bowel initially appeared to be pale but became pink with adequate perfusion and an intact mesenteric pulse following the decompressive laparotomy. The combination of elevated peak airway pressure and improvement of the bowel appearance following the decompressive laparotomy, abdominal compartment syndrome was suspected. Due to the elevated intra-abdominal pressure it was left open with an open abdomen negative pressure therapy wound vacuum-assisted closure (VAC) device. The peak airway pressure improved to 25 mmHg at the end of the procedure but did not return to normal. Repeat chest X-ray following the procedure demonstrated worsening bilateral consolidative airspace opacity since the previous chest X-ray (Figure 3). Antibiotic coverage was changed to vancomycin and meropenem following the procedure. Patient was hemodynamically unstable following the procedure requiring mechanical ventilation, vasopressor support, and abdominal wound VAC. Patient went into cardiac arrest with the initial rhythm being pulse electrical activity (PEA) and immediate advanced cardiovascular life support treatment was started. The

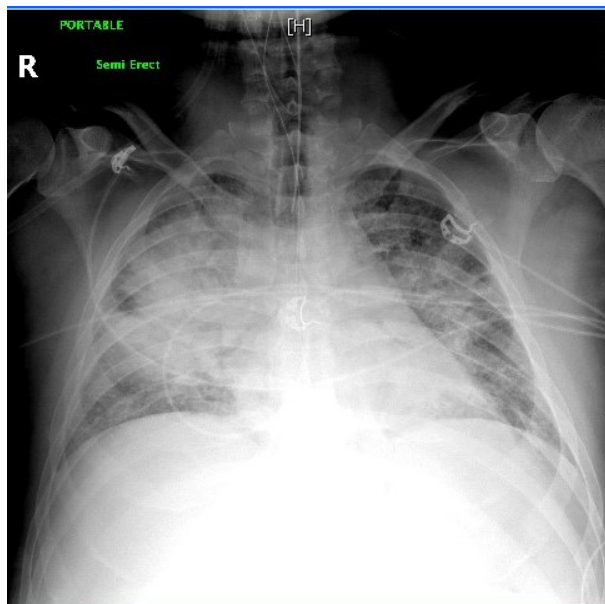


Figure 3: Repeat chest X-ray following the procedure demonstrated worsening bilateral consolidative airspace opacity since the previous chest X-ray.

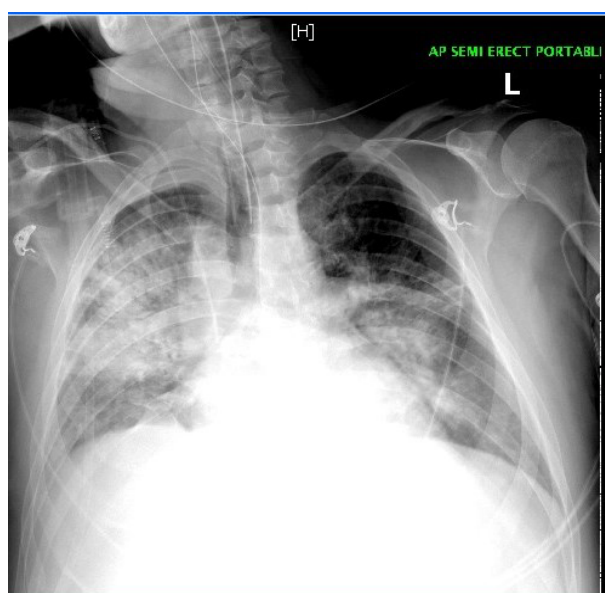


Figure 4: Repeat chest X-ray prior to the cardiac arrest demonstrated worsening bilateral airspace opacities suggestive of pulmonary edema or pulmonary infiltrates.

rhythm converted to Torsades and eventually asystole. Patient was unable to be resuscitated and bedside ultrasound confirmed cardiac standstill. Repeat chest X-ray prior to the cardiac arrest demonstrated worsening bilateral airspace opacities suggestive of pulmonary edema or pulmonary infiltrates (Figure 4). On further review of the chest X-ray the findings may be suggestive of SARS-CoV-2 disease. There was increased suspicion of this because the patient's wife presented with SARS-CoV-2 symptoms two days after his death requiring hospitalization. She tested positive for SARS-CoV-2.

Discussion

Coronaviruses are known to cause respiratory or

intestinal infections in humans and animals [6]. SARS-CoV-2 virus is related to the bat coronaviruses and to SARS-CoV-1, it enters human cells through the angiotensin-converting-enzyme 2 (ACE2) receptors [7]. SARS-CoV-2 virus is primarily spread from person to person through respiratory droplets, which are typically released by an infected person coughing or sneezing [7]. Transmission typically does not occur through inhalation of aerosols, which are virions suspended in the air, but the virus may linger in aerosols for more than three hours which increases the risk of exposure [7]. Our patient's wife was at bedside throughout his hospitalization which increased her risk of exposure. SARS-CoV-2 RNA has been detected in blood and stool, but oral fecal route has not been documented [7]. Reports suggest that patients may be infectious one to three days before the onset of symptoms and up to 40 to 50% of cases are due to transmission from asymptomatic or presymptomatic patients [7]. The time period from exposure to symptom onset is approximately four to five days and 97.5% of symptomatic patients will have symptoms within 11.5 days after infection [7]. Common symptoms are fever, cough, sore throat, malaise, myalgias, loss of smell, loss of taste, and gastrointestinal symptoms such as anorexia, nausea, and diarrhea [7]. Shortness of breath may develop five to eight days after onset of the initial symptoms [7]. Our patient may have been mistakenly diagnosed with bronchitis prior to his hospitalization. His symptoms of bronchitis and abdominal pain in addition to developing altered mental status, fever, and shortness of breath during his hospitalization, within five to eight days of his initial symptoms makes a SARS-CoV-2 infection very likely. Risk factors associated with COVID-19 complications are age (> 65), cardiovascular disease, chronic lung disease, hypertension, diabetes, and obesity [7]. Other conditions with presumed increased risk of complications are kidney disease, immunosuppression, malignancy, and uncontrolled human immunodeficiency virus (HIV) [7]. In our case the patient's only risk factor was hypertension. The diagnosis of COVID-19 is made by detection of SARS-CoV-2 by polymerase-chain-reaction (PCR) assay [7]. Evaluation and management of COVID-19 is guided by the severity of the disease. Severe disease was defined as marked tachypnea (respiratory rate > 30 breaths per minute), hypoxemia (Oxygen saturation < 93%), ratio of partial pressure of arterial oxygen to fraction of inspired oxygen (< 300), and lung infiltrates (> 50% of the lung field within 24 to 48 hours) [7]. Our patient had severe disease exacerbated by his underlying abdominal compartment syndrome. A case series by Bhatraju, et al. found that 96% of ICU patient's chest radiographs showing bilateral pulmonary opacities [2]. In our case the patient's chest X-ray showed worsening bilateral pulmonary opacities daily. Hypotension requiring vasopressor support in patients without a secondary infection was found in 71% of the patients reported in a case series by Bhatraju, et al. [2]. In our case vasopressor support

was needed to maintain a mean arterial pressure > 65 mmHg. A recent study showed that critical patients with COVID-19 showed signs of organ dysfunction, including ARDS in 67%, acute kidney injury in 29%, cardiac injury in 23%, and liver dysfunction in 29% [6]. Our patient exhibited multi-organ dysfunction such as acute kidney injury, liver dysfunction, hypoxemic respiratory failure, and eventual cardiac injury. Viral infections may trigger arrhythmias due to a combination of significant systemic inflammatory response and vascular inflammation at the arterial plaque level [6]. Our patient went into sudden cardiac arrest for multiple reasons but one of the main reasons could be his underlying COVID-19 infection. As reported by Shi, et al. cardiac injury is a common condition among hospitalized patients with COVID-19 and is associated with a higher risk of in-hospital mortality [8]. Another study reported that 44% of patients with COVID-19 were transferred to the ICU due to arrhythmias [6].

Our patient had abdominal compartment syndrome due to an unknown etiology except for possible severe septic shock. His abdominal compartment syndrome may have contributed to his ventilation defects, decreased cardiac output, oliguria, and altered mental status [9,10]. The pathogenesis for abdominal compartment syndrome due to shock occurs from vasoconstriction mediated by the sympathetic nervous system leading to decreased blood flow to the skin, muscles, kidneys, and gastrointestinal tract to preserve blood flow to the brain and heart [10]. Decreased splanchnic circulation and intestinal tissue hypoxia is associated with three critical factors (cytokine release, free radical formation, and decreased ATP production) which lead to intra-abdominal hypertension and abdominal compartment syndrome [10]. It is possible that our patient's symptoms may have been exacerbated by his underlying abdominal compartment syndrome but the overwhelming evidence makes a COVID-19 infection very likely. To the best of our knowledge no other cases of coronavirus with abdominal compartment syndrome have been previously reported.

Conclusion

The SARS-CoV-2 virus has become one of the most deadly worldwide pandemics in recent history. Every day we are gaining a deeper understanding of the symptoms and diseases associated with COVID-19 patients. Physicians need to be able to recognize unusual presentations of COVID-19 because at this time we do not have enough information to predict clinical course,

severity, and complications associated with the disease. Focusing on treating other medical conditions such as cardiovascular disease, renal disease, gastrointestinal disease, and coagulopathy can lead to a missed diagnosis of COVID-19 as seen in our patient. Recent data is suggesting that increased mortality rate of all medical conditions may have been driven by an underlying COVID-19 infection. We hope our case report will bring more awareness and highlight a rare presentation of COVID-19.

Consent

The patient provided informed consent.

Disclaimer

This research was supported in part by HCA Healthcare and/or an HCA Healthcare affiliated entity. The views expressed in this publication represent those of the author(s) and do not necessarily represent the official views of HCA Healthcare or any of its affiliated entities.

References

1. Center for Disease Control and Prevention (2020) Coronavirus (COVID-19).
2. Bhatraju P, Ghassemieh B, Nichols M, Kim R, Jerome KR, et al. (2020) COVID-19 in critically ill patients in the Seattle region- case series. *N Engl J Med* 382: 2012-2022.
3. Zhu N, Zhang D, Wang W, Li X, Yang B, et al. (2020) A novel coronavirus from patients with pneumonia in China, 2019. *N Engl J Med* 382: 727-733.
4. Holshue M, DeBolt C, Lindquist S, Lofy K, Wiesman J, et al. (2020) First case of 2019 novel coronavirus in the United States. *N Engl J Med* 382: 929-936.
5. Guan W, Zheng-yi N, Hu Y, Liang W, Ou C, et al. (2020) Clinical characteristics of coronavirus disease 2019 in China. *N Engl J Med* 382: 1708-1720.
6. Madjid M, Safavi-Naeini P, Solomon S, Vardeny O (2020) Potential effects of coronavirus on the cardiovascular system. *JAMA Cardiol*, E1-E10.
7. Gandhi R, Lynch J, Rio C (2020) Mild or moderate COVID-19. *N Engl J Med*.
8. Shi S, Qin M, Shen B, Cai Y, Liu T, et al. (2020) Association of cardiac injury with mortality in hospitalized patients with COVID-19 in Wuhan, China. *JAMA Cardiol*, E1-E8.
9. Rogers W, Garcia L (2018) Intraabdominal hypertension, abdominal compartment syndrome, and the open abdomen. *CHEST* 153: 238-250.
10. Pereira B (2019) Abdominal compartment syndrome and intra-abdominal hypertension. *Curr Opin Crit Care* 25: 688-696.