



CASE REPORT

Eye Movements Induced by Stimulation of the Utricle

Hiroaki Ichijo, MD, PhD*

Ichijo Ear, Nose and Throat Clinic, Japan

*Corresponding author: Hiroaki Ichijo, MD, PhD, Ichijo Ear, Nose and Throat Clinic, 3-2-1, Ekimae, Hirosaki, 036-8002, Japan, Tel: +81-172-39-6222, Fax: +81-172-39-6222



Abstract

Background and aims: Pathophysiology of benign paroxysmal positional vertigo (BPPV) is canalolithiasis in the semicircular canal. The principle of Epley maneuver is moving debris from a long arm to the utricle, therefore debris stimulates the utricular macula in the sitting position after the treatment. To clarify the characteristics of eye movements evoked by the stimulation of unilateral macula of the utricle.

Methods: The subjects were ten patients with posterior semicircular canal BPPV. After the diagnosis, we performed Epley maneuver immediately. We observed and recorded eye movements in the sitting position (chin-down 30°) just after the treatment.

Results: No one showed nystagmus in the sitting position after the treatment. In all patients, positional nystagmus disappeared two days after the treatment.

Conclusion: Nystagmus does not occur by the stimulation to the macula of the utricle.

Keywords

Benign paroxysmal positional vertigo, Canalolithiasis, Epley maneuver, Otolith ocular reflex, Video-oculography

Introduction

Peripheral vestibular disorder, which causes provocative vertigo and robust torsional nystagmus in the head-hanging position, is known as benign paroxysmal positional vertigo (BPPV) and was formerly thought to be an otolith organ disorder [1]. However, the canalith repositioning procedure [2] and operative findings [3] supported the theory of canalolithiasis in the posterior semicircular canal. Previous studies demonstrated the efficacy of the Epley maneuver, and it is used worldwide for the purposes of treatment [4].

The principle of the Epley maneuver is the movement of debris from the long arm to the utricle, which stimulates the utricular macula in the sitting position after the treatment (Figure 1).

The utricular macula is located on the floor of the utricle, approximately in the plane of the lateral semicircular canal, and is oriented to respond best to lateral (ear to shoulder) tilts and side-to-side or fore-and-aft translations of the head. Although excitation of hair cells may produce eye movements, the details of the otolith ocular reflex are unknown.

In animal experiments, electrical stimulation of the utricular nerve produced various patterns of eye movements. Suzuki, et al. [5] reported that there was a vertical deviation of the optic axes (skew deviation) and a horizontal deviation, in addition to a torsional component. Moreover, Goto, et al. [6] reported that horizontal eye movements were evoked. However, there is not a physiological consensus regarding otolith ocular reflex.

The aim of the present study was to clarify the characteristics of eye movements evoked by the stimulation of unilateral macula of the utricle.

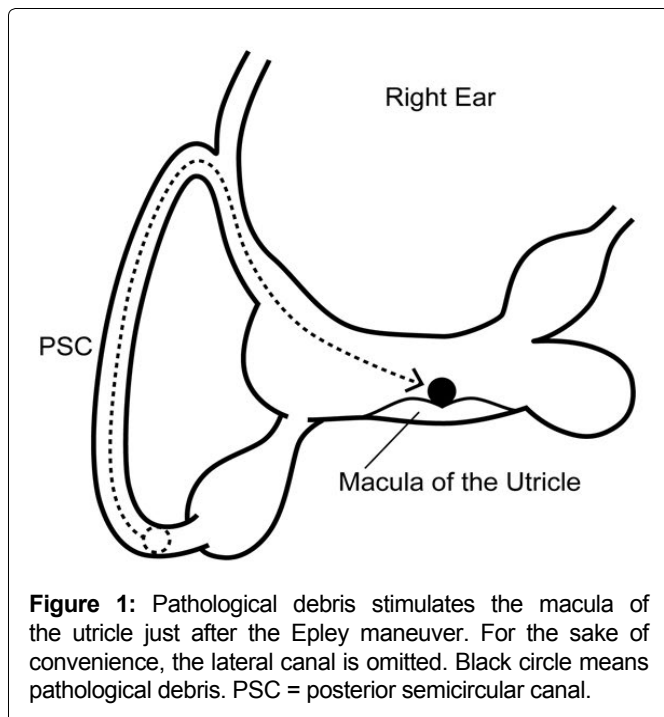
Material and Methods

Subjects

The subjects were ten patients with posterior semicircular canal BPPV who visited our institution between January 2022 and April 2022.

Inclusion criteria

1. The Dix-Hallpike test [1] revealed upward vertical



and torsional nystagmus with some latency period in the head-hanging position.

2. In the sitting position, vertical and torsional nystagmus occurred, and the direction was opposite to that in the head-hanging position.
3. In both positions, nystagmus stopped within 1 minute.
4. Epley maneuver was effective.

Exclusion criteria

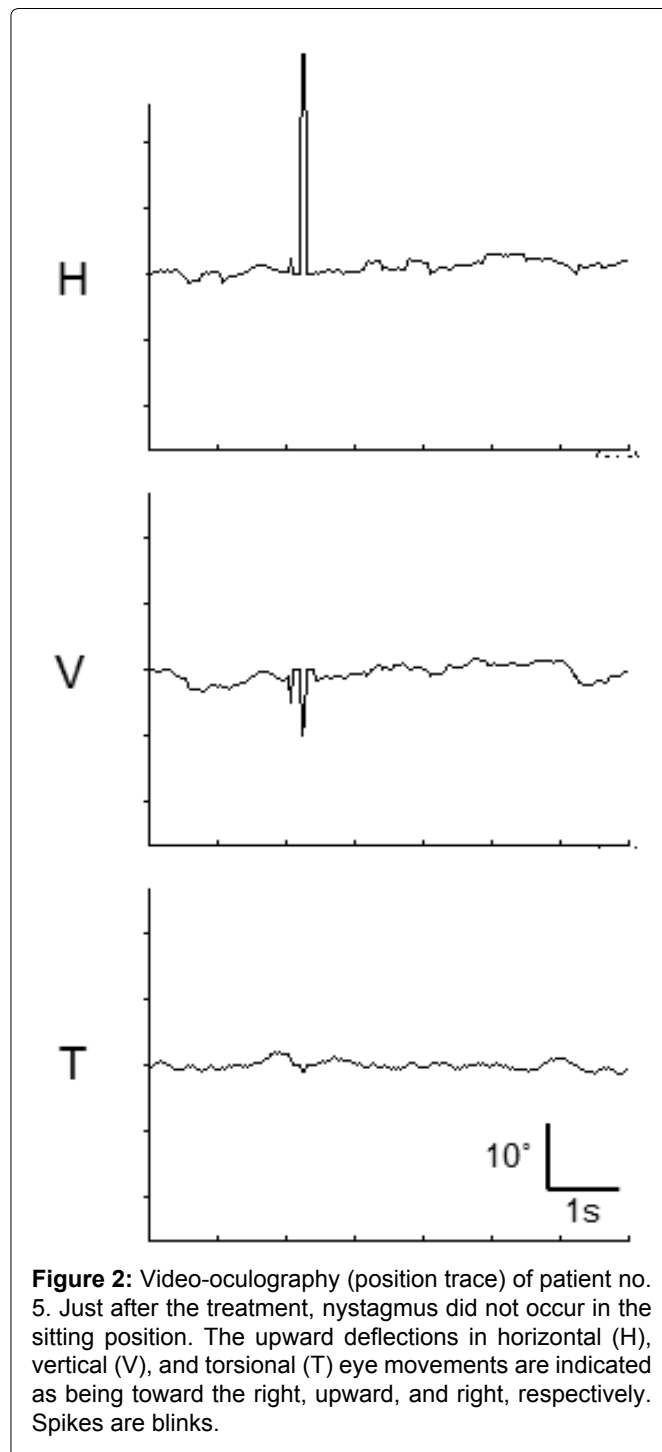
1. Cochlear symptoms related to vertigo.
2. Central nervous system disorders.
3. History of head trauma.

Nystagmus testing and analysis

Nystagmus testing was performed in the dark with the patients' eyes open using an infrared charge-coupled device camera. Eye movements were recorded and converted to digital data. Three-dimensional video-oculography was performed using ImageJ version 1.36 software (a public domain, Java-based image-processing program developed at the National Institutes of Health). For analysis of horizontal and vertical components, the XY center of the pupil was calculated. For analysis of the torsional component, the whole iris pattern, which was rotated in steps of 0.1° , was overlaid with the same area of the next iris pattern, and the angle at which both iris patterns showed the greatest match was calculated [7].

Treatment

After the diagnosis, we performed the Epley maneuver. The detail of treatment is available elsewhere [4]. We observed and recorded eye movements in the sitting position (chin-down 30°) just after the treatment.



Results

Video-oculography results of patient no. 6 are shown in Figure 2. A movie of patient no. 3 is shown in Supplemental Material (Video 1). Just after the treatment, none of the patients showed nystagmus in the sitting position, and none complained of dizziness (Table 1). In all patients, positional nystagmus disappeared two days after the treatment. There were no complaints of residual dizziness.

Discussion

We found that nystagmus does not occur by stimulus to the unilateral macula of the utricle. In all patients, as both positional nystagmus and dizziness disappeared two days after the treatment, the debris returned to the

Table 1: Results.

Patient	Age (years)	Sex	Affected side	Just after treatment		2 days after treatment	
				Nystagmus (Sitting)	Dizziness	Nystagmus (Head-hanging)	Dizziness
1	43	Female	Left	-	-	-	-
2	50	Female	Right	-	-	-	-
3	54	Male	Right	-	-	-	-
4	63	Female	Right	-	-	-	-
5	72	Female	Left	-	-	-	-
6	74	Female	Left	-	-	-	-
7	74	Female	Right	-	-	-	-
8	75	Female	Left	-	-	-	-
9	78	Female	Left	-	-	-	-
10	82	Female	Left	-	-	-	-

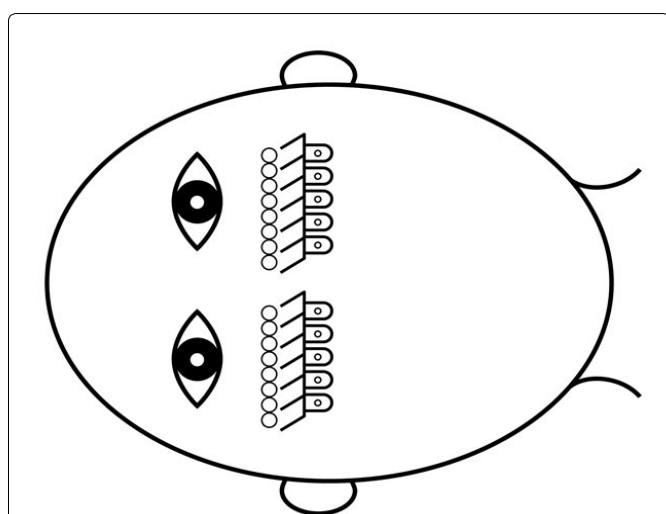


Figure 3: When a human lies down on the right side, otoconia on the utricular macula move to the right side. If utricle ocular reflex occurs, leftward nystagmus should occur in the same fashion as a leftward lineal acceleration; however, nystagmus does not occur in actuality.

utricle. Despite the debris stimulating the macula of the utricle, nystagmus did not occur. This phenomenon is a new finding regarding otolith ocular reflex.

Curthoys [8] reported that upward eye movements were evoked by stimulation to the unilateral macula of the utricle using guinea pigs; however, this finding may not be relevant to studies of human responses, because torsional eye movements occur by head tilt in humans.

When a human lies down on the right side, otoconia on the utricular macula move to the right side. If utricle ocular reflex occurs, leftward nystagmus should arise in the same fashion as a leftward lineal acceleration. However, nystagmus does not occur in actuality. This suggests that the utricle does not produce nystagmus (Figure 3).

Our findings suggest that the semicircular canal ocular reflex responds to linear acceleration. The head has six semicircular canals that respond to all direction

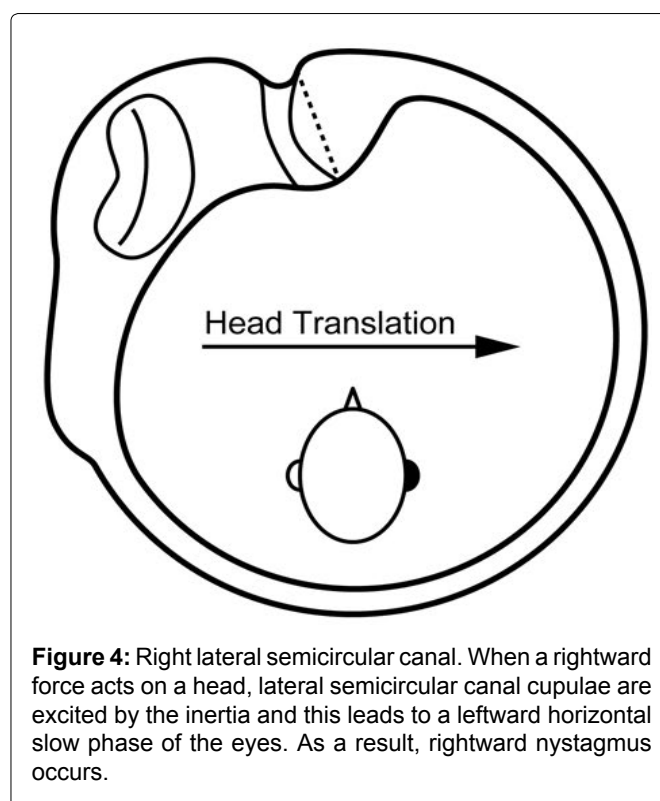


Figure 4: Right lateral semicircular canal. When a rightward force acts on a head, lateral semicircular canal cupulae are excited by the inertia and this leads to a leftward horizontal slow phase of the eyes. As a result, rightward nystagmus occurs.

of acceleration. For example, side-to-side movements stimulate the lateral canal cupula and horizontal nystagmus occurs (Figure 4).

It is generally believed that ocular counter-rolling is derived from the utricle. There are two types of ocular counter-rolling: dynamic torsion and static torsion. This study suggests that dynamic torsion does not occur from the utricle and is a semicircular canal ocular reflex. However, we did not obtain any findings regarding static torsion because of the limitation of the device. Moreover, we were unable to assess skew deviation as we performed single eye recording.

Conclusion

Nystagmus does not occur by the stimulation to the macula of the utricle; hence, eye movements derived

from a horizontal linear acceleration are a semicircular canal ocular reflex.

Acknowledgements

We thank Dr. Kazunori Futai for preparing some of the figures.

Declarations

Funding

None.

Conflict of interest

We declare that we have no conflict of interest.

Ethical approval

All procedures performed in study involving human participants were in accordance with the ethical board of the Hirosaki Medical Association (certificate number is 2022-12) and with the 1964 Helsinki declaration and its later amendments or comparable ethical standards.

References

1. Dix MR, Hallpike CS (1952) The pathology, symptomatology and diagnosis of certain common disorders of the vestibular system. *Ann Otol Rhinol Laryngol* 61: 987-1016.
2. Epley JM (1992) The canalith repositioning procedure: for treatment of benign paroxysmal positional vertigo. *Otolaryngol Head Neck Surg* 107: 399-404.
3. Parnes LS, McClure JA (1992) Free-floating endolymph particles: A new operative finding during posterior semicircular canal occlusion. *Laryngoscope* 102: 988-992.
4. Kim JS, Zee DS (2014) Clinical practice. Benign paroxysmal positional vertigo. *N Engl J Med* 370: 1138-1147.
5. Suzuki JI, Tokumasu K, Goto K (1969) Eye movements from single utricular nerve stimulation in the cat. *Acta Otolaryngol* 68: 350-362.
6. Goto F, Meng H, Bai R, Sato H, Imagawa M, et al. (2003) Eye movements evoked by the selective stimulation of the utricular nerve in cats. *Auris Nasus Larynx* 30: 341-348.
7. Ikeda T, Hashimoto M, Horiike O, Yamashita Y (2002) Simple eye movement image analysis technique using NIH Image. *Equilibrium Res* 61: 90-96.
8. Curthoys IS (1987) Eye movements produced by utricular and saccular stimulation. *Aviat Space Environ Med* 58: 192-197.