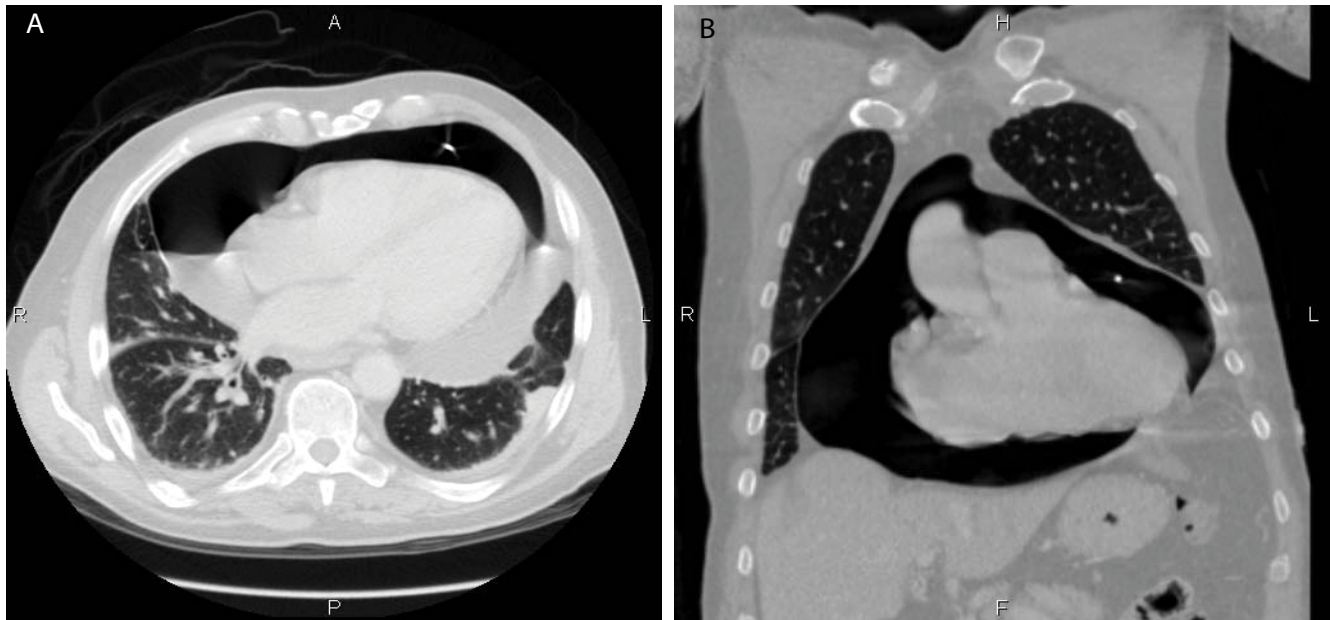




Image 1:019

Images of Iatrogenic Pneumopericardium



A 76-year-old man presenting with cardiac tamponade underwent urgent pericardial drainage using ultrasound guided pericardial puncture. A pericardial drainage catheter was left in place. The patient continued to present with symptoms suggestive of recurrent cardiac tamponade. Computed tomography (CT) of the chest in axial (Figure 1A) and coronal (Figure 1B) plans demonstrated a large pneumopericardium. In this particular case, the pericardial drainage catheter was malfunctioning due to a kink at its distal end. Air was entering the pericardium via the pericardial drainage catheter but could not drain out.

Information

Josephine Pressacco*

University of Montreal, Montreal, Quebec, Canada

*Correspondence: Josephine Pressacco, MD, PhD,
University of Montreal, 5400 Gouin Boulevard west
Montreal, Quebec H4J 1C5, Canada, Tel: 514-338-2222,
Fax: 514-338-3541, E-mail: pressacco@gmail.com

Citation: Pressacco J (2015) Images of Iatrogenic Pneumopericardium. Clin Med Img Lib 1:019

Published: December 11, 2015

Copyright: © 2015 Pressacco J. This is an open-access content distributed under the terms of the Creative Commons Attribution License, which permits unrestricted use, distribution, and reproduction in any medium, provided the original author and source are credited.