



Image 2:037

PET Molecular Imaging of the Dopaminergic System in Parkinson's Disease

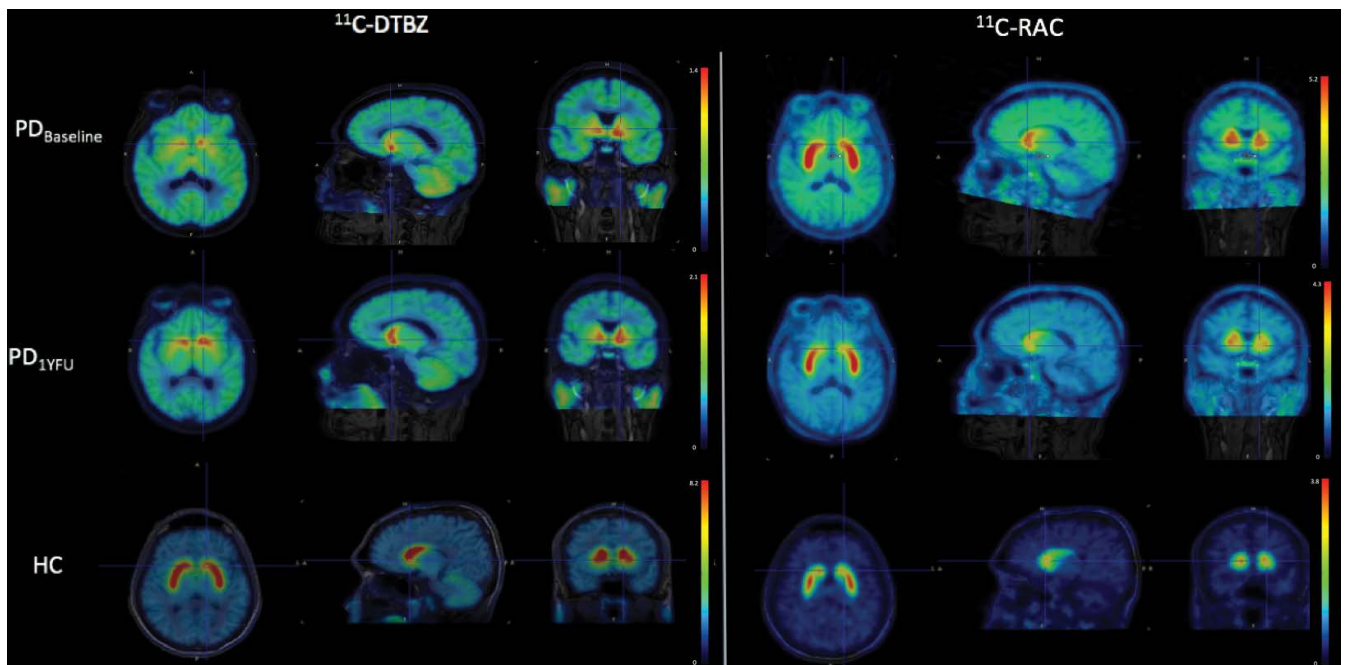


Figure 1: Axial, sagittal and coronal planes of PET/MRI images of a PD patient evaluated with DTBZ and RAC before and after stem cell implantation. A healthy control subject is included at the bottom row for comparison purposes.

Keywords

PET imaging, Dopaminergic system, Parkinson's disease

Introduction

It is well known that the dopaminergic system plays a major role in Parkinson's disease (PD). Current technological developments in molecular imaging have made it possible to evaluate the dopaminergic system in vivo, including alterations of dopamine synthesis, integrity of dopaminergic terminals, and receptor densities, invaluable information for understanding the mechanisms underlying the pathogenesis of PD and to evaluate efficacy of treatments [1]. Positron Emission Tomography (PET) provides these features, provided the availability

Information

**A Avendaño-Estrada¹, I Madrazo²,
O Kopyov³, H Carrasco-Vargas⁴, J
Altamirano-Ley¹ and MA Ávila-Rodríguez^{1*}**

¹Facultad de Medicina, Universidad Nacional Autónoma de México, Mexico

²Hospital Ángeles del Pedregal, Mexico

³Celavie Biosciences LLC, USA

⁴Hospital Central Militar, México

***Correspondence:** Miguel A. Ávila-Rodríguez, Unidad Radiofarmacia-Ciclotrón, División de Investigación Facultad de Medicina, UNAM, Torre de Investigación, P.B., Ciudad Universitaria, CDMX, C.P. 04510, Mexico, Tel: 525-5562-32288, E-mail: avilarod@uwalumni.com

Citation: Avendaño-Estrada A, Madrazo I, Kopyov O, Carrasco-Vargas H, Altamirano-Ley J, et al. (2016) PET Molecular Imaging of the Dopaminergic System in Parkinson's Disease. Clin Med Img Lib 2:037

Published: March 28, 2016

Copyright: © 2016 Avendaño-Estrada A, et al. This is an open-access content distributed under the terms of the Creative Commons Attribution License, which permits unrestricted use, distribution, and reproduction in any medium, provided the original author and source are credited.

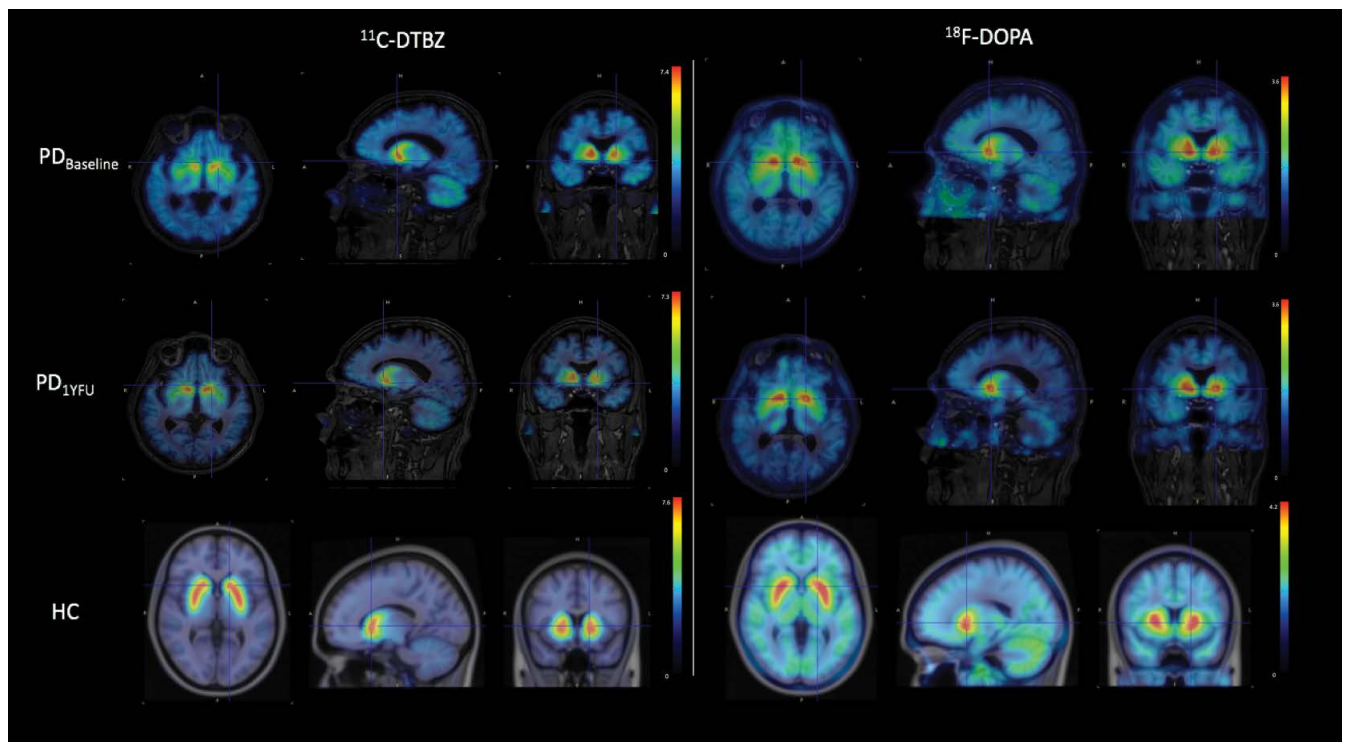


Figure 2: Axial, sagittal and coronal planes of PET/MRI images of a PD patient evaluated with DTBZ and FDOPA before and after stem cell implantation. A healthy control subject is included at the bottom row for comparison purposes.

of suitable tracers to investigate presynaptic and postsynaptic function [2,3]. Here we present two case reports to show the utility of the combined use of PET radiopharmaceuticals to evaluate PD and the efficacy of treatments to restore dopaminergic transmission.

Case 1

A 56-year-old right handed Hispanic female with a 10-year history of PD under L-dopa treatment, with a Unified Parkinson's Disease Rating Scale motor score (UPDRSms) of 43 and 24 under "OFF" and "ON" medication conditions, respectively. History of diabetes treated with metformin. She denies any family history of PD or any other neurodegenerative problems and does not drink alcohol orsmokes cigarettes. Patient underwent intraputaminaal transplantation of human fetal-derived stem cells (hfSC). **Figure 1** shows PET images (fused with MRI) in the baseline state (top row) and at one year after stem cell transplantation (middle row), obtained with two radiopharmaceuticals. For comparison purposes a healthy control (HC) subject is included in the bottom row. Radiopharmaceuticals utilized were (+)-alpha-[11C] Dihydrotrabenzazine (DTBZ) and [11C]Raclopride (RAC). DTBZ is a presynaptic radioligand with a high affinity to type-2 vesicular monoamine transporter (VMAT2) and is used as an in vivo marker of nigrostriatal dopaminergic system integrity. PD patients, compared to HCs, show a reduced uptake of DTBZ in the striatum, which is more prominent in the putamen [4,5]. RAC, on the other hand, is a postsynaptic radioligand. It is a dopamine D2 receptor antagonist and previous studies have shown that RAC binding to the postsynaptic D2 receptors is either normal or increased in PD patients, and the increase has been interpreted as a compensatory reaction to the reduction of striatal dopaminergic terminals [6]. Note the mismatch pattern of DTBZ and RAC uptake in the putamen of PD patients. Note also the increased uptake of DTBZ and decreased uptake of RAC at one year follow up (1YFU) compared with baseline studies, suggesting improvement of the disease after stem cell implantation.

Case 2

A 60-year-old right handed white male, with a 12- or 13-year history of PD under L-dopa treatment, with a UPDRSms of 28 and 11 under "OFF" and "ON" medication conditions, respectively. His past medical history is significant for irritable bowel syndrome. Patient denies any allergies and alcohol use. He used to smoke one cigarette per day. Patient underwent intraputaminaal transplantation of hfSC. **Figure 2** shows PET images (fused with MRI) in the baseline state (top row) and at one year after stem cell transplantation (middle row), obtained with two radiopharmaceuticals. For comparison purposes a HC subject is included in the bottom row. Radiopharmaceuticals utilized were DTBZ and 6-[18F]Fluoro-L-DOPA (FDOPA). FDOPA evaluates the first step in dopaminergic transmission, measuring the dopamine synthesis through the expression of aromatic amino-acid decarboxylase (AADC) in presynaptic neurons. It has been demonstrated that PD patients, compared to HC, show a significant reduction of striatal uptake, which is more severe in the putamen than in the caudate nucleus, and more prominent in the posterior putamen [7,8]. Note the match pattern of DTBZ and FDOPA uptake in the putamen of PD patients. In this case the uptake of both tracers before and after stem cell implantation is very similar, suggesting stable disease.

Acknowledgments

Research supported in part by Celavie Biosciences and UNAM-DGAPA-PAPIIT IT201115.

References

1. Cummings JL, Henchcliffe C, Schaefer S, Simuni T, Waxman A, et al. (2011) The role of dopaminergic imaging in patients with symptoms of dopaminergic system neurodegeneration. *Brain* 134: 3146-3166.
2. Sioka C, Fotopoulos A, Kyritsis AP (2010) Recent advances in PET imaging for evaluation of Parkinson's disease. *Eur J Nucl Med Mol Imaging* 37: 1594-1603.

-
3. Berti V, Pupi A, Mosconi L (2011) PET/CT in diagnosis of movement disorders. *Ann N Y Acad Sci* 1228: 93-108.
 4. Frey KA, Koeppe RA, Kilbourn MR, Vander Borghet TM, Albin RL, et al. (1996) Presynaptic monoaminergic vesicles in Parkinson's disease and normal aging. *Ann Neurol* 40: 873-884.
 5. Bohnen NI, Albin RL, Koeppe RA, Wernette KA, Kilbourn MR, et al. (2006) Positron emission tomography of monoaminergic vesicular binding in aging and Parkinson disease. *J Cereb Blood Flow Metab* 26: 1198-1212.
 6. Rinne UK, Laihinen A, Rinne JO, Någren K, Bergman J, et al. (1990) Positron emission tomography demonstrates dopamine D2 receptor supersensitivity in the striatum of patients with early Parkinson's disease. *MovDisord* 5: 55-59.
 7. Brooks DJ, Ibanez V, Sawle GV, Quinn N, Lees AJ, et al. (1990) Differing patterns of striatal 18F-dopa uptake in Parkinson's disease, multiple system atrophy, and progressive supranuclear palsy. *Ann Neurol* 28: 547-555.
 8. Brück A, Aalto S, Nurmi E, Vahlberg T, Bergman J, et al. (2006) Striatal subregional 6-[18F]fluoro-L-dopa uptake in early Parkinson's disease: a two-year follow-up study. *Mov Disord* 21: 958-963.