



## IMAGE ARTICLE

# Gastric Duplication Cyst as an Unusual Cause of Gastric Outlet Obstruction in an Adult

Shinil K Shah<sup>1,2\*</sup>, Sheilendra S Mehta<sup>1</sup> and Kulvinder S Bajwa<sup>1</sup>

<sup>1</sup>Department of Surgery, McGovern Medical School, University of Texas Health Science Center at Houston, Texas, USA

<sup>2</sup>Michael E. DeBakey Institute for Comparative Cardiovascular Science and Biomedical Devices, Texas A&M University, College Station, Texas, USA

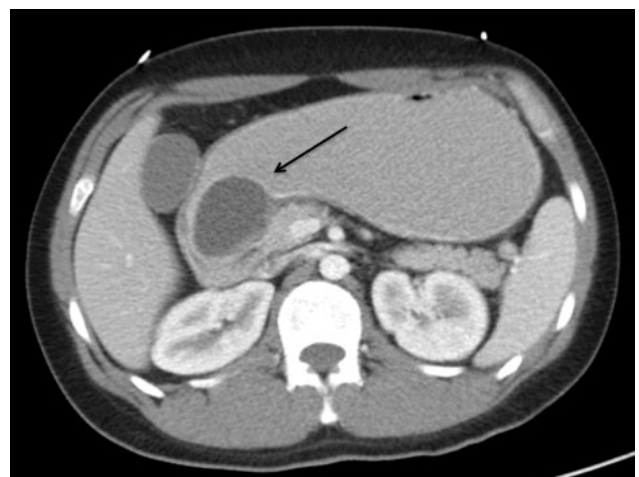
\*Corresponding author: Shinil K Shah, DO, Department of Surgery, McGovern Medical School, University of Texas Health Science Center at Houston, 6431 Fannin Street, MSB 4.156, Houston, TX 77030, Texas, USA, Tel: 713-500-7216, E-mail: [shinil.k.shah@uth.tmc.edu](mailto:shinil.k.shah@uth.tmc.edu)

### Keywords

Duplication cyst, Gastric outlet obstruction, Adult, Endoscopy, Robotic surgery, Laparoscopy

## Case Report

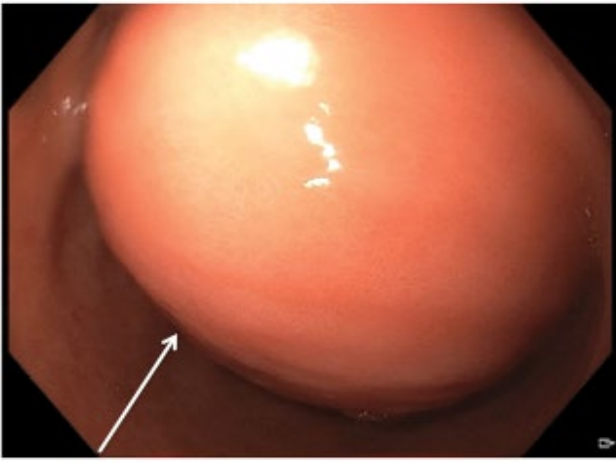
The patient is a 29-year-old man with no significant medical or surgical history who presented with 2 months of nausea, emesis, and 20 pounds of unintentional weight loss. On initial presentation, he was afebrile with normal vital signs. His abdomen was soft, non-distended and non-tender. Initial laboratory parameters revealed a hypokalemic, hypochloremic metabolic alkalosis consistent with a clinical picture of gastric outlet obstruction. Computed Tomography (CT) of the abdomen and pelvis (Figure 1) revealed a 3.5 × 4.9 cm cyst proximal to the pylorus, suggestive of a gastric duplication cyst, causing a gastric outlet obstruction. Endoscopy demonstrated a large pre-pyloric mass without noted mucosal abnormality or luminal connection, likely responsible for the gastric outlet obstruction (Figure 2). Antral biopsies revealed mild chronic inflammation and mild foveolar hyperplastic changes. Given gastric outlet obstruction as well as imaging suggestive of a duplication cyst, the patient was taken to the operating room and underwent robotic assisted laparoscopic distal gastrectomy with Billroth 2 gastrojejunostomy for a suspected gastric duplication cyst (Figure 3). Final pathology revealed features consistent with a gastric duplication cyst (5.2 × 4.0 × 4.0 cm) not communicating with the gastric lumen (Figure 4).



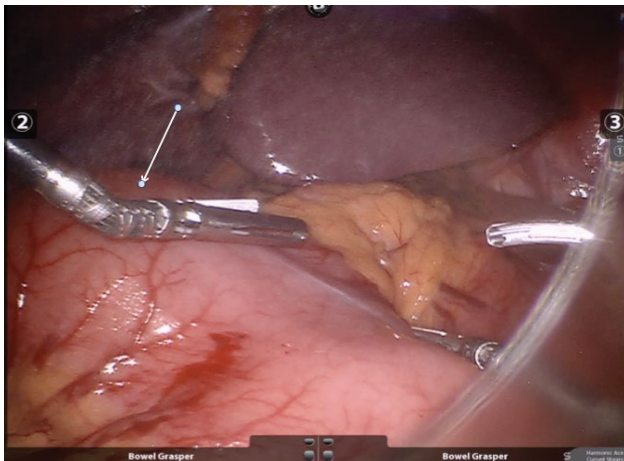
**Figure 1:** Computed Tomography (CT) of the abdomen/pelvis demonstrates a 3.5 × 4.9 cm cyst in the pre-pyloric antral area (arrow) with associated gastric dilation suggestive of gastric outlet obstruction.

## Discussion

Gastric duplication cysts, rarely diagnosed in adults, and often discovered incidentally on imaging, were first reported in 1911 [1]. They are congenital abnormalities, and account for 2-4% of gastrointestinal tract duplication cysts [2]. They may present with non-spe-

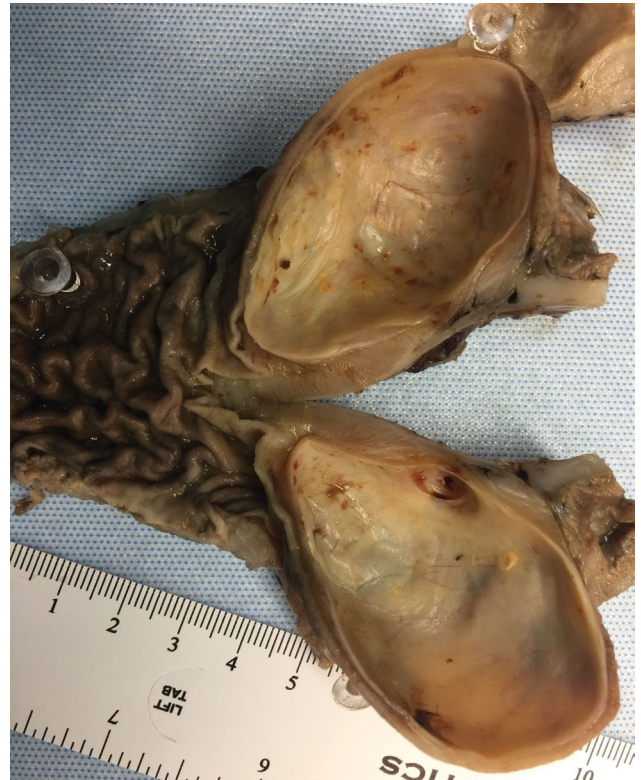

**Figure 2:** Endoscopy revealed a submucosal mass without luminal communication (arrow) corresponding to the lesion noted on imaging.



**Figure 3:** Intraoperative photograph demonstrating the external appearance of the gastric duplication cyst (arrow).

cific symptoms including pain, nausea, vomiting, and weight loss. CT, magnetic resonance imaging, and Endoscopic Ultrasound (EUS) may assist in the diagnosis. EUS guided biopsy may help when other diagnoses, such as gastrointestinal stromal tumors, are suspected. In the stomach, most duplication cysts arise along the greater curvature; they are rarely reported in the antrum or pre-pyloric region. Malignant degeneration is rare [3,4].



**Figure 4:** Surgical pathology revealed features consistent with a gastric duplication cyst (5.2 × 4.0 × 4.0 cm) not communicating with the gastric lumen.

Treatment of gastric duplication cysts involves complete cyst resection and typically achieved with laparoscopic or open methods.

## References

1. Kim SM, Ha MH, Seo JE, Kim JE, Min BH, et al. (2015) Gastric duplication cysts in adults: a report of three cases. *J Gastric Cancer* 15: 58-63.
2. Deesomsak M, Aswakul P, Junyangdikul P, Prachayakul V (2013) Rare adult gastric duplication cyst mimicking a gastrointestinal stromal tumor. *World J Gastroenterol* 19: 8445-8448.
3. Namdaroglu OB, Argon A, Aydogan S, Ozturk AM, Yakan S, et al. (2017) Gastric duplication cyst in adult: Challenge for surgeons. *J Minim Access Surg* 13: 57-59.
4. Gupta S, Sleeman D, Alsumait B, Abrams L (1998) Duplication cyst of the antrum: a case report. *Can J Surg* 41: 248-250.