



IMAGE ARTICLE

A Rare Case Report: Urothelial Carcinoma Arising from a Bladder Diverticulum

Hasan Erdogan, Serdar Arslan*, Fatih Oncu, Nahide Baran, Fatma Zeynep Arslan and Mehmet Sedat Durmaz

Department of Radiology, Konya Education and Research Hospital, University of Health Sciences, Konya, Turkey



*Corresponding author: Serdar Arslan, MD, Specialist, Department of Radiology, Konya Education and Research Hospital, University of Health Sciences, 42090, Meram, Konya, Turkey, Tel: +90-555-866-0621, E-mail: arslanserdar10@gmail.com

Keywords

Urothelial carcinoma, Bladder, Diverticulum, US, CT

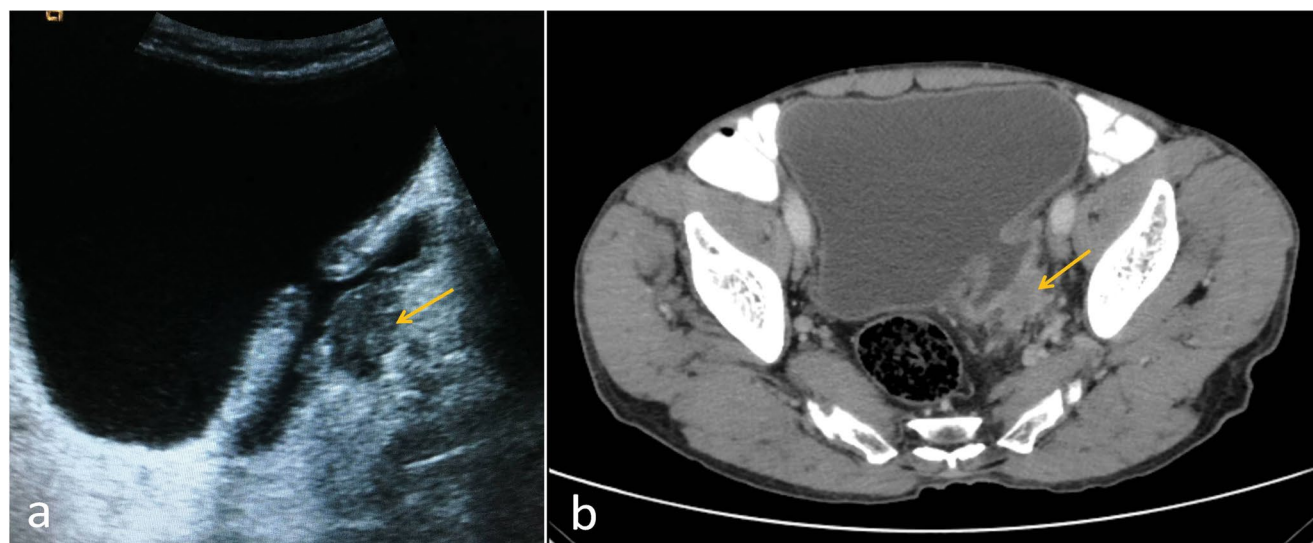


Figure 1: Contrast-enhanced abdominal computed tomography demonstrates a bladder diverticulum protruding from the left posterior lateral wall with irregular wall thickening in the diverticulum.

A 73-year-old man was admitted our hospital with gross hematuria. Abdominal ultrasonography (US) and computed tomography (CT) revealed a bladder diverticulum with a irregular wall thickening that was concerning for tumor (Figure 1). Subsequent cystoscopy and transurethral resection of bladder tumor revealed urothelial carcinoma. Cystoprostatectomy was performed and revealed invasive urothelial carcinoma in the diverticulum

extending through the diverticular wall and into peridiverticular adipose tissue.

Bladder diverticulum is mucosal outpouching of bladder without a muscle layer. The lack of a muscle layer in bladder diverticulum results in a loss of contractility, which results in urine stasis in the diverticulum. Chronic irritation of intradiverticular urine may cause

chronic inflammation or infection or malignant neoplastic change [1]. Neoplasms in the bladder diverticulum are rare with an incidence of 2% to 7% [2]. Urothelial carcinoma and squamous cell carcinoma are the most frequently encountered histological types [3]. Most bladder diverticula are asymptomatic. The main clinical presentation is painless gross hematuria for diverticular tumor. It is important to make an early diagnosis of the bladder tumor arising within a bladder diverticulum but it is difficult in asymptomatic period [3,4]. Treatment options include diverticulectomy, partial cystectomy or radical cystectomy [4]. Radiologists should keep in mind the risk of developing tumors in the bladder diverticulum. When a bladder diverticulum is seen, the wall of the diverticulum should be carefully evaluated in terms of the tumor.

Source(s) of Support

None.

Conflicting Interest

None.

References

1. Chen HE, Lin YC, Cheng YH (2016) Urothelial carcinoma arising within bladder diverticulum-Report of a case and review of the literature. *Urological Science* 27: 177-180.
2. Shah B, Rodriguez R, Krasnokutsky S, Shah SM, Ali Khan S (1997) Tumour in a giant bladder diverticulum: A case report and review of literature. *Int Urol Nephrol* 29: 173-179.
3. Dondalski M, White EM, Ghahremani GG, Patel SK (1993) Carcinoma arising in urinary bladder diverticula: Imaging findings in six patients. *AJR Am J Roentgenol* 161: 817-820.
4. Golijanin D, Yossepowitch O, Beck SD, Sogani P, Dalbagni G (2003) Carcinoma in a bladder diverticulum: Presentation and treatment outcome. *J Urol* 170: 1761-1764.