



## IMAGE ARTICLE

# Rare Case of Lung Adenocarcinoma Invading the Inferior Vena Cava with Neoplastic Thrombus Extending into the Right Atrium

Miriam Patella, Francesco Proietti\*, Francesco Mongelli and Stefano Cafarotti

Department of Thoracic Surgery, San Giovanni Hospital, Bellinzona, Switzerland



\*Corresponding author: Francesco Proietti, Department of Thoracic Surgery, San Giovanni Hospital, Bellinzona, Switzerland, Tel: +41-(0)918118218, Fax: +41-(0)918119173

### Keywords

Lung cancer, Inferior vena cava thrombosis, Right atrium thrombosis

A 40-years-old patient with M1a lung adenocarcinoma. CT scan showed a mass directly invading the inferior vena cava (IVC) with neoplastic thrombus in the right atrium (Figure 1A and Figure 1B). Echocardiogram confirmed solid mass floating in the right atrium, connected with tumour invading the IVC (Figure 1C).

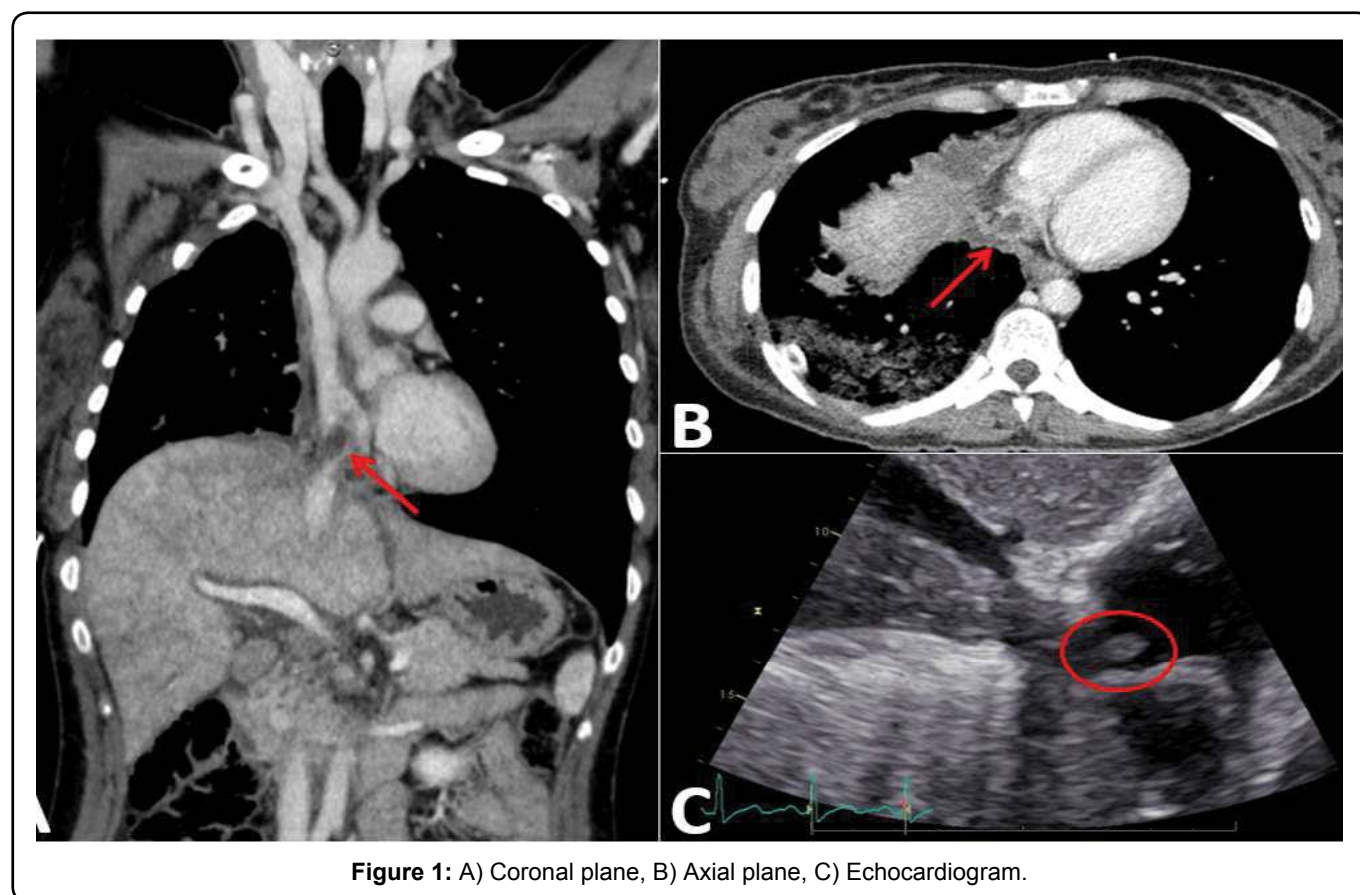


Figure 1: A) Coronal plane, B) Axial plane, C) Echocardiogram.