



IMAGES IN SURGERY

Teleconsultation in COVID Era can be Unwholesome at Times

Bhushan Bhalgat*, Suresh Singh, Pravin Kumar, Phanindra Kumar Swain, Kamal Kishore Lakhera and Raj Govind Sharma

Department of Surgical Oncology, SMS Medical College and Hospital, Jaipur, India

*Corresponding author: Bhushan Sanjay Bhalgat, Department of Surgical Oncology, SMS Medical College and Hospital, Jaipur, India



Image Description

COVID-19 pandemic has led to a vast increase in the number of teleconsultations. These images alongside are a perfect example of misinterpreted diagnosis due to unwanted importance to radiological investigations without performing a proper clinical examination. The X-ray chest PA view (see [Figure 1](#)) was advised by family

physician of the patient on a well-known multiplatform messaging app when the patient complained of “chhati mai gaath hai” (translated to English: “swelling in the chest”). After seeing the X-ray on the same messaging app, the doctor further advised a computed tomography scan of the chest (see [Figure 2](#)); still unaware of the plane of the swelling. The patient, having trust in his family

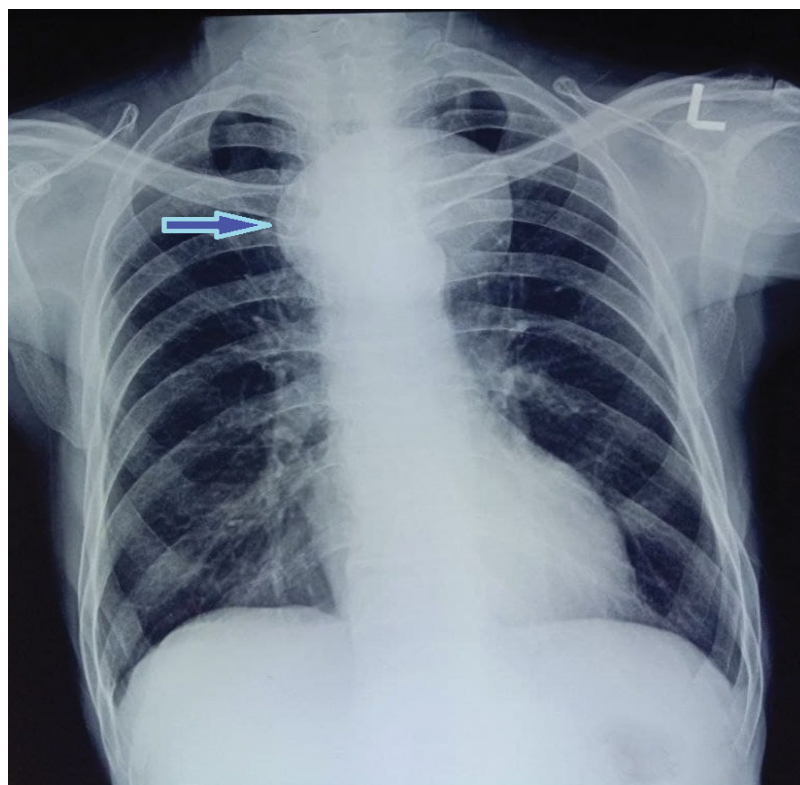


Figure 1: The X-ray chest PA view.

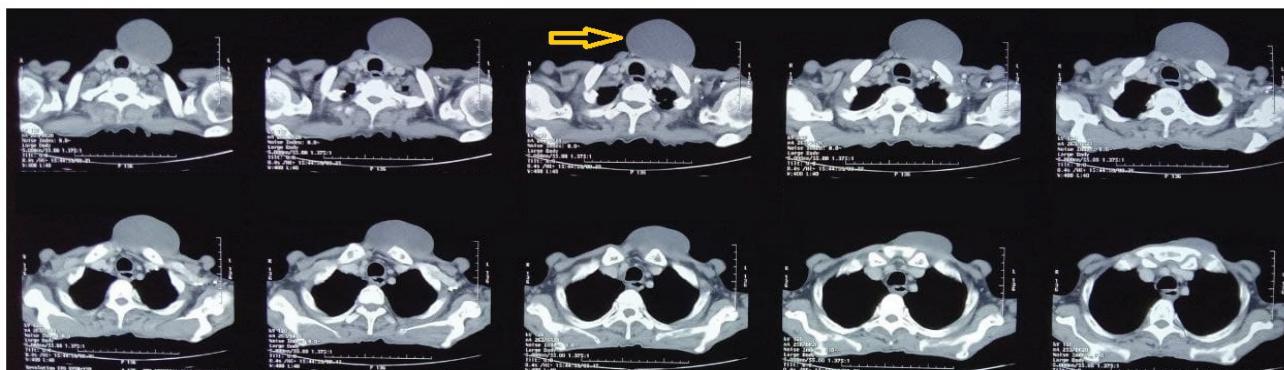


Figure 2: Computed tomography scan of the chest.

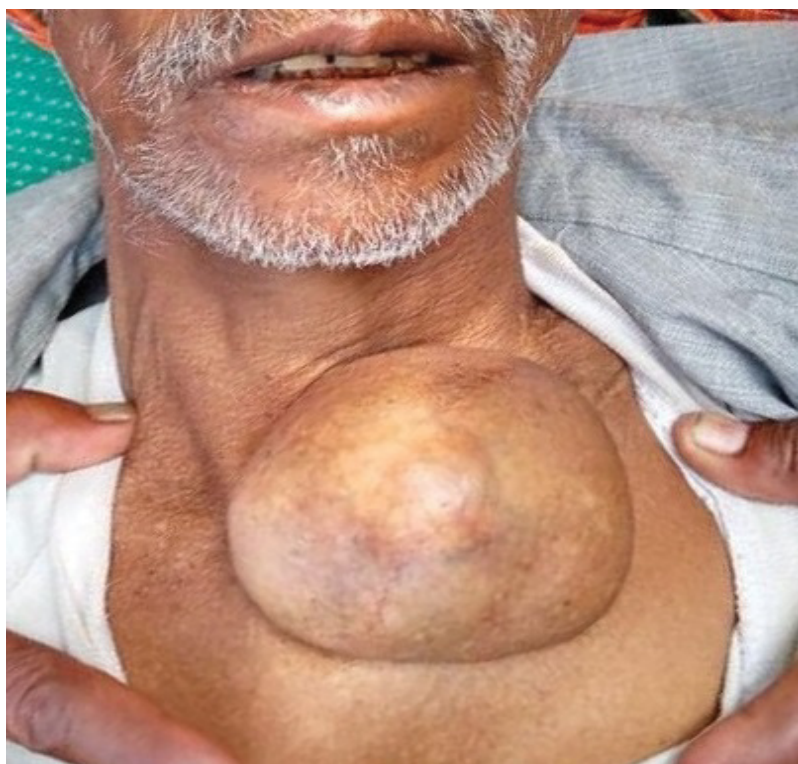

Figure 3: Swelling in the chest.

physician, underwent the unnecessary investigation. On viewing the CT scan films, the physician referred the patient to our higher center for excision.

Had the family physician examined the patient during the first consultation itself, (at least by inspection!); the patient would not have required to go through the extra investigation (see [Figure 3](#)).

Conflict of Interest

None.

Ethical Committee Approval

Not required.