



## CLINICAL IMAGE

# Vocal Cord Edema Leading to Complete Airway Obstruction in a Case of Traumatic Difficult Airway

Koninica Sanyal<sup>1</sup> and Abhishek Singh<sup>2\*</sup>

<sup>1</sup>Senior Resident, Department of Anesthesiology, Pain Medicine and Critical Care, All India Institute of Medical Sciences, India

<sup>2</sup>Assistant Professor, Department of Anesthesiology, Pain Medicine and Critical Care, All India Institute of Medical Sciences, India

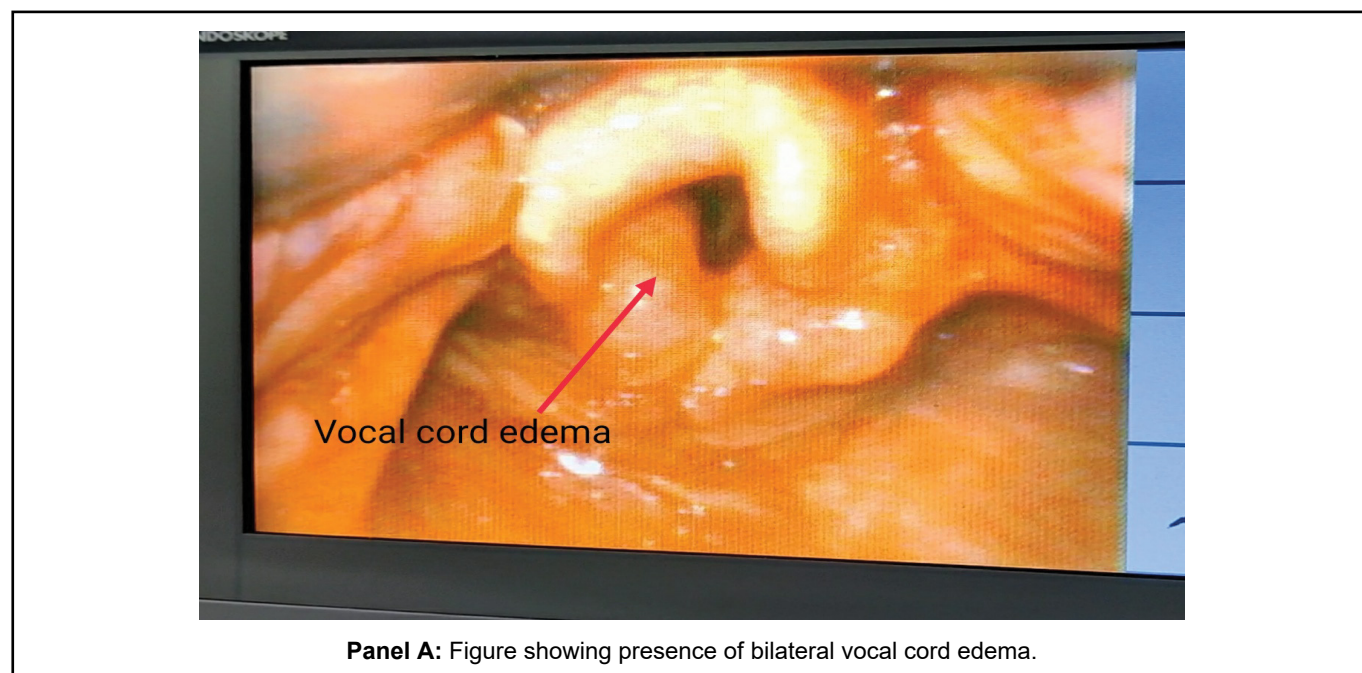
\*Corresponding author: Abhishek Singh, Assistant Professor, Department of Anesthesiology, Pain Medicine and Critical Care, All India Institute of Medical Sciences, India



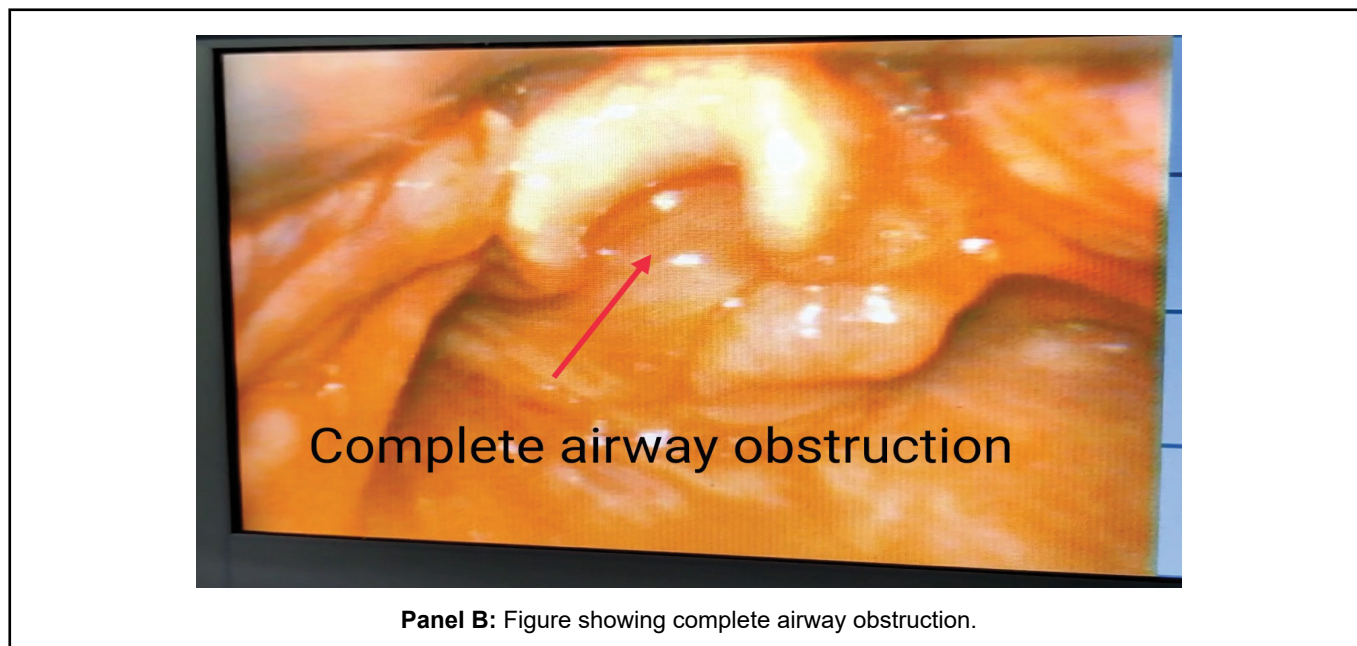
## Case Description

A 31-year-old male had presented to the emergency department after road traffic accident. Primary investigation revealed presence of right clavicle fracture, bilateral LeFort 2 and 3 fractures along with displaced mandible. He was intubated in view of poor GCS and threatened airway. After 2 days of mechanical ventilation, he was extubated and posted for open reduction and internal fixation for LeFort 2 and 3

fractures. Airway examination revealed presence of reduced mouth opening. After induction of patient with fentanyl and Propofol, there was difficulty in bag and mask ventilation. Considering it to be due to tongue fall, oropharyngeal airway was inserted but it failed to improve the ventilation. Now, patient started showing signs of suprasternal retraction and labored breathing. Check laryngoscopy was done with C-MAC video laryngoscope which showed presence of vocal cord edema (Panel A) with reduced glottic aperture which



Panel A: Figure showing presence of bilateral vocal cord edema.



converted into partial to complete obstruction with each breath ([Panel B](#) and [Video 1](#)). While maintaining spontaneous respiration, CPAP of 5 cmH<sub>2</sub>O was added and patient was monitored till he was completely awake.

The patient was shifted to intensive care unit for monitoring and was asked to be posted for elective surgery after clearance of vocal cord edema. To conclude, when faced with similar situations, clinicians should maintain a high level of suspicion even in absence of frank signs of impending airway obstruction.