



Right Sided Approach for a Pacemaker Insertion in the presence of Persistent Left Sided Superior Vena Cava: A Pacing Challenge

Edupuganti Mohan Mallikarjuna Rao*, Hakan Paydak and Jawahar Mehta

University of Arkansas for Medical Sciences, USA

*Corresponding author: Edupuganti Mohan Mallikarjuna Rao, University of Arkansas for Medical Sciences, Little Rock, Arkansas, USA, Tel: 2053812026; E-mail: mmedupuganti@gmail.com

Abstract

Persistent Left sided superior vena cava is a rare congenital anomaly that can complicate a variety of cardiac procedures. We present a patient where a persistent superior vena cava was encountered unexpectedly during routine pacemaker insertion. The condition was diagnosed on the table and greatly lengthened the operating time. Given the situation and an absence of a pre procedure diagnosis the surgeon had to be innovative and invent approaches to navigate the complex anatomy on the spot. Fortunately the procedure was able to be completed without complications. We illustrate how this anomaly was diagnosed on the operating table, describe the approach that were employed and review the literature on the topic and summarize the steps that can be employed in this situation.

Keywords

Persistent left sided superior vena cava, Pacemaker insertion, Venogram

disease. He was taking a combination of aspirin, simvastatin, hydrochlorothiazide and glimepiride. Examination revealed a well built and nourished elderly male with normal arterial and venous pulses and heart sounds. Laboratory examination was unremarkable. An EKG showed a normal sinus rhythm with complete heart block and a ventricular escape rhythm. Echocardiogram revealed a normal LV function without regional wall motion abnormalities.

A persistent left sided vena cava was discovered intraoperatively during an unsuccessful attempt at a pacemaker implantation at an outside facility and he was referred to University of Arkansas for Medical Sciences UAMS. A right sided approach was undertaken. During the procedure there were difficulty advancing the leads which took an abnormal course to the left heart border. An intraoperative venogram showed an absent right sided superior vena cava and the right brachiocephalic vein draining into the persistent left superior vena cava (Figure 1). A left sided approach was considered but was not

Introduction

A persistent left sided superior vena cava is an uncommon congenital anomaly that can occur either alone or in association with other congenital anomalies. The prognosis depends on the associated congenital anomalies. Normally the right subclavian vein and the right internal jugular vein form the right innominate or brachiocephalic vein. The left subclavian vein and the left internal jugular vein drain into the left brachiocephalic vein or left innominate vein, both the innominate veins join together to form the right superior vena cava. Typically a left sided SVC is present alongside a small right sided SVC and there is no left sided brachiocephalic vein, the left sided SVC drains directly into the coronary sinus. It is very rare to encounter a persistent left sided superior vena cava with an absent right sided vena cava.

Case Presentation

A 71 y/o Caucasian male was referred to the University of Arkansas for Medical Sciences (UAMS) for consideration for a permanent pacemaker dual chamber pacemaker insertion in view of a symptomatic high grade AV block. The past medical history was significant for hypertension, diabetes, dyslipidemia and kidney

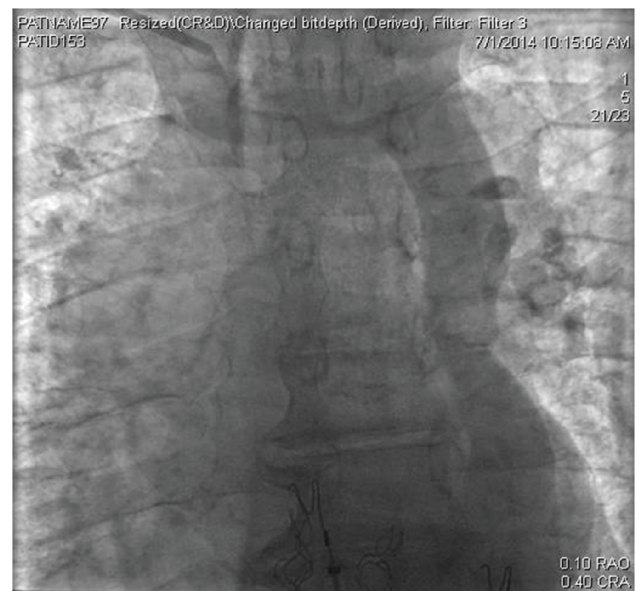


Figure 1: Venogram showing a catheter in the right subclavian vein and a persistent left sided superior vena cava

Citation: Rao EMM, Paydak H, Mehta J (2015) Right Sided Approach for a Pacemaker Insertion in the presence of Persistent Left Sided Superior Vena Cava: A Pacing Challenge. Clin Med Rev Case Rep 2:031. doi.org/10.23937/2378-3656/1410031

Received: April 24, 2015; **Accepted:** May 22, 2015; **Published:** May 25, 2015

Copyright: © 2015 Rao EMM. This is an open-access article distributed under the terms of the Creative Commons Attribution License, which permits unrestricted use, distribution, and reproduction in any medium, provided the original author and source are credited.

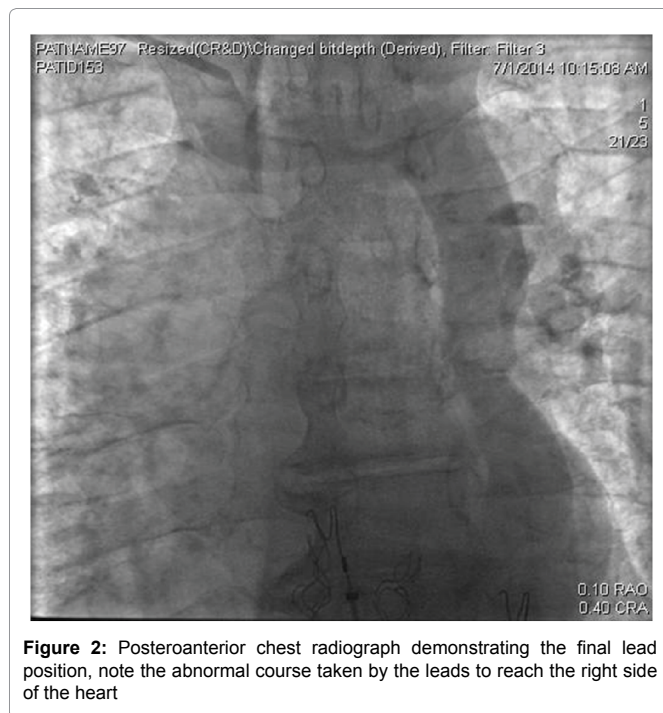


Figure 2: Posteroanterior chest radiograph demonstrating the final lead position, note the abnormal course taken by the leads to reach the right side of the heart

Table 1: Anomalies of the vena cava

Anomalies of the vena cava [9]

- Left SVC and its tributaries drain into the coronary sinus
- Left superior vena cava draining into the left atrium through an unroofed coronary sinus
- The left superior vena cava draining into the left coronary sinus and draining into the right internal jugular vein by means of an innominate vein
- Persistent left superior vena cava with an absent right sided vena cava.

Anomalies of the right superior vena cava [10]

- Drainage into left atrium
- Low right atrial insertion
- Aneurysmal dilatation
- Anomalous left brachiocephalic vein draining into right superior vena cava.

Table 2: Other congenital heart defects

Congenital Heart defects	Other defects
a. Atrial septal defect	a. Absent right SVC
b. Ventricular septal defect	b. Situs inversus
c. Pulmonary stenosis /atresia	c. Coronary sinus atresia / enlargement
d. D Transposition	d. Williams syndrome
e. Anomalous pulmonary venous drainage	
f. Mitral atresia	
g. Tetralogy of fallot	
h. Coarctation of aorta	

tried to minimize the risk for infection due to the recent procedure on the left side. An extended hook coronary sinus guiding catheter was used and with the help of a glide wire, entrance was made into the right ventricular apex. A Medtronic pace sense bipolar lead was then inserted through the guide catheter into the right ventricular apex under fluoroscopy. The following number were obtained RV sensing - 7mV, impedance- 675ohms and pacing threshold -1.0 volt at 0.5msec. A long Medtronic right atrial lead was inserted into the right atrial appendage under fluoroscopy without difficulty. P wave sensing was 3mV, impedance was 565 ohms and patient threshold was 1.0 volt at 0.5msec.

Discussion

Persistent left sided superior vena cava is a rare congenital anomaly, and is a part of the spectrum of anomalies of the development of the great veins [1-3]. Its prevalence is estimated to be 0.3% in the general population and 4.4% in patients with congenital heart disease [4]. Persistent left SVC with an absent right SVC is even more uncommon and occurs in 0.07-0.13% of patients with congenital heart disease and viscera atrial situs solitus [5]. The condition is usually benign unless it is accompanied by other congenital developmental abnormalities.

The situation usually poses a problem during procedures such as pacemaker insertion [6-8], insertion of jugular venous lines or cardiothoracic surgery such as heart transplant. Other anomalies [9,10] and associated congenital heart defects [11] are mentioned in Tables 1 and 2 respectively.

Clues to the possibility of an abnormal venous drainage include a posteroanterior chest X-ray showing a widening of the aortic shadow, a paramediastinal bulging, para mediastinal stripe or a low density line along the upper left margin of the heart [11]. The presence of a large coronary sinus on echo, relative ease with which a coronary sinus catheter can be passed into the OS of the coronary sinus during an EP study and an abnormal course of the catheter are some other clues. When a left subclavian approach is used the catheter can be seen coursing parallel to the left side of the spine before it enters the coronary sinus [12]. A diagnosis can usually be established with imaging techniques such as a contrast echocardiogram, CT venogram and MRI. The diagnosis can be confirmed with a bubble study, when agitated saline is injected into a left arm vein the bubbles can be seen to enter the coronary sinus before opacifying the right atrium [11].

A persistent left sided superior vena cava offers unique challenges to the implantation of a permanent pacemaker from a left sided approach; it becomes even more difficult when the procedure is approached from the right side in view of the many acute angle bends encountered on the way [9]. Inserting the atrial lead into the right atrium is usually not difficult. Once in the right atrium the straight stylet can be exchanged for a curved J tip stylet and a clockwise torque can be applied to deliver the lead into the anteriorly positioned right atrial appendage. The OS of the coronary sinus is directed in such a manner that the lead entering the right atrium is directed at the lateral free wall rather than the inlet of the right ventricle making the insertion of the lead into the right ventricle challenging. The ventricular lead can be advanced to the free wall of the right atrium and reflected off of it and looped in the right atrium to enter the inlet of the right ventricle. Other methods include adding a curve to the RV stylet and using a long curved venous access sheath such as the one used for cannulating the OS of the coronary sinus. We used an extended hook coronary sinus guiding catheter and entered the right ventricular apex with ease with a glide wire.

Conclusion

Persistent Left sided superior vena cava is a rare congenital anomaly and can be encountered unexpectedly during minimally invasive procedures. When the leads take an unexpected course during a procedure the operator is often concerned about a procedural complication such as perforation. However knowledge of this condition can minimize anxiety and enable the surgeon to use novel approaches to successfully perform the procedure and avoid surgery.

References

- Tak T, Crouch E, Drake GB (2002) Persistent left superior vena cava: incidence, significance and clinical correlates. *Int J Cardiol* 82: 91-93.
- Schreve-Steensma AM, van der Valk PH, Ten Kate JB, Kofflard MJ (2008) Discovery of a persistent left superior vena cava during pacemaker implantation. *Neth Heart J* 16: 272-274.
- Kilickap M, Altin T, Akyurek O, Karaoguz R, Akgun G, et al. (2005) DDD pacemaker implantation in a patient with persistent left superior vena cava and absent right superior vena cava: a four-year follow-up report. *Can J Cardiol* 21: 1221-1223.
- Biffi M, Boriani G, Frabetti L, Bronzetti G, Branzi A (2001) Left superior vena cava persistence in patients undergoing pacemaker or cardioverter-defibrillator implantation: a 10-year experience. *Chest* 120: 139-144.
- Uaar O, Paayaoaylu L, Ciaekaoaylu H, Vural M, Kocaoaylu I, et al. (2010) Persistent left superior vena cava with absent right superior vena cava: a case report and review of the literature. *Cardiovasc J Afr* 21: 164-166.
- Lappegard KT, Prytz JF, Haug B (2004) Pacemaker implantation in patients with persistent left superior vena cava. *Heart Vessels* 19: 153-154.
- Cardozo Zepeda CM, Guyomar Y, Heuls S, Graux P (2005) Implantation of a pacemaker through persistent left superior vena cava. *Arch Cardiol Mex* 75: 316-319.

8. Corbisiero R, DeVita M, Dennis C (2003) Pacemaker implantation in a patient with persistent left superior vena cava and absent right superior vena cava. *J Interv Card Electrophysiol* 9: 35-37.
9. Rizkallah J, Burgess J, Kuriachan V (2014) Absent right and persistent left superior vena cava: troubleshooting during a challenging pacemaker implant: a case report. *BMC Res Notes* 7: 462.
10. Bhatti S, Hakeem A, Ahmad U, Malik M, Kosolcharoen P, et al. (2007) Persistent left superior vena cava (PLSVC) with anomalous left hepatic vein drainage into the right atrium: role of imaging and clinical relevance. *Vasc Med* 12: 319-324.
11. Innasimuthu AL, Rao GK, Wsong P (2007) Persistent left-sided superior vena cava--a pacing challenge. *Acute Card Care* 9: 252.