



## CASE REPORT

# Kounis Syndrome: A Form of Acute Coronary Syndrome of Unusual Aetiology

Fulvio Cacciapuoti<sup>1</sup>, Valerio Langella<sup>2</sup>, Paolo Tirelli<sup>2</sup> and Federico Cacciapuoti<sup>3\*</sup>

<sup>1</sup>Department of Emergency, "A. Cardarelli" Hospital, Italy

<sup>2</sup>Department of Internal Medicine, "S. Maria di Loreto Mare" Hospital, Italy

<sup>3</sup>Department of Internal Medicine, "L. Vanvitelli" University, Naples, Italy

\*Corresponding author: Federico Cacciapuoti, MD, PhD, Department of Internal Medicine, "L. Vanvitelli" University, Piazza L Miraglia, 2, 80138, Naples, Italy, E-mail: [fulviocacciapuoti@gmail.com](mailto:fulviocacciapuoti@gmail.com)



### Abstract

Anaphylactic reaction rarely manifests such as acute coronary syndrome induced by coronary vasospasm or atheromatous plaque rupture due to some chemical mediators, such as histamine, platelet activating factors, cytokines and others, derived from mast cells degranulation. This condition was called as Kounis Syndrome (KS) first described by Kounis and Zavras in 1991 and was referred to an "allergic angina". We report a case of KS found in a 28-year-old woman with the subjective and electrocardiographic findings of NSTEMI, but negative coronary angiography which resolved after adequate anti-allergic treatment.

### Keywords

Acute coronary syndrome (STEMI/NSTEMI), Anaphylaxis, Coronary angiography

(pure vasospasm);

- Subtype II occurring in S-T elevation in the presence of coronary artery disease;
- Subtype III (the most dangerous variant), which occurs in patients with stent thrombosis, induced by reactions with chemical allergens. Herein, we present a case of KS.

### Case Report

A 28-years-old woman was treated with i.m. injection of phloroglucinol for acute abdominal pain. A few minutes after administration of the drug, the patient had sudden chest discomfort and pain in the left arm, shortness of breath, sweating and palpitations, generalized erythema and cutaneous rashes that justified admission to Emergency Room. On physical examination, arterial blood pressure was 95/70 mmHg and pulse rate was 105 beats/min. Cardiovascular auscultation demonstrated no additional heart sounds. A clean reduction of arterial oxygen saturation was present. Blood tests revealed troponin I value of 2.5 ng/ml. White cell count was  $15.51 \times 10^9/l$ ; C-reactive protein was 168 mg/dl. 12-leads ECG evidenced sinus rhythm and S-T depression (2 mm) in leads II, III, aVF (Figure 1). Treatment for anaphylaxis was started, with intravenous administration of hydrocortisone, diphenhydramine and bronchodilators, followed by improvement in cutaneous rashes, dyspnea, erythema and chest discomfort. 2D echocardiography did not reveal any valvular disease or contractility disorders, Simpson's %EF also was within normal limits. Normal ejection fraction, along with absence of wall

### Introduction

Kounis Syndrome (KS) has been defined as an acute coronary syndrome with or without the presence of underlying coronary artery disease, showing as unstable vasospastic/non-vasospastic angina or acute myocardial infarction. It is triggered by mediators released from mast cells and activated from allergic, hypersensitivity, or anaphylactoid reactions [1]. The mechanism of KS involves release of inflammatory cytokines through mast cell activation, which leads to coronary vasospasm and/or plaque erosion or rupture [2].

Three subtypes of KS were described [3]:

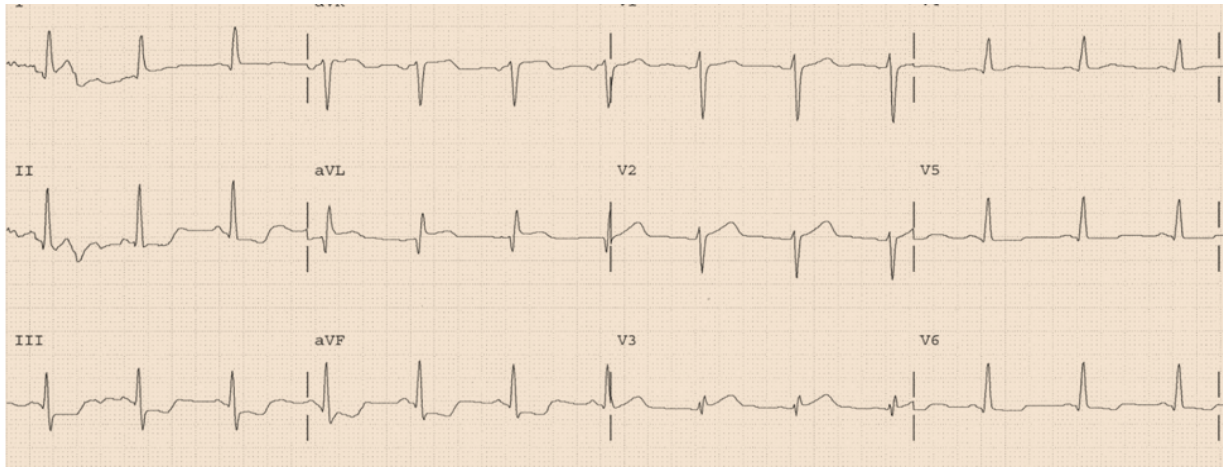
- Subtype I, which includes an S-T elevation myocardial infarction without underlying coronary disease



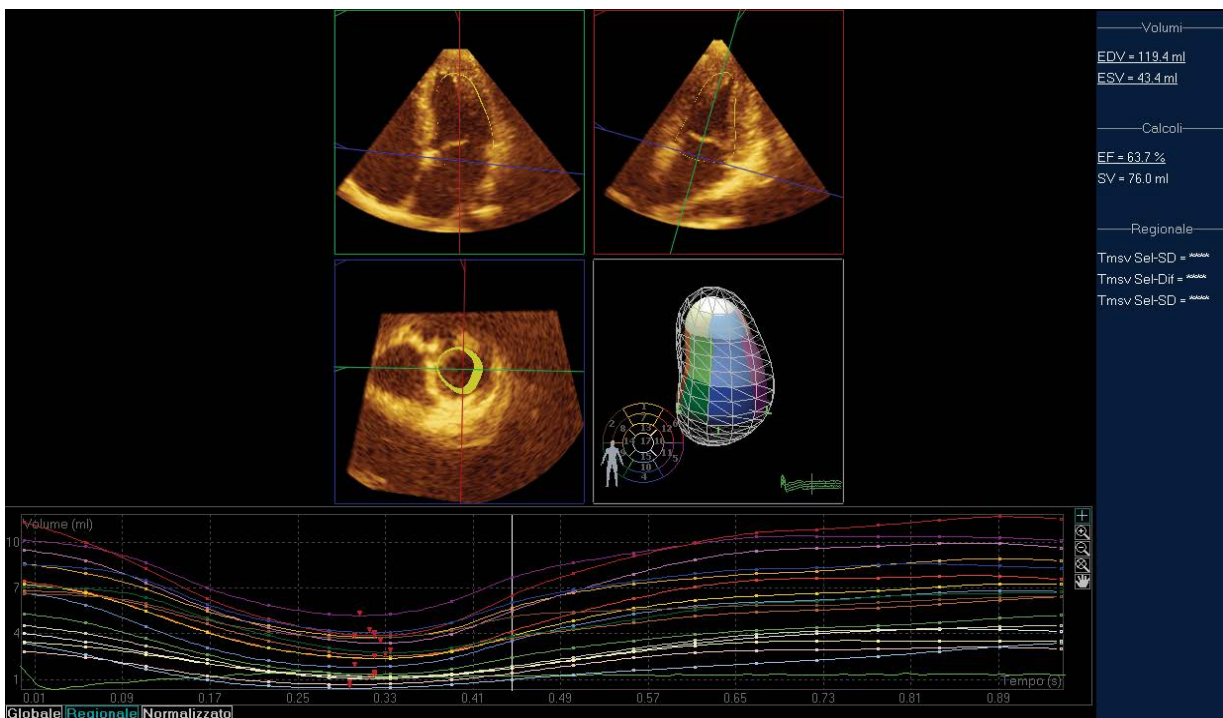
**Citation:** Cacciapuoti F, Langella V, Tirelli P, Cacciapuoti F (2017) Kounis Syndrome: A Form of Acute Coronary Syndrome of Unusual Aetiology. Int Arch Cardiovasc Dis 1:001.

**Received:** August 10, 2017; **Accepted:** September 23, 2017; **Published:** September 25, 2017

**Copyright:** © 2017 Cacciapuoti F, et al. This is an open-access article distributed under the terms of the Creative Commons Attribution License, which permits unrestricted use, distribution, and reproduction in any medium, provided the original author and source are credited.



**Figure 1:** ECG-12 leads-Depression of S-T segment (2 mm) in DI, DIII, aVF.



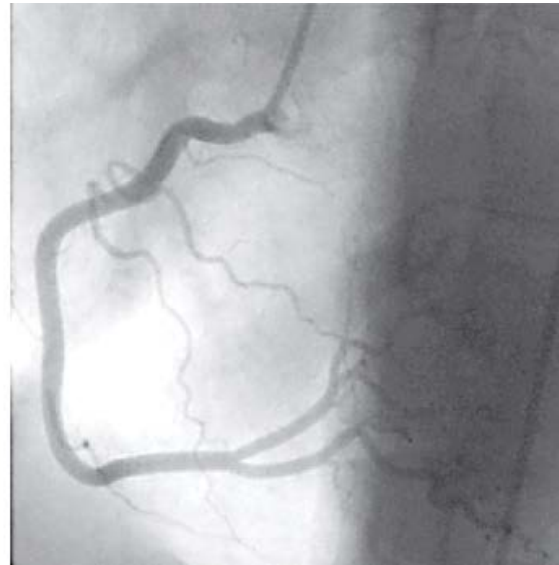
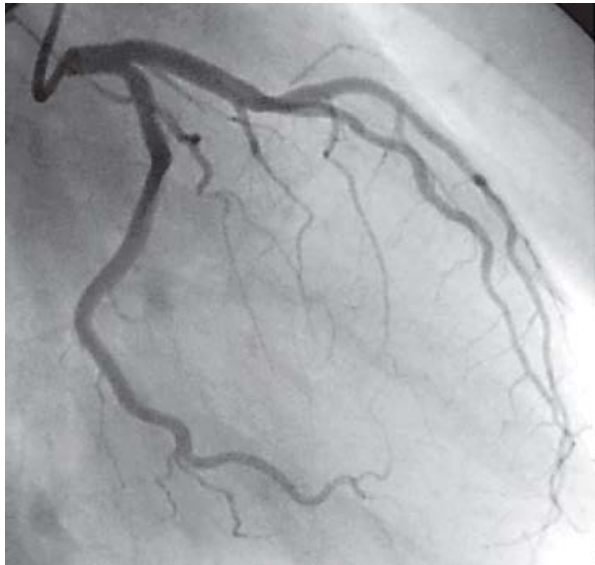
**Figure 2:** Three-dimensional echocardiography of Left Ventricle (LV). EDV (End Diastolic Volume): 119.4 ml; ESV (End Systolic Volume): 43.4 ml; EF (Ejection Fraction): 63.7%; SV (Stroke Volume): 76.0 ml. The silhouette of LV in systole and diastole is also recorded. Uniform motility of LV fibers (below).

motion abnormalities or contractile dysfunction was confirmed via 3D transthoracic echocardiography (Figure 2). Afterwards, the patient was transferred to the Coronary Intensive Care Unit due to a diagnosis of acute coronary syndrome and subsequently received 300 mg of ASA, 300 mg of clopidogrel and atorvastatin 40 mg PO. At the pre-angiographic treatment, 5000 IU heparin was given intravenously. Next, the patient underwent cardiac catheterization for coronary angiography. The procedure revealed no significant stenosis in the left anterior descending artery and its branches, circumflex artery or right coronary artery (Figure 3). On the basis of angiographic findings, a diagnosis of pure vasospasm was considered likely [4], and a diagnosis of KS was made on account of cutaneous and respiratory symptoms which resolved after bronchodilators, hydrocortisone and diphenhydramine. Prior to discharge,

the repeat ECG revealed resolution of S-T segment depression, while troponin returned to normal values. Subsequently, the patient was discharged on day five of hospital admission.

## Discussion

KS is a vasospastic acute coronary syndrome, also described as “allergic angina” or “allergic myocardial infarction” depending on the presence or the absence of underlying coronary artery disease [5]. It is a condition which occurs in response to mast cells degranulation inducing an allergic reaction, with subsequent release of some inflammatory mediators. These include histamine, platelet activating factors, proteases, leukotrienes, numerous cytokines, prostaglandins [6]. The chemical mediators play a role in coronary vasospasm and/or atherosclerotic plaque



**Figure 3:** Angiography - Normal left and right coronary arteries.

rupture, leading to acute coronary syndrome [2-6]. Specifically, anaphylactic reaction happened in this case [7]. Symptoms and signs recorded in our patient correlate with subtype I (vasospasm, without predisposing factors for coronary artery disease), due to endothelial dysfunction or microvascular angina alone [8]. On the other hand, hypotension caused by anaphylaxis can lead to myocardial hypoperfusion and acute ischemia, further explaining the manifestations of acute coronary syndrome. In our patient, troponin I (that can be normal or reflect the progression towards AMI) showed a small increase followed by a return towards the normal values, reflecting the absence of any coronary artery impairment. ST segment alteration is related to coronary vasospasm. Therapy directed towards the allergic insult can be performed in accordance with the recommendations of allergy, asthma and immunology societies [9], analogously, to the case recently described by Omri, et al. [10] and Shen, et al. [11]. It remains the primary treatment to hemodynamically normalize these patients. Nevertheless, future studies are needed to understand the close mechanisms of anaphylaxis in inducing acute coronary temporary impairment.

### Conflict of Interests

The authors declare that they have no conflict of interest.

### References

1. Kounis NG, Zavras GM (1991) Histamine-induced coronary artery spasm: The concept of allergic angina. *Br J Clin Pract* 45: 121-128.
2. Kounis NG (2013) Coronary hypersensitivity disorder: The Kounis syndrome. *Clin Ther* 35: 563-571.
3. Gangadharan V, Bhatheja S, Balbissi KA (2013) Kounis syndrome-an atopic monster for the heart. *Cardiovasc Diagn Ther* 3: 47-51.
4. Gazquez V, Dalmau G, Gaig P, Gomex C, Navarro S, et al. (2010) Kounis syndrome: Report of 5 cases. *J Investig Allergol Clin Immunol* 20: 162-165.
5. Waller BF (2010) Non atherosclerotic coronary heart disease. In: Fuster V, Wane Alexander A, O'Rourke RA, Hurst's-The Heart. (13<sup>th</sup> edn), New York McGraw-Hill.
6. Gonzales-de-Olano D, Alvarez-Twose I, Matito A, Sanchez-Munoz L, Kounis NG, et al. (2011) Mast cell activation disorders with cerebral vasospasm related symptoms, a "Kounis like"? *Int J Cardiol* 150: 210-211.
7. Nahas O, Nkashama-Tshiaba L, Demoly P, Chiriach AM (2016) Anaphylaxis case report to trimethylphloroglucinol (Spasfon). *Allergol Int* 65: 481-482.
8. Nikoladis LA, Kounis NG, Gradman AH (2002) Allergic angina and allergic myocardial infarction: A new or an old syndrome. *Can J Cardiol* 18: 508-511.
9. Joint Task Force on Practice Parameters; American Academy of Allergy, Asthma and Immunology; American College of Allergy, Asthma and Immunology; Joint Council of Allergy, Asthma and Immunology (2005) The diagnosis and management of anaphylaxis: An updated practice parameters. *J Allergy Clin Immunol* 115: S483-S523.
10. Omri M, Krallem H, Mejri O, Najia M, Chebili N (2017) Management of Kounis syndrome: Two case reports. *J Med Case Rep* 11: 145.
11. Shen G, Wu Y, Bion J, Zhang Y (2017) Kounis syndrome secondary to use in a middle-aged female. *J Cardiol Clin Res* 5: 1112.