




CASE SERIES AND SYSTEMATIC REVIEW

Left Ventricular Function and Myocardial Longitudinal Strain Analysis in Patients with Chagas Disease: Case Series and Systematic Literature Review

José Victor da Nóbrega Borges^{1*} , Kiran Sooraj Thirukonda Jegadeesh Babu² , Karma Jashvantbhai Patel³ , Kavya Hitesh kumar Shah³ , Mahitha Reddy⁴ , Abdul Majid Shaik⁵ , Muhammad Ahmed Shaikh⁶  and Sahithi Burra⁷ 



¹University of Sao Paulo Medical School Heart Institute, Sao Paulo, Brazil

²Sri Ramachandra Institute of Higher Education and Research, Chennai, India

³Gujarat Medical Education Research Society Medical College and Hospital, Himmatnagar, Gujarat, India

⁴Kasturba Medical College, Manipal, India

⁵Kakatiya Medical College, Warangal, India

⁶University Jinnah Sindh Medical, Karachi, Pakistan

⁷Osmania Medical College, Hyderabad, India

*Corresponding author: José Victor da Nóbrega Borges, University of Sao Paulo Medical School Heart Institute, Sao Paulo, Brazil

Abstract

Introduction: Left ventricular dysfunction in an independent predictor of mortality in Chagas disease. Global longitudinal strain (GLS) is an emerging echocardiographic modality with possible incremental value in early detection of cardiac involvement.

Objective: Compare left ventricular function with multiple echocardiographic parameters between patients with the indeterminate and chronic forms of Chagas and perform a literature review.

Methods: In this observational study, 11 patients with a confirmed diagnosis of Chagas disease were evaluated. Individuals were distributed as follows: 5 with the indeterminate and 6 with the chronic forms. Conventional echocardiographic evaluation was followed by GLS measurement.

Results: The mean left ventricle ejection fraction LVEF was 33 ± 2.88 and the mean GLS of the left ventricle was -10.76 ± 2.20 in the chronic form as compared to 57.80 ± 6.49 and -17.34 ± 3.82 , respectively in the indeterminate group. Contractility was reduced in segments of the inferior, inferoseptal and anteroseptal walls in both groups.

Conclusion: Analysis of longitudinal strain in the indeterminate form has potential incremental value to the conventional analysis of ejection fraction when compared to patients with chronic Chagas cardiomyopathy, especially with individual segmental analysis but the impact and clinical significance of these techniques is still unknown.

Introduction

Chagas disease is one of the leading causes of tropical disease in the New World, with a higher burden than any other parasitic disease in the Americas [1]. It is caused by infection with *Trypanosoma cruzi* (*T. cruzi*), a hemoflagellate protozoan parasite primarily transmitted by triatomine bugs which feed on human and animal blood by biting on exposed areas. From the feces of the bugs, the parasite passes through these breaks in the skin or mucosa causing infection. Rarely, it may be transmitted congenitally, via organ transplantation or through contaminated food and water [2]. The different routes of transmission vary between geographic areas. First described in 1909 by Carlos Chagas, after whom it

was named, Chagas disease was initially largely confined to Latin America where it is endemic [3]. Though vector transmission has been controlled to an extent in formerly endemic areas, with current migration trends, the prevalence has also increased in the United States, Europe and Japan [4]. In 2019, the global prevalence of Chagas disease was estimated to be 6,469,283, an 11.3% decrease in prevalence in the preceding three decades from 1990. However, it was accompanied by an increase in prevalence in non-endemic countries. Spain had the largest absolute increase in estimated cases, followed by the United States and Italy [5]. This increase is mainly due to the population movement of already-infected individuals from endemic areas in contrast to the rarity of vector-borne transmission in non-endemic countries [6]. Only 16 infections were presumably acquired by autochthonous vector-borne transmission in the United States from 1955 to 2012 [7,8]. Polymerase chain reaction (PCR) testing is the most sensitive test in diagnosis of acute Chagas infection including monitoring of the organ transplant patients from *T. cruzi* infected donors and immunocompromised patients [9]. To confirm chronic Chagas disease, at least two serological antibodies detection tests with different methods are required [10,11]. Indirect immunofluorescence, enzyme-linked immunosorbent assay (ELISA), and hemagglutination are most commonly used [12,13]. In the acute phase, patients are often asymptomatic or present with mild symptoms such as fever, fatigue, and rash, whereas the chronic form usually presents with gastrointestinal manifestations and most seriously cardiomyopathy, including heart failure, arrhythmias, and sudden cardiac death. Left ventricular dysfunction is an independent predictor of mortality in Chagas disease. Systolic dysfunction is often preceded by subclinical manifestations. Global longitudinal strain (GLS) is a non-invasive modality derived from bidimensional speckle tracking echocardiography (STE) [14]. Assessment of STE along with conventional echocardiography has shown to detect subclinical left ventricular myocardial strain abnormalities even before a profound reduction in Left ventricular ejection fraction (LVEF) in Chagas cardiomyopathy [15,16]. This technique emerges as a significant predictor of adverse cardiovascular events in patients with the indeterminate form of the disease [17].

Methods

A cross-sectional observational study of 11 patients with confirmed diagnosis of Chagas disease was conducted at a tertiary care specialized hospital in Brazil. Patients underwent detailed history, physical examination, resting electrocardiogram (ECG), and conventional bidimensional echocardiography with Doppler followed by GLS analysis using speckle tracking. Participants had an average age of 76.36 +/- 6.26 years and a written informed consent for clinical

data usage was required for each individual in the study. The patients were classified as indeterminate (45%) and cardiac (55%) forms of Chagas disease [18]. The patients with Chagas cardiomyopathy were classified as stage B1, B2, C and D [18]. B1 is defined as structural changes as seen on ECG or echocardiography with normal global ventricular function and no symptoms of heart failure. Stage B2 shows structural cardiomyopathy with ventricular dysfunction but no present or past symptoms of heart failure. Stage C is defined as patients with ventricular dysfunction and present or past symptoms of heart failure (all NYHA classes) and stage D is treatment-refractory heart failure requiring specialized interventions. Patients underwent serologic confirmation by anti-*T. cruzi* enzyme-linked ELISA (Ortho Clinical Diagnostic, USA) and indirect hemagglutination assay (IHA) (Polychaco, Lemos Laboratory SRL, Argentina). Echocardiography was performed using Philips Epiq 7C with a 3.4 MHz sector transducer. Measurements for left ventricular parameters were made according to recommendations by the American Society of Echocardiography and the European Association of Cardiovascular Imaging [19]. LVEF was calculated by the modified Simpson's biplane method using the apical four and two-chamber views. Left ventricle segmental and longitudinal strain analyses were conducted using QLAB system (Philips, Netherlands). A scoping review of literature was performed on major medical sciences databases, including Pubmed and Scopus. Keyword inclusion criteria were selected for the following: Chagasic cardiomyopathy and left ventricle global longitudinal strain. The results were filtered to include full-text case reports of humans with Chagas disease, written in English. A total of 25 records were obtained during the initial search. Two reviewers screened the titles and abstracts to determine if they met the inclusion criteria. During the screening, 12 records were excluded. A total of 13 records proceeded to the full-text assessment. Four reviewers assessed the content of the case reports to determine if they had enough information about the patients and their disease. Baseline characteristic and echocardiographic parameters for the patients enrolled in the study are presented in Table 1.

Case Series Presentation

This cross-sectional observational study included 11 participants selected from a cohort of Chagas disease patient's follow-up at a tertiary center in Brazil, with 7 males (63.34%) and 4 females (36.36%) that were divided into chronic (55%) and indeterminate forms (45%). The mean age of the participants was 76.36 +/- 6.26 years with mean age of 79.56 +/- 5.16 in the chronic group and 72.51 +/- 5.19 in the indeterminate group. In terms of classification of disease severity, patients in the chronic and indeterminate phases were classified as B1 and C stages, respectively [18]. Clinical evaluation

Table 1: Baseline characteristic and echocardiographic parameters for the patients enrolled in the study.

Patient No.	Age (years)	Body surface area (sq meter)	LVEF (%)	LA volume index (ml sq meter)	LV mass (g)	LV ESV (ml)	LV EDV (ml)	LV GLS (%)	ANT-SEPT LS (%)	ANT LS (%)	ANT-LAT LS (%)	INF-LAT LS (%)	INF LS (%)	INF-SEPT LS (%)	E-e' ratio	LVSD (mm)	LVDD (mm)
1	74.5	1.698	31	79.51	277	127	186	-14.2	-9	-18	-20	-19	-15	-17	20.4	51.6	60.8
2	71.58	1.555	28	58.96	185.28	152	195	-7.1	-5	-8	-4	-7	-6	-6	38	55.8	62.2
3	67.66	1.674	51	34.29	377	116	234	-11.2	-16	-11	-10	-11	-11	-6	10	49.5	67.3
4	67.16	1.664	65	40.21	310	53	152	-22.2	-18	-24	-26	-21	-22	-22	13	35.7	55.7
5	78.33	1.73	33	62.41	366		190	-9.8	-9	-8	-10	-11	-11	-6	31.33		61.5
6	83.58	1.791	34	41.2	302		190	-12.1	-14	-11	-14	-20	-8	-8	19.75		61.4
7	77.83	1.492	62	23.13	209	49	149	-18.5	-23	-20	-22	-15	-14	-16	9.8	34.6	55.3
8	85.5	1.528	35	52.28	257	133	204	-9.9	-8	-7	-10	-12	-4	-9	24	52.6	63.4
9	70.33	2.151	49	38.5	287		194	-15.1	-17	-15	-18	-19	-10	-12	13		63
10	79.58	1.932	62	27.33	240		140	-19.7	-13	-27	-19	-18	-21	-19	18		53.7
11	83.91	1.637	37	58.84	381		201	-11.5							65		63

LA: Left Atrium; LV: Left Ventricle; LVEF: Left Ventricle Ejection Fraction; LV ESV: Left Ventricular End-Systolic Volume; LV EDV: Left Ventricular End-Diastolic Volume; LV GLS: Left Ventricular Global Longitudinal Strain; ANT-SEPT LS: Anterior-Septal Longitudinal Strain; ANT LS: Anterior Longitudinal Strain; ANT-LAT LS: Anterior-Lateral Longitudinal Strain; INF-LAT LS: Inferior-Lateral Longitudinal Strain; INF LS Inferior Longitudinal Strain; INF-SEPT LS: Inferior-Septal Longitudinal Strain; E-e' ratio: Ratio of Early Transmitral Flow Velocity (E) To Early Diastolic Tissue Velocity (e') in Echocardiography; LVSD: Left Ventricular Septal Diameter; LVDD: Left Ventricular Diastolic Diameter

included detailed history, physical examination, resting electrocardiogram (ECG), and conventional bidimensional echocardiography with Doppler followed by GLS analysis using speckle tracking. Written consent was obtained from study participants and even though no direct intervention was promoted the proposed analysis was also approved by the institutional ethics review board. Patients of the indeterminate form were initially screened and tested for Chagas disease due to either generalized symptoms or suggestive epidemiological history without cardiovascular disease at the time of diagnosis. Patients of the chronic form presented with classic symptoms of heart failure such as bilateral lower extremity edema, shortness of breath on exertion and paroxysmal nocturnal dyspnea. Three of the six patients (50%) in the chronic form were in New York Heart Association (NYHA) class II, two patients in NYHA class III, and one patient in NYHA

class I. One patient of the chronic form also had non-sustained ventricular tachycardia (NSVT) registered on 24-hour Holter monitoring (Figure 1). The mean values for the echocardiographic and baseline parameters for all individuals are presented on Table 2. At the time of diagnosis, serologic confirmation by anti-*T. cruzi* ELISA (Ortho Clinical Diagnostic, USA) and IHA (Poly chaco, Lemos Laboratory SRL, Argentina) was established. All patients were treated according to the most recent guidelines in cardiomyopathies.

Echocardiographic analysis was performed and reviewed by two board certified echocardiographers using Philips Epiq 7C with a 3.4 MHz sector transducer. Measurements were conducted according to American Society of Echocardiography and the European Association of Cardiovascular Imaging guidelines [19]. LVEF was calculated by the modified Simpson's biplane method using the apical four and two-chamber views. Left ventricle segmental and longitudinal strain analysis

Table 2: Mean values of all participants.

Variable	Value
N	11
Male (%)	63.64
Female (%)	36.36
Age (years)	76.36 ± 6.26
Body surface area (sq meter)	1.7138 ± 0.1819
LVEF (%)	44.27 ± 13.27
LA volume index (ml sq meter)	46.96 ± 16.16
LV mass (g)	290.11 ± 62.85
LVSD (mm)	46.63 ± 9.13
LVDd (mm)	60.66 ± 3.90
LV ESV (ml)	105 ± 43.44
LV EDV (ml)	185 ± 26.38
E-e' ratio	23.84 ± 15.48
ANT-SEPT LS (%)	-13.20 ± 5.21
ANT LS (%)	-14.90 ± 6.72
ANT-LAT LS (%)	-15.30 ± 6.45
INF-LAT LS (%)	-14.63 ± 5.04
INF LS (%)	-12.20 ± 5.61
INF-SEPT LS (%)	-12.10 ± 5.68
LV GLS (%)	-13.75 ± 4.47

Table 3: Mean values of participants with chronic form.

Variable	Value
N	6
Age	79.56 ± 5.18
Body surface area (sq meter)	1.6565 ± 0.1024
LVEF (%)	33 ± 2.88
LA volume index (ml sq meter)	58.87 ± 12.60
LV mass (g)	294.71 ± 72.51
LVSD (mm)	53.33 ± 2.19
LVDd (mm)	62.05 ± 1.00
LV ESV (ml)	137.33 ± 13.05
LV EDV (ml)	194.33 ± 7.005
E-e' ratio	33.08 ± 17.13
ANT-SEPT LS (%)	-9.83 ± 3.54
ANT LS (%)	-10.83 ± 4.16
ANT-LAT LS (%)	-11.16 ± 5.38
INF-LAT LS (%)	-12.83 ± 5.49
INF LS (%)	-8.33 ± 4.03
INF-SEPT LS (%)	-8.83 ± 4.16
LV GLS (%)	10.76 ± 2.20

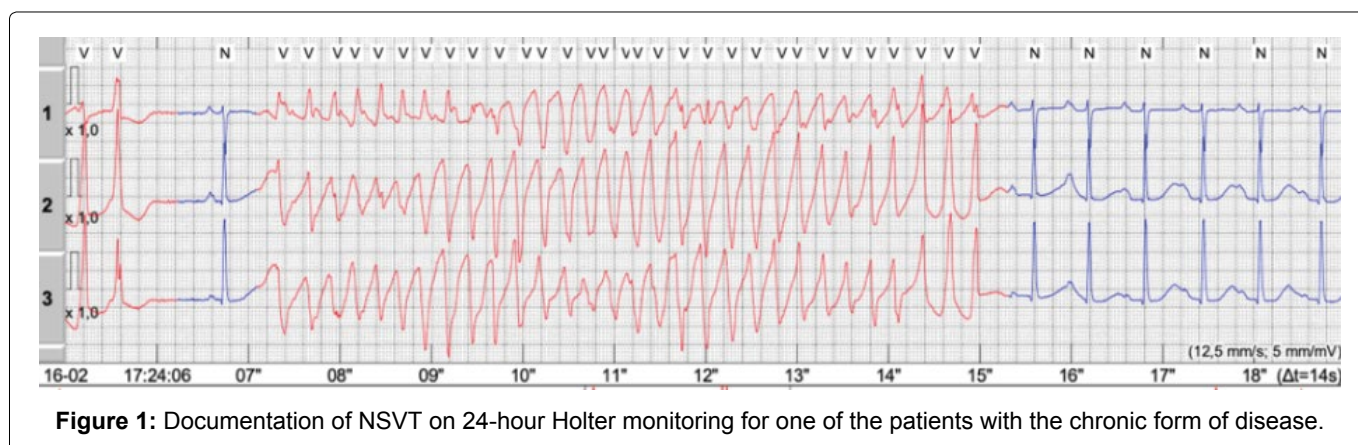


Figure 1: Documentation of NSVT on 24-hour Holter monitoring for one of the patients with the chronic form of disease.

were calculated using the QLAB semi-automatic system (Philips, Netherlands), which considered normal values $> -18\%$. The mean values for the echocardiographic parameters divided by groups are presented on [Table 3](#) (chronic form) and [Table 4](#) (indeterminate form). The end systolic volume and left ventricular systolic diameter of a few patients were not obtained due to technical difficulties and hence not included in the data presented.

Table 4: Mean values of participants with indeterminate form.

Variable	Value
N	5
Age	72.51 \pm 5.19
Body surface area (sq meter)	1.7826 \pm 0.26
LVEF (%)	57.80 \pm 6.49
LA volume index (ml sq meter)	32.69 \pm 7.29
LV mass (g)	284.6 \pm 64.98
LVSD (mm)	39.93 \pm 8.30
LVDd (mm)	59 \pm 5.86
LV ESV (ml)	72.67 \pm 37.58
LV EDV (ml)	173.8 \pm 39.57
E-e' ratio	12.76 \pm 3.31
ANT-SEPT LS (%)	-17.4 \pm 3.65
ANT LS (%)	-19.4 \pm 6.50
ANT-LAT LS (%)	-19 \pm 5.92
INF-LAT LS (%)	-16.8 \pm 3.89
INF LS (%)	-15.6 \pm 5.59
INF-SEPT LS (%)	-15 \pm 6.24
LV GLS (%)	17.34 \pm 3.82

The mean left ventricle ejection fraction LVEF was 33 ± 2.88 and the mean GLS of the left ventricle was -10.76 ± 2.20 in the chronic form as compared to 57.80 ± 6.49 and -17.34 ± 3.82 , respectively in the indeterminate group. In relation to left ventricle segmental strain, each segment was evaluated individually in each group. Myocardial deformity analysis by speckle tracking was significantly reduced in all segments of the inferior, inferoseptal and anteroseptal walls in both categories ([Figure 1](#) and [Figure 2](#)).

Discussion

Chagas disease cardiac involvement presents most commonly in the form of dilated cardiomyopathy as a result of chronic inflammation with subsequent cardiomyocyte loss. The final stage of disease is characterized by disruption of muscle fibers and neuronal structures with replacement by fibrotic tissue. This architectural anomaly contributes to electrophysiological dysfunction and is a major factor in the propensity of chagasic individuals to experience ventricular arrhythmias and heart failure [18,20,21] accounting for considerable morbidity and mortality [15]. The degree of ventricular dysfunction also determines the severity of ventricular arrhythmia. One of the main causes of death in this population is sudden cardiac death (SCD), accounting for nearly 55-60% of deaths. Patients with a history of syncope, severe bradyarrhythmia, and cardiac arrest are more likely to develop SCD [18,21,22]. Clinical features can be divided into three stages: acute, indeterminate, and chronic. Acute Chagas disease typically persists from 8 to 12 weeks and frequently remains undiagnosed because

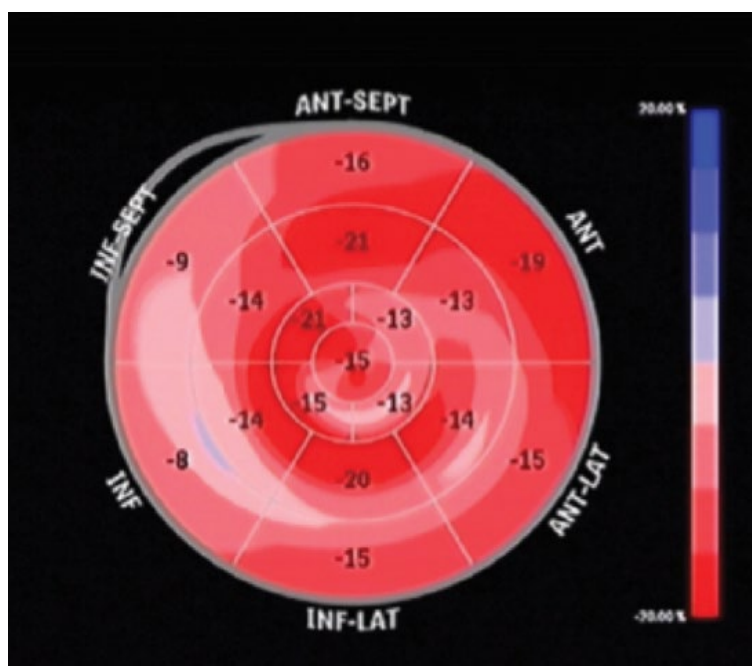


Figure 2: As represented in the bull's eye, segmental contractility of the left ventricle analyzed by bidimensional strain derived from STE was significantly reduced in the inferior, inferoseptal, and anteroseptal walls with similar results in both groups.

most patients are asymptomatic or experience only mild and nonspecific symptoms such as fever, tiredness, lymphadenopathy, hepatomegaly, and splenomegaly. Local signs at the infection site may also be noted, like the characteristic chagoma (*T. cruzi* skin abscess) or the Romaña sign (unilateral conjunctivitis with painless swelling of the eyelids). Other organ systems less frequently involved include: gastrointestinal tract and nervous system. Fulminant disease commonly presents with acute myocarditis, pericardial effusion, and mural thrombosis [18]. In the indeterminate phase, patients are asymptomatic and have preserved LVEF. Nearly 20-40% patients with acute Chagas disease [23] develop chronic disease 20 to 30 years later, either in the form of megaesophagus, megacolon or Chagas Heart disease [24]. Cardiac involvement is marked by significant arrhythmias (both supraventricular or ventricular), and ventricular aneurysms [25]. Damage to the electrical conduction system is also a prevalent cause of atrioventricular block [15] with right bundle branch block (RBBB) as the most common intraventricular conduction abnormality and often one of the first manifestations of disease. The combination of RBBB and left anterior fascicular block is strongly suggestive of Chagas disease [18] in high-risk groups. Pulmonary and systemic thromboembolism formation [26], myocardial scarring and wall motion abnormalities, most commonly in the apical and inferolateral walls, are also reported. Cardiac manifestations make up a significant part of Chagas disease morbidity and mortality but clinical deterioration can have an insidious course as seen in the indeterminate form. We intend to compare the progression of left ventricular function through multiple echocardiographic parameters in indeterminate and chronic forms of Chagas disease, through a case series. In doing so, we suggested the possibility of using GLS as an incremental value to the ejection fraction of the left ventricle in the early identification of cardiac changes. Concurrently, a literature review of the topic

was also conducted. The analysis of left ventricular myocardial changes in Chagas cardiomyopathy using speckle tracking was first studied across the spectrum of ejection fractions (from preserved to reduced) by Lima, et al. [27]. Speckle tracking is an echocardiographic tool that allows automated quantitative frame-by-frame tracking of interactions between acoustic changes and regional myocardial changes [27,28]. The study showed a decreased strain in the inferior and posterior heart walls with paradoxical increase in septal and anterior segments across the evolution of Chagas cardiomyopathy. It also demonstrated reduced longitudinal velocities in the indeterminate form [27]. Another cross-sectional study was able to demonstrate an early abnormal change in regional longitudinal strain in patients with indeterminate form localized to the inferior, septal inferior and inferolateral segments. When compared with cardiac magnetic resonance imaging, these changes occurred before cardiac fibrosis [29]. The prognostic value of biomarkers and strain parameters has been prospectively studied more recently in the same cohort that demonstrated an independent association of LV GLS, left ventricular torsion and brain natriuretic peptide (BNP) levels with a composite outcome consisting of mortality, hospital admission, heart transplant or device implantation in patients with chronic Chagas disease [30]. In our review, we have included the study data on speckle tracking echocardiography in Chagas disease currently present in literature on Table 5.

Conclusion

The addition of global longitudinal strain analysis to conventional echocardiography yields a potential incremental value at detection of subclinical myocardial changes before significant reduction in left ventricle ejection fraction. When compared to patients with the chronic variant of Chagas disease, individual segmental analysis in the indeterminate form may allow early

Table 5: Data on speckle tracking echocardiography in chagas disease currently present in literature.

Author	Type of Study	Participants	Parameters
Garcia-Alvaraez (2011)	Cross-sectional	98	GLS, radial and circumferential strain
Barbosa (2014)	Cross-sectional	78	GLS, radial and circumferential strain
Gomes (2016)	Cross-sectional	126	GLS, radial and circumferential strain
Lima (2016)	Cross-sectional	131	GLS, twist/torsion and rotational strain
Lima (2017)	Cross-sectional	42	GLS, twist/torsion and rotational strain
Santos Jr. (2019)	Prospective cohort	122	GLS
Echeverría (2020)	Cross-sectional	273	GLS
Cianciulli (2021)	Cross-sectional	90	GLS
Romano (2020)	Cross-sectional	69	GLS, radial and circumferential strain
Echeverria (2022)	Prospective cohort	177	GLS
Win (2022)	Prospective cohort	139	GLS
Hotta (2022)	Prospective cohort	72	GLS
Mendes (2023)	Prospective cohort	361	GLS

recognition of patients at risk for progression to clinical cardiac dysfunction as suggested by this case series and systematic literature review in line with current available data. However, the clinical impact and significance of these newer techniques remain unknown.

References

- World Health Organization (2008) Global burden of disease estimates: 2004 update, 2008, geneva, switzerland, WHO.
- de Fuentes-Vicente JA, Gutiérrez-Cabrera AE, Flores-Villegas AL, Lowenberger C, Benelli G, et al. (2018) What makes an effective chagas disease vector? Factors underlying *Trypanosoma cruzi*-triatomine interactions. *Acta Trop* 183: 23-31.
- Chagas C (1909) Nova tripanozomíaze humana: Estudos sobre a morfologia e o ciclo evolutivo do *Schizotrypanum cruzi* n. gen., n. sp., agente etiológico de nova entidade morbida do homem. *Memórias do Instituto Oswaldo Cruz* 1: 159-218.
- Dias JC, Silveira AC, Schofield CJ (2002) The impact of chagas disease control in Latin America: A review. *Mem Inst Oswaldo Cruz* 97: 603-612.
- Gómez-Ochoa SA, Rojas LZ, Echeverría LE, Muka T, Franco OH (2022) Global, regional, and national trends of chagas disease from 1990 to 2019: Comprehensive analysis of the global burden of disease study. *Glob Heart* 17: 59.
- Gascon J, Bern C, Pinazo MJ (2010) Chagas disease in Spain, the United States and other non-endemic countries. *Acta Trop* 115: 22-27.
- Dorn PL, Perniciaro L, Yabsley MJ, Roellig DM, Balsamo G, et al. (2007) Autochthonous transmission of *Trypanosoma cruzi*, Louisiana. *Emerg Infect Dis* 13: 605-607.
- Cantey PT, Stramer SL, Townsend RL, Kamel H, Ofafa K, et al. (2012) The United States *trypanosoma cruzi* infection study: Evidence for vector-borne transmission of the parasite that causes chagas disease among United States blood donors. *Transfusion* 52: 1922-1930.
- Chin-Hong PV, Schwartz BS, Bern C, Montgomery SP, Kontak S, et al. (2011) Screening and treatment of chagas disease in organ transplant recipients in the United States: Recommendations from the chagas in transplant working group. *Am J Transplant* 11: 672-680.
- Schijman AG, Vigliano C, Burgos J, Favaloro R, Perrone S, et al. (2000) Early diagnosis of recurrence of *Trypanosoma cruzi* infection by polymerase chain reaction after heart transplantation of a chronic Chagas' heart disease patient. *J Heart Lung Transplant* 19: 1114-1117.
- Gomes ML, Galvao LM, Macedo AM, Pena SD, Chiari E (1999) Chagas' disease diagnosis: Comparative analysis of parasitologic, molecular, and serologic methods. *Am J Trop Med Hyg* 60: 205-210.
- Bern C, Montgomery SP, Herwaldt BL, Rassi A Jr, Marin-Neto JA, et al. (2007) Evaluation and treatment of chagas disease in the United States: A systematic review. *JAMA* 298: 2171-2181.
- Brasil M (2005) Consenso brasileiro em doença de Chagas. *Rev Soc Bras Med Trop* 30: 12-14.
- Kang Y, Xu X, Cheng L, Li L, Sun M (2014) Two-dimensional speckle tracking echocardiography combined with high-sensitive cardiac troponin T in early detection and prediction of cardiotoxicity during epirubicin-based chemotherapy. *Eur J Heart Fail* 16: 300-308.
- Win S, Miranda-Schaeubinger M, Durán Saucedo RG, Jimenez PC, Flores J, et al. (2022) Early identification of patients with chagas disease at risk of developing cardiomyopathy using 2-D speckle tracking strain: Win, miranda prediction of chagas cardiomyopathy. *Int J Cardiol Heart Vasc* 41: 101060.
- Collier P, Phelan D, Klein A (2017) A test in context: Myocardial strain measured by speckle-tracking echocardiography. *J Am Coll Cardiol* 69: 1043-1056.
- Echeverría LE, Rojas LZ, Rueda-Ochoa OL, Gómez-Ochoa SA, Mayer MA, et al. (2022) Longitudinal strain by speckle tracking and echocardiographic parameters as predictors of adverse cardiovascular outcomes in chronic chagas cardiomyopathy. *Int J Cardiovasc Imaging* 38: 1245-1255.
- Nunes MCP, Beaton A, Acquatella H, Bern C, Bolger AF, et al. (2018) Chagas cardiomyopathy: An update of current clinical knowledge and management: A scientific statement from the american heart association. *Circulation* 138: e169-e209.
- Lang RM, Badano LP, Mor-Avi V, Afilalo J, Armstrong A, et al. (2015) Recommendations for cardiac chamber quantification by echocardiography in adults: An update from the American society of echocardiography and the European association of cardiovascular imaging. *J Am Soc Echocardiogr* 28: 1-39.e14.
- Rocha MO, Ribeiro AL, Teixeira MM (2003) Clinical management of chronic chagas cardiomyopathy. *Front Biosci* 8: e44-e54.
- Andrade JP, Marin Neto JA, Paola AA, Vilas-Boas F, Oliveira GM, et al. (2011) I Latin American guidelines for the diagnosis and treatment of chagas' heart disease: Executive summary. *Arq Bras Cardiol* 96: 434-442.
- Rassi A Jr, Rassi SG, Rassi A (2001) Sudden death in chagas' disease. *Arq Bras Cardiol* 76: 75-96.
- Hotta VT, Abduch MCD, Vieira MLC, de Andrade Vilela A, Bocchi EA (2022) Three and two-dimensional cardiac mechanics by speckle tracking are predictors of outcomes in chagas heart disease. *Sci Rep* 12: 12237.
- Rassi A Jr, Rassi A, Little WC (2000) Chagas' heart disease. *Clin Cardiol* 23: 883-889.
- Ribeiro FFF, Moreira HT, de Barros-Filho ACL, Tanaka DM, Fabricio CG, et al. (2022) Prospective analysis of myocardial strain through the evolution of chagas disease in the hamster animal model. *Int J Cardiovasc Imaging* 38: 117-129.
- Choudhuri S, Garg NJ (2022) Platelets, macrophages, and thromboinflammation in chagas disease. *J Inflamm Res* 15: 5689-5706.
- Lima MS, Villarraga HR, Abduch MC, Lima MF, Cruz CB, et al. (2016) Comprehensive left ventricular mechanics analysis by speckle tracking echocardiography in chagas disease. *Cardiovasc Ultrasound* 14: 20.
- Cianciulli TF, Albarracín GA, Llobera MN, Prado NG, Saccheri MC, et al. (2021) Speckle tracking echocardiography in the indeterminate form of chagas disease. *Echocardiography* 38: 39-46.
- Romano MMD, Moreira HT, Marin-Neto JA, Baccelli PE, Alenezi F, et al. (2020) Early impairment of myocardial deformation assessed by regional speckle-tracking echocardiography in the indeterminate form of chagas disease without fibrosis detected by cardiac magnetic resonance. *PLoS Negl Trop Dis* 14: e0008795.
- Mendes VG, Rimolo L, de Lima ACB, Ferreira RR, Oliveira LS, et al. (2023) Biomarkers and echocardiographic predictors of cardiovascular outcome in patients with chronic chagas disease. *J Am Heart Assoc* 12: e028810.