



SHORT COMMUNICATION

Pathobiology of Human Uterine Leiomyosarcoma for Development of Novel Diagnosis and Clinical Therapy

Takuma Hayashi^{1,2,3*}, Tomoyuki Ichimura⁴, Mari Kasai⁴, Gal Gur^{3,5}, Pnina Yaish^{3,5}, Dorit Zharhary^{3,5}, Yae Kanai^{6,7}, Susumu Tonegawa⁸, Nobuo Yaegashi⁹ and Ikuo Konishi¹⁰

¹Department of Obstetrics and Gynaecology, Shinshu University School of Medicine, Japan

²Promoting Business Using Advanced Technology, Japan Science and Technology Agency (JST), Japan

³SIGMA-Aldrich Collaboration Laboratory Project, Japan

⁴Department of Obstetrics and Gynaecology, Osaka City University Graduate School of Medicine, Japan

⁵SIGMA-Aldrich Israel, Israel

⁶Pathology Division, Keio University School of Medicine, Japan

⁷The International Human Epigenome Consortium (IHEC) and CREST, Japan Science and Technology Agency (JST), Japan

⁸Department of Biology, Massachusetts Institute of Technology, USA

⁹Department of Obstetrics and Gynaecology, Tohoku University Graduate School of Medicine, Japan

¹⁰National Hospital Organization Kyoto Medical Centre, Japan

*Corresponding author: Takuma Hayashi, Department of Obstetrics and Gynaecology, Shinshu University School of Medicine; Promoting Business Using Advanced Technology, Japan Science and Technology Agency (JST); SIGMA-Aldrich Collaboration Laboratory Project, Nagano, Japan, E-mail: yoyoyo224@hotmail.com

Abstract

Uterine sarcomas comprise a group of rare tumours with differing tumour pathobiology, natural history and response to clinical treatment. Diagnosis is often made following surgical treatment for presumed malignant mesenchymal tumours and benign tumours. Currently pre-operative diagnosis does not reliably distinguish between malignant mesenchymal tumours, Uterine Leiomyosarcoma (U-LMS) and benign tumours including Leiomyomas (LMA). U-LMS is the most common sarcoma but other subtypes include endometrial stromal sarcoma (low grade and high grade), undifferentiated uterine sarcoma and adeno sarcoma. Clinical trials have shown no definite survival benefit for adjuvant radiotherapy or chemotherapy, and have been hampered by the rarity and heterogeneity of these tumour types. There is a role of adjuvant treatment in carefully selected cases following multidisciplinary discussion at U-LMS reference centres. In patients with metastatic LMS then systemic chemotherapy can be considered. Accordingly, it is necessary to analyse risk factors associated with human U-LMS, in order to establish a treatment method. Proteasome β -subunit 9 (PSMB9)/ β 1i-deficient mice spontaneously develop U-LMS, with a disease prevalence of ~37% by 12 months

of age. We found PSMB9/ β 1i expression to be absent in human U-LMS, but present in human LMA. Therefore, defective PSMB9/ β 1i expression may be one of the risk factors for human U-LMS. PSMB9/ β 1i is a potential diagnostic-biomarker for human U-LMS, and may be targeted-molecule for a new therapeutic approach.

Keywords

PSMB9/ β 1i, Diagnosis, Mesenchymal tumour, Leiomyosarcoma, Leiomyoma

Abbreviations

U-LMS: Uterine Leiomyosarcoma; LMA: Leiomyomas; SEER: Surveillance Epidemiology and End Results; PSMB9: Proteasome β -subunit 9; IHC: Immunohistochemistry

Introduction

Soft tissue sarcomas arising from the uterus are a rare and varied group of neoplasms all of mesenchymal origin. They can occur at any anatomical site and exhibit a wide range of behaviours which largely depend on the

histologic subtype and associated tumour grade. The incidence of human Uterine Leiomyosarcoma (U-LMS) is around 3-7% of all uterine malignancies and is associated with a poor prognosis when compared to endometrial carcinoma [1]. Recent results from Surveillance Epidemiology and End Results (SEER) database analysis have shown a higher incidence rate for those aged 40 years or older, compared to younger patients and twice the incidence in women of Afro-Caribbean descent compared to Caucasian women [2].

The development of gynaecologic tumours is often correlated with female hormone secretions; however, the development of human U-LMS is not substantially correlated with hormonal conditions, and the risk factors are not yet known. Importantly, a diagnostic-biomarker which distinguishes malignant human U-LMS from other uterine mesenchymal tumours including benign tumour Leiomyoma (LMA) is yet to be established. Accordingly, it is necessary to analyze risk factors associated with human U-LMS, in order to establish a treatment method. Proteasome β -subunit 9 (PSMB9)/ β 1i-deficient mice spontaneously develop U-LMS, with a disease prevalence of ~37% by 12 months of age. We found PSMB9/ β 1i expression to be absent in human U-LMS, but present in human LMA. Therefore, defective PSMB9/ β 1i expression may be one of the risk factors for human U-LMS. PSMB9/ β 1i is a potential diagnostic-biomarker for human U-LMS, and may be targeted-molecule for a new therapeutic approach.

Takuma Hayashi (Shinshu University School of Medicine) discussed a novel biomarker for detecting human U-LMS. Patients with U-LMS typically present with vag-

inal bleeding, pain and a pelvic mass, with atypical presentations of hypercalcemia and eosinophilia also being reported [3-5]. There is concern that radiographic evaluation with combined positron emission tomography/computed tomography, which is commonly used to aid assessment of patient prognosis, might not necessarily be effective for diagnosis and surveillance of human U-LMS [6-8]. Unfortunately, radiographic imaging cannot provide any medical information to help distinguish between U-LMS and other uterine mesenchymal tumours including benign tumour LMA [9,10].

Importantly, diagnostic biomarkers that are able to distinguish between human U-LMS and other uterine mesenchymal tumours are not yet established. In eukaryotes, proteasomes are large, ATP-dependent complexes located in both nucleus and cytosol. The main function of the proteasome is to degrade unneeded or damaged proteins by proteolysis, a chemical reaction that breaks peptide bonds. The proteasome and its subunits are of clinical significance, a compromised complex assembly or a dysfunctional proteasome can be associated with the underlying pathophysiology of specific diseases. Hayashi's research group reports that PSMB9/ β 1i-deficient mice exhibit spontaneous development of human U-LMS, with a disease prevalence of ~37% by 12 months of age [11]. The current focus of Hayashi's research is to probe the loss of PSMB9/ β 1i expression in human U-LMS, as well as the detectable expression of the protein in human LMA [12,13]. Defective expression of PSMB9/ β 1i is likely to be one of the risk factors for the development of human uterine neoplasms, as it is in the PSMB9-deficient mouse. Thus, PSMB9/ β 1i is useful as a novel diagnostic biomarker for human U-LMS, and

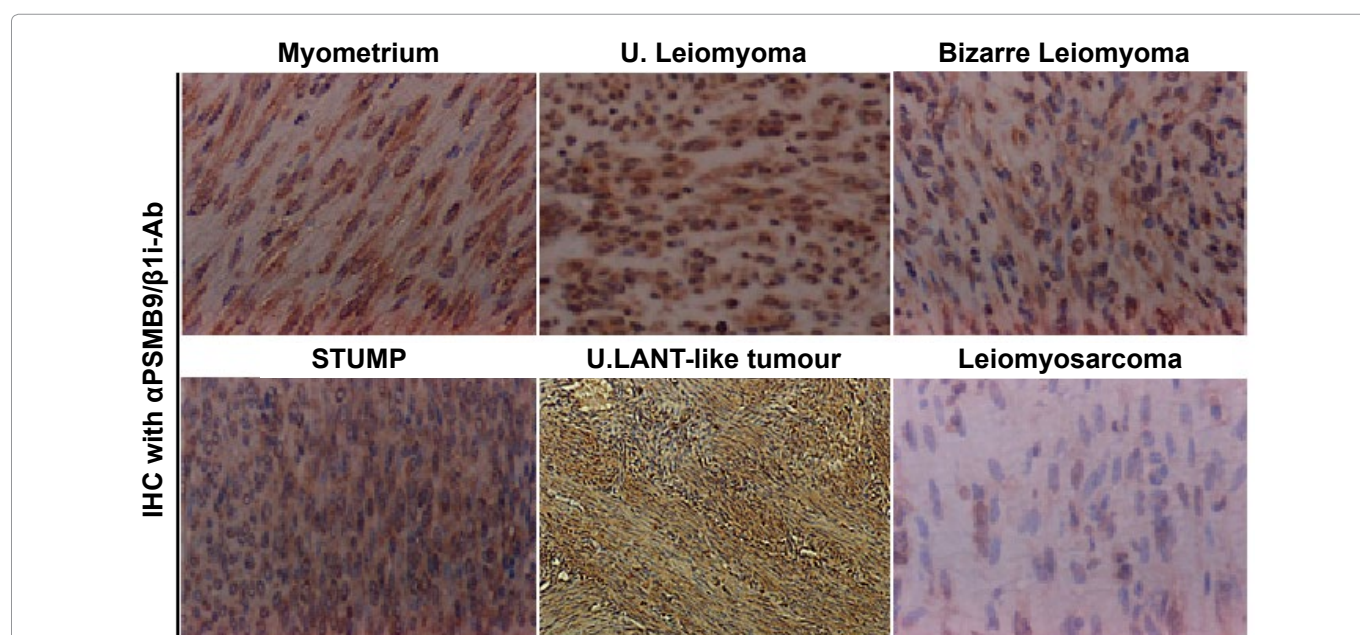


Figure 1: Differential expression of PSMB9/ β 1i in human normal myometrium, several mesenchymal tumour types and uterine LANT-like malignant tumour. Immunohistochemistry (IHC) of PSMB9/ β 1i in normal myometrium, usual leiomyoma, Bizarre leiomyoma, Smooth Muscle Tumour of Uncertain Malignant Potential (STUMP) and Uterine Leiomyosarcoma (LMS) tissues located in same tissue, and uterine LANT-like malignant tumour. For all samples, 5- μ m sections of tissues specimens were stained with anti-PSMB9/ β 1i antibody revealed by peroxidase-conjugated anti-rabbit IgG antibody.

Hayashi's research group have been trying to establish a novel diagnostic biomarker with PSMB9/ β 1i, which can distinguish the human U-LMS from other human uterine mesenchymal tumours including LMA under the SIGMA-Aldrich Collaboration Laboratory Project.

The Immunohistochemistry (IHC) experiments, performed separately at several medical facilities, revealed a serious loss in the ability to induce the expression of PSMB9/ β 1i in human U-LMS tissues in comparison with normal human myometrium tissues located in same tissue sections: normal myometrium; total 74 cases, uterine LMA; total 52 cases, Bizarre LMA; total 3 cases, U-LMS; total 58 cases. Of the 58 patients with U-LMS that we examined, 49 were negative for PSMB9/ β 1i expression, 4 were focally positive, and 3 were partially positive. Two patients with U-LMS were analyzed for the expression of PSMB9/ β 1i [12,13]. PSMB9/ β 1i levels were also evaluated in skeletal muscle and rectal metastases from individual patients with U-LMS, where surgical samples showed the presence of a mass measuring 3 cm in maximum diameter in the lumbar quadratus muscle without a fibrous capsule. All lymph nodes were negative for human LMS metastases, and IHC analyses with U-LMS showed positivity for Ki-67 (clone MIB1) and negativity for PSMB9/ β 1i (Figure 1 and Table 1). The defective expression of PSMB9/ β 1i detected in primary human U-LMS was also observed in the metastatic LMS of the skeletal muscle and rectum, indicating that the metastatic lesions conserved this biological characteristic of primary human U-LMS. In both western blotting and RT-PCR experiments, PSMB9/ β 1i was expressed in normal myometrium but not in human U-LMS, which was strongly supportive of the IHC findings. Furthermore, analysis of a human U-LMS cell line clarified the biological significance of PSMB9/ β 1i in malignant myometrium transformation and cell cycle, thus implicating PSMB9/ β 1i as an anti-tumorigenic candidate [12,13]. Human U-LMS reportedly is a highly metastatic smooth muscle neoplasm for which CALPONIN h1 is suspected to have a biological role as a tumor suppressor. Moreover, several lines of evidence indicate that although

CALPONIN h1 does not directly influence tumorigenesis, it clearly affects PSMB9/ β 1i-induced cellular morphological changes [14].

There is only one prospective Phase II study of aromatase inhibitors in human U-LMS with primary endpoint of Progression-Free Survival (PFS) at 12 weeks [15]. Whilst no objective responses were seen stable disease was recorded in 14 out of 27 patients and PFS at 12 weeks of 50%, and median duration of treatment only 2.2 months. This therapeutic approach has the benefit of being relatively well tolerated, especially when compared to chemotherapy and is recommended in patients with more indolent disease patterns and lower burden of disease. The physiological significance of PSMB9/ β 1i as a tumour suppressor may lead to new therapeutic targets in human U-LMS.

Conclusions

Defective expression of PSMB9/ β 1i is likely to be one of the risk factors for the development of human uterine neoplasm, as it is in the PSMB9/ β 1i deficient mouse. Thus, combination of PSMB9/ β 1i with other functional candidates is useful for a novel diagnostic biomarker for human U-LMS [16-19]. Additionally, gene therapy with PSMB9/ β 1i expression vectors may be a new treatment for human U-LMS that exhibit a defect in PSMB9/ β 1i expression. Because there is no effective therapy for unrespectable human U-LMS, our results may bring us to specific molecular therapies to treat this disease.

Note

Experimental procedure

Immunohistochemistry (IHC) was performed using the avidin-biotin complex method previously described [19]. Briefly, one representative 5- μ m tissue section was cut from a paraffin-embedded sample of the radical hysterectomy specimen from 58 patients with uterine Leiomyosarcoma (LMS), 52 patients with Leiomyoma (LMA), 3 patients with Bizarre LMA, 1 patient with Leiomyomatoid Angiomatous Neuroendocrine Tumour (LANT)-like tumour, normal myometrium total 74 cases.

Table 1: Differential expressions of PSMB9/ β 1i and Ki-67/MIB1 in human uterine mesenchymal tumours and uterine LANT-like tumour.

	Age years	n	PSMB9/ β 1i expression*				Ki-67/MIB1 expression*			
			-	-/+ ¹	Focal+ ²	+++ ³	-	-/+ ¹	Focal+ ²	+++ ³
Normal	32-83	74				74	74			
Leiomyoma (Ordinally leiomyoma) (Cellular leiomyoma) (Tumour of uncertain malignant potentialy)	33-83	52 (30) (10) (12)				52		10	15	27
Bizarre Leiomyoma	44,49,55	3				3				3
Leiomyosarcoma	32-83	58	49	3	4	2		2	4	52
U.LANT-like tumour	45	1	1							1

*Staining score of PSMB9/ β 1i expression and Ki-67/MIB1 expression from results of IHC experiments; -/+¹: Partially positive (5% to 10% of cells stained); Focal+²: Focal-positive (focal or sporadic staining with less than 5% of cells stained); +++³: Diffuse-positive (homogeneous distribution with more than 90% of cells stained); -: Negative (no stained cells); U.LANT-like tumour: Uterine Leiomyomatoid Angiomatous Neuroendocrine Tumour-like tumour.

Sections were deparaffinized and rehydrated in graded alcohols and then incubated with normal mouse serum for 20 min. Sections were incubated at room temperature for 1 hour with anti-human PSMB9/ β 1i antibody and anti-Ki-67/MIB1 antibody (SIGMA-Aldrich Israel, Rehovot, Israel, dilution 1/100). Afterwards, sections were incubated with a biotinylated secondary antibody (Dako, Carpinteria, CA) and then exposed to a streptavidin complex (Dako). Complete reaction was revealed by 3,3'-diaminobenzidine, and the slide was counterstained with hematoxylin. Twenty one normal human myometrium sections from specimens were used as positive controls. Negative controls consisted of tissue sections also incubated with normal rabbit IgG instead of the primary antibody. These studies are registered, at Shinshu University in accordance with local guidelines (approval no. M192).

Acknowledgments

We sincerely appreciate the generous donation of PSMB9/ β 1i-deficient breeding mice and technical comments by Dr. Luc Van Kaer (Vanderbilt University Medical School, Nashville, Tennessee). We thank Isamu Ishiwata for his generous gift of the human U-LMS cell lines. We appreciate the technical assistance of the research staff at Harvard Medical School. We are grateful to Dr. Tamotsu Sudo and Dr. Ryuichiro Nishimura (Hyogo Cancer Centre, Akashi, Hyogo, Japan) for their generous assistance with Immunohistochemistry (IHC) analysis and helpful discussion. This work was supported by grants from the Ministry of Education, Culture, Science and Technology, the Japan Science and Technology Agency (JST), the Foundation for the Promotion of Cancer Research, Kanzawa Medical Research Foundation, and The Ichiro Kanehara Foundation.

References

- D'Angelo E, Prat J (2010) Uterine sarcomas: A review. *Gynecol Oncol* 116: 131-139.
- Hosh M, Antar S, Nazzal A, Warda M, Gibreel A, et al. (2016) Uterine Sarcoma: Analysis of 13,089 Cases Based on Surveillance, Epidemiology, and End Results Database. *Int J Gynecol Cancer* 26: 1098-1104.
- Zaloudek C, Hendrickson MR (2002) Blaustein's pathology of the female genital tract. In: Kurman RJ, Mesenchymal tumors of the uterus. (5th edn), Springer-Verlag, New York, 561-578.
- Gadducci A, Landoni F, Sartori E, Zola P, Maggino T, et al. (1996) Uterine leiomyosarcoma: Analysis of treatment failures and survival. *Gynecol Oncol* 62: 25-32.
- Nordal RR, Thoresen SO (1997) Uterine sarcomas in Norway 1956-1992: Incidence, survival and mortality. *Eur J Cancer* 33: 907-911.
- Wu TI, Chang TC, Hsueh S, Hsu KH, Chou HH, et al. (2006) Prognostic factors and impact of adjuvant chemotherapy for uterine leiomyosarcoma. *Gynecol Oncol* 100: 166-172.
- Leitao MM, Soslow RA, Nonaka D, Olshen AB, Aghajanian C, et al. (2004) Tissue microarray immunohistochemical expression of estrogen, progesterone, and androgen receptors in uterine leiomyomata and leiomyosarcoma. *Cancer* 101: 1455-1462.
- Kurma RJ (2001) Pathology of the Female Genital Tract. (4th edn), Springer-Verlag, New York, 4-499.
- Diagnostic Criteria for LMS, Adapted from 2003 WHO Guidelines (2003) World Health Organization Classification of Tumours: Pathology and genetics of tumours of the breast and female genital organs. IARC press, France.
- Van Kaer L, Ashton-Rickardt PG, Eichelberger M, Gaczynska M, Nagashima K, et al. (1994) Altered peptidase and viral-specific T cell response in LMP2 mutant mice. *Immunity* 1: 533-541.
- Hayashi T, Faustman DL (2002) Development of spontaneous uterine tumors in low molecular mass polypeptide-2 knockout mice. *Cancer Res* 62: 24-27.
- Hayashi T, Kobayashi Y, Kohsaka S, Sano K (2006) The mutation in ATP-binding region of JAK1, identified in human uterine leiomyosarcomas, results in defective interferon- γ inducibility of TAP1 and LMP2. *Oncogene* 25: 4016-4026.
- Hayashi T, Horiuchi A, Sano K, Hiraoka N, Kasai M, et al. (2011) Potential role of LMP2 as tumor-suppressor defines new targets for uterine leiomyosarcoma therapy. *Sci Rep* 1: 180.
- Hayashi T, Horiuchi A, Sano K, Hiraoka N, Kasai M, et al. (2012) Potential role of LMP2 as an anti-oncogenic factor in human uterine leiomyosarcoma: Morphological significance of calponin h1. *FEBS Lett* 586: 1824-1831.
- George S, Feng Y, Manola J, Nucci MR, Butrynski JE, et al. (2014) Phase 2 trial of aromatase inhibition with letrozole in patients with uterine leiomyosarcomas expressing estrogen and/or progesterone receptors. *Cancer* 120: 738-743.
- Hayashi T, Ichimura T, Yaegashi N, Shiozawa T, Konishi I (2015) Expression of CAVEOLIN 1 in uterine mesenchymal tumors: No relationship between malignancy and CAVEOLIN 1 expression. *Biochem Biophys Res Commun* 463: 982-987.
- Hayashi T, Horiuchi A, Sano K, Hiraoka N, Ichimura T, et al. (2016) Potential diagnostic biomarkers: LMP2/ β 1i and Cyclin B1 differential expression in human uterine mesenchymal tumors. *Tumori* 100: 509-516.
- Kawano M, Hayashi T (2016) Biological analysis for understanding of the uterine Sarcomagenesis. *Global Journal for Research Analysis* 5: 310-311.
- Hayashi T, Ichimura T, Kasai M, Sano K, Zharhary D, et al. (2017) Characterization of Leiomyomatoid Angiomatous Neuroendocrine Tumour (LANT)-like tumour in the myometrium with histopathological examination. *Anticancer Res* 37: 1765-1772.