



## COMMENTARY ARTICLE

# Spontaneous Coronary Artery Dissection: An up to Date

Dario Buccheri<sup>1\*</sup> and Daniele Adorno<sup>1,2</sup>

<sup>1</sup>Interventional Cardiology, S. Antonio Abate Hospital, Italy

<sup>2</sup>Cardiology Department, AOUP "P. Giaccone", Italy



\*Corresponding author: Dario Buccheri Interventional Cardiology, "S. Antonio Abate" Hospital, Via Cosenza, 80, 91016 Erice (TP), Italy, Tel: +39-0923809177

Spontaneous dissection of the coronary artery (SCAD) is an uncommon cause of acute coronary syndrome (ACS) and is defined as a dissection of the coronary artery not associated with an atherosclerotic process, plaque rupture and/or thrombus formation and, by definition, not iatrogenic. The resulting myocardial damage is determined not by the rupture of a plaque indeed, but by the formation of an intramural hematoma (IMH) or intimal/medial disruption that determines the dissection of the arterial wall with the formation of a false lumen that obstructs the blood flow through the true lumen. SCAD can represent up to 4% of the total ACS according several casuistry [1].

The population most affected by the SCAD is the female one, representing, in fact, up to 35% of all myocardial infarction (MI) in women aged  $\leq 50$  years and also is the main cause of MI associated with the pregnancy [2]. SCAD is a condition often underdiagnosed for several reasons, such as the young age of the patients on average, the low presence of classic cardiovascular risk factors, the poor level of knowledge of this entity by physicians and the limitations of classical hallmarks for coronary artery dissection during angiography [1] causing flow deficits in the coronary arteries and therefore MI [3].

Two main theories of how a spontaneous dissection develops have been described, the first one suggests that primum movens is the formation of an interruption in the arterial wall (intimal tear), which causes blood to come out of the true lumen to create a false lumen. The second theory predicts that primum movens is a spontaneous hemorrhage from the vasa vasorum that starts the dissection process [4,5]. The presence of an

inflammatory cellular infiltrate was also noted around the spontaneous dissection that could be useful in the post-mortem diagnosis to distinguish between spontaneous and iatrogenic dissections [3].

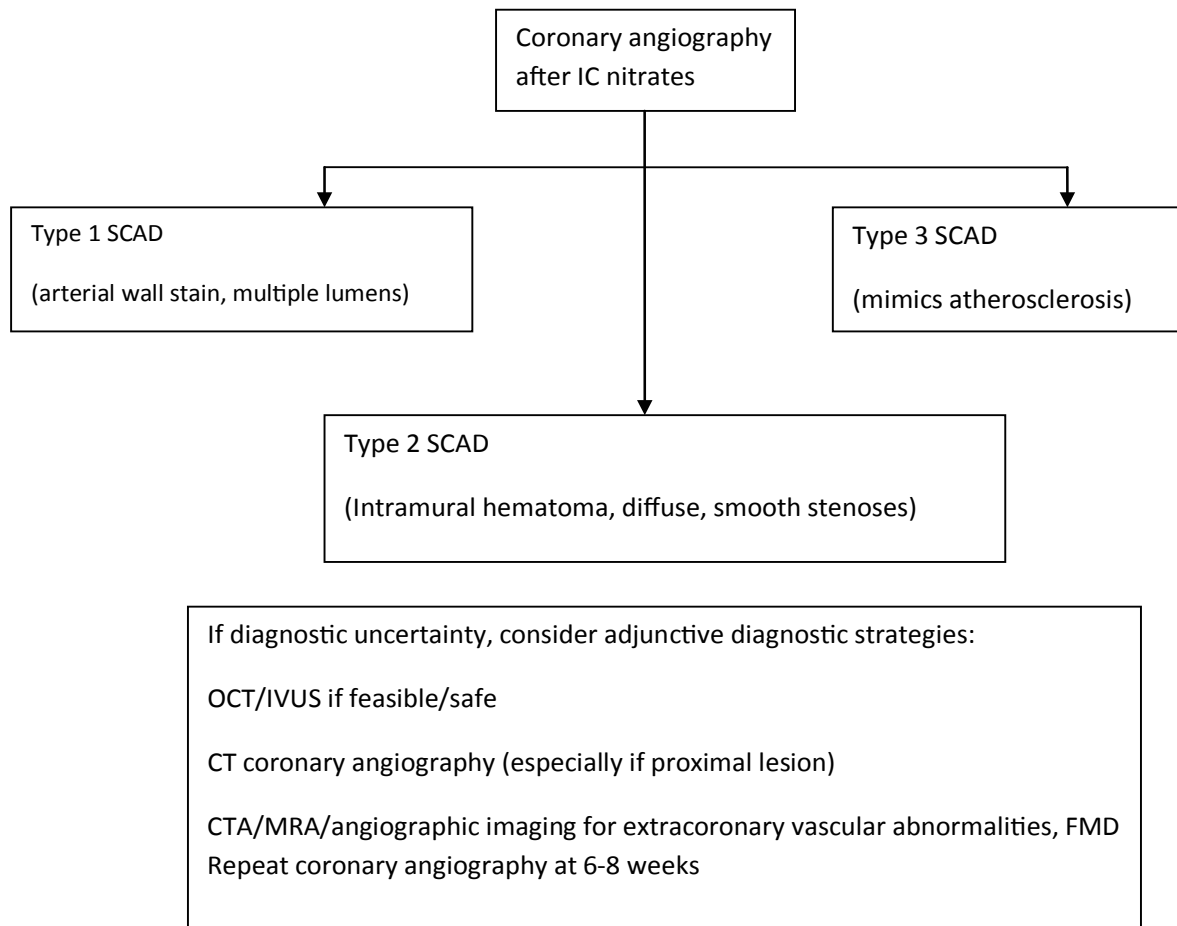
SCAD is a multifactorial disease, with a poor predominance of traditional risk factors. Predisposing factors are female gender, pregnancy, age  $< 50$  years, female sex hormones, other arteriopathies, such as fibromuscular dysplasia (FMD) that represents the most commonly extracoronary arterial disease associated. FMD is a non-atherosclerotic and non-inflammatory vascular disease that can affect any part of the arterial bed and has a very varied manifestation (arterial stenosis, aneurysm, tortuosity, or dissection) [6].

Probable triggers of SCAD, in a predisposing patient, are emotional/physical stress, intense isometric exercise, and weightlifting [7].

Clinical manifestations of SCAD include ACS (26% to 87% of patients with SCAD presents an ST-segment elevation MI), ventricular arrhythmias or sudden cardiac death [8,9].

Regarding the management of SCAD, despite the substantial difference between ACS caused by SCAD compared to those based on atherosclerosis in the field of pathogenesis, response to the medical therapy and revascularization, no randomized studies or comparisons have been performed between these strategies in ACS caused by SCAD [1].

From the point of view of the angiographic manifestation, several contemporary coronary angiography series show that the classical pathognomonic characteristics of artery dissection (presence of multiple radi-



**Figure 1:** Algorithm for diagnosis of spontaneous coronary artery dissection (SCAD) in the setting of acute coronary syndrome [1].

Clinical-angiographic score system for SCAD faster diagnosis	Point (s)
<b>❖ Clinical characteristics</b>	
• Connective tissue disorder (marfan sdr, EDS, cystic medial necrosis)/Fibromuscular dysplasia	+2
• Youth/ <50 year	+1
• No classical coronary risk factors	+1
• Estroprogestinic therapy	+1
• Pregnancy (peri-partum, history of multiple pregnancy)/Female gender	+1
• History of coronary artery spasm/previous SCAD	+3
• Amphetamines/Cocaine/Vasospastic drugs abuse	+1
• Systematic Inflammation (SLE, Crohn disease, sarcoidosis, polyarteritis nodosa, Bechet sdr)	+2
• Emotional/physical stress	+1
<b>❖ Angiographic characteristics</b>	
• One vessel disease (no typical atherosclerotic lesions in other coronary arteries)	+1
• Long/tortuose suspected lesion	+1
• Diffuse, typically smooth arterial narrowing	+1

Atleast 3 points: Indication to perform endovascular imaging (OCT or, if not available IVNUS)\*

\* In presence of a score of at least three points in a patient presenting with chest pain, ECG/Echo abnormalities or troponin rise/fall, perform OCT/IVUS analysis for suspected SCAD.

**Figure 2:** Clinical-angiographic score system for SCAD faster diagnosis [12].

olucent lumens and contrast extra luminal staining) are present only in a reduced percentage of SCADs. Therefore, for greater clarity, we report a recent proposal for angiographic classification of SCAD (Figure 1) [10]. With these premises, as an angiography supplement, intravascular imaging is a very useful means of diagnosing SCAD. In our experience, we prefer to use OCT more than IVUS. In fact, OCT improves the possibility of making a diagnosis and, in our opinion, is the intravascular imaging of the first choice in doubtful cases [11]. OCT has a spatial resolution ranging from 10 to 20  $\mu\text{m}$  and is therefore superior to IVUS in delimiting the lumen-intimal interface and discriminating true lumen, false lumen, intimal tear, and intraluminal thrombi.

According to the difficulty of angiographic SCAD diagnosis, we proposed a clinical-angiographic score system, previously worked out by our group (Figure 2). In presence of a patient with chest pain, ECG/Echo-abnormalities or a rise/fall in troponin, if at least three points are gained it's advisable to perform an intracoronary imaging (OCT as the first choice or, if unavailable, IVUS) to detect a suspected SCAD [12-15].

If a SCAD diagnosis is confirmed, recent American heart association (AHA) guidelines suggest an algorithm for management of this condition, based at first on clinically stability/instability of patient and also according on the coronary arteries anatomy (Figure 3). Thus, in a patient with a diagnosis of SCAD, clinically stable with no high-risk anatomy, a conservative therapy is reasonable, monitoring as an inpatient for 3-5 days [1]. In fact, the majority of cases of SCAD goes to spontaneous healing generally within a months, moreover, percutaneous coronary intervention (PCI) in these cases has a lower yield than ACS on atherosclerotic basis, due to a greater technical difficulty due to the fragility of the arteries and to the possible interaction between the metal stents

and IMH after the natural reabsorption of the latter [16]. Conservative management consists of medical therapy, based on ACE-I, B-blockers, statins, an antianginal drugs if necessary, dual antiplatelet therapy (DAPT) [17], also if there is little evidence regarding the duration of DAPT in patients with SCAD that don't undergo percutaneous revascularization.

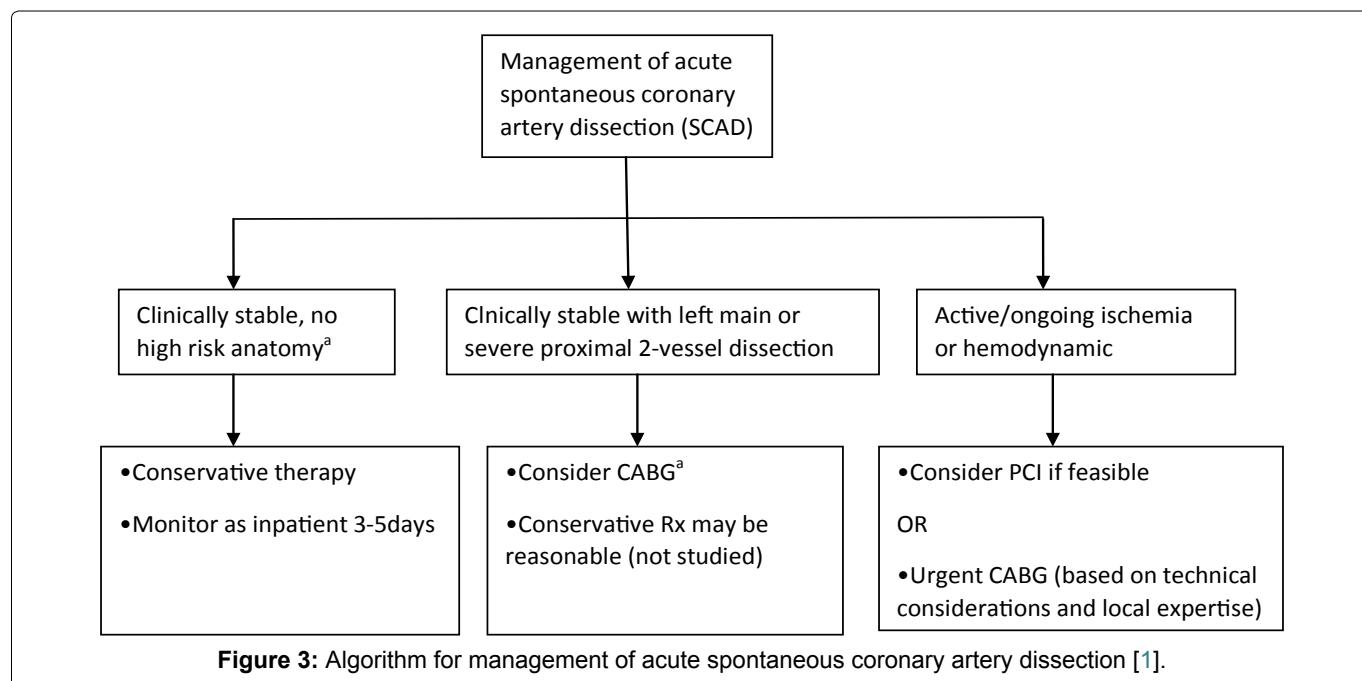
If there is a high risk-anatomy, like the left main coronary artery (LMCA) involvement or several proximal two-vessel dissections, and the patient is clinically stable, the proposed strategy is to perform a CABG, according to also with the new guidelines for myocardial revascularization [18].

Finally, if a patient is unstable and there is ongoing ischemia, PCI should be considered, based on the case and coronary anatomy [1].

In cases where PCI is needed, our approach is to prefer the use of a bioresorbable scaffold (BRS), which have proven effective and safe in our experience [19] and in a cohort analysis of 18 patients [20]. Although despite these intriguing findings, larger studies will be needed in the future.

Patients with SCAD require after hospitalization a clinical follow-up at 1, 3, 6 and 12 months. In cases where symptoms should reoccur, it is advisable to repeat an invasive re-evaluation [12]. In fact, in a series of the year 2012, the risk of relapse, with a median of 2.8 years in the second episode, was 17%, with an estimated 10-year rate of MACEs (death, heart failure, myocardial infarction, and SCAD recurrence) of 47% [16].

It is increasingly clear that the SCAD is a clinical entity, albeit uncommon, to be kept in close consideration especially in the youth and female who present with ACS without the traditional risk factors. The effort of the scientific community, as evidenced by the review



published by the AHA in 2018, is aimed at reducing more and more the lack of diagnosis and providing guidance in the management of this condition which still today has shady areas.

## References

1. Hayes SN, Kim ESH, Saw J, Adlam D, Arslanian-Engoren C, et al. (2018) Spontaneous coronary artery dissection: Current state of the science: A scientific statement from the American heart association. *Circulation* 137: e523-e557.
2. Elkayam U, Jalnapurkar S, Barakkat MN, Khatri N, Kealey AJ, et al. (2014) Pregnancy-associated acute myocardial infarction: A review of contemporary experience in 150 cases between 2006 and 2011. *Circulation* 129: 1695-1702.
3. Desai S, Sheppard MN (2012) Sudden cardiac death: Look closely at the coronaries for spontaneous dissection which can be missed: A study of 9 cases. *Am J Forensic Med Pathol* 33: 26-29.
4. Saw J, Mancini GB, Humphries K, Fung A, Boone R, et al. (2016) Angiographic appearance of spontaneous coronary artery dissection with intramural hematoma proven on intracoronary imaging. *Catheter Cardiovasc Interv* 87: E54-E61.
5. Kwon TG, Gulati R, Matsuzawa Y, Aoki T, Guddeti RR, et al. (2016) Proliferation of coronary adventitial vasa vasorum in patients with spontaneous coronary artery dissection. *JACC Cardiovasc Imaging* 9: 891-892.
6. Persu A, Van der Niepen P, Touzé E, Gevaert S, Berra E, et al. (2016) Revisiting fibromuscular dysplasia: Rationale of the European fibromuscular dysplasia initiative. *Hypertension* 68: 832-839.
7. Saw J, Aymong E, Sedlak T, Buller CE, Starovoytov A, et al. (2014) Spontaneous coronary artery dissection: Association with predisposing arteriopathies and precipitating stressors and cardiovascular outcomes. *Circ Cardiovasc Interv* 7: 645-655.
8. Lettieri C, Zavalloni D, Rossini R, Morici N, Etti F, et al. (2015) Management and long-term prognosis of spontaneous coronary artery dissection. *Am J Cardiol* 116: 66-73.
9. Nakashima T, Noguchi T, Haruta S, Yamamoto Y, Oshima S, et al. (2016) Prognostic impact of spontaneous coronary artery dissection in young female patients with acute myocardial infarction: A report from the angina pectoris-myocardial infarction multicenter investigators in Japan. *Int J Cardiol* 207: 341-348.
10. Saw J (2014) Coronary angiogram classification of spontaneous coronary artery dissection. *Catheter Cardiovasc Interv* 84: 1115-1122.
11. Saw J, Mancini GBJ, Humphries KH (2016) Contemporary review on spontaneous coronary artery dissection. *J Am Coll Cardiol* 68: 297-312.
12. Buccheri D, Piraino D, Andolina G (2016) Score system approach to diagnose and manage spontaneous coronary artery dissection. *Rev Esp Cardiol* 69: 878-879.
13. Buccheri D, Zambelli G (2016) Focusing on spontaneous coronary artery dissection: Actuality and future perspectives. *J Thorac Dis* 8: E1784-E1786.
14. Buccheri D, Piraino D, Cortese B (2016) Intravascular imaging as a tool for definite diagnosis of acute coronary syndrome caused by spontaneous coronary artery dissection. *Int J Cardiol* 214: 43-45.
15. Buccheri D, Milazzo D, Geraci S, Vaccaro G, Caramanno G (2017) A lesson from intravascular imaging: Insights for recognizing a spontaneous coronary artery dissection. *J Thorac Dis* 9: 5363-5367.
16. Tweet MS, Hayes SN, Pitta SR, Simari RD, Lerman A, et al. (2012) Clinical features, management, and prognosis of spontaneous coronary artery dissection. *Circulation* 126: 579-588.
17. Dario Buccheri, Giulia Zambelli, Fernando Alfonso, Bernardo Cortese (2017) Pulse on spontaneous coronary artery dissections: Experience-based survey. *JACC Cardiovasc Interv* 10: 1469-1471.
18. Neumann FJ, Sousa-Uva M, Ahlsson A, Alfonso F, Banning AP, et al. (2019) 2018 ESC/EACTS Guidelines on myocardial revascularization. *Eur Heart J* 40: 87-165.
19. Buccheri D, Piraino D, Latini RA, Andolina G, Cortese B (2016) Spontaneous coronary artery dissections: A call for action for an underestimated entity. *Int J Cardiol* 214: 333-335.
20. Ielasi A, Cortese B, Tarantini G, Loi B, Mazzarotto P, et al. (2016) Sealing spontaneous coronary artery dissection with bioresorbable vascular scaffold implantation: Data from the prospective "Registro Absorb Italiano (RAI Registry)". *Int J Cardiol* 212: 44-46.