



CASE REPORT

An Infected Ectopic Wisdom Tooth in the Ascending Ramus

Rajeevan Sritharan, BDS (Bris), MFDS RCSEd*, Zainab Sarwar Shaikh, BDS (Lond), MFDS RCS (Glasgow) and Steven John Liggins, BDS, MBBCh, FRCS (OMFS), FDSRCS (Ed), BSc

Dental Core Trainee in Oral & Maxillofacial Surgery, Department of Oral & Maxillofacial Surgery, Broomfield Hospital, Mid & South Essex Healthcare Trust, Broomfield, Chelmsford, United Kingdom



***Corresponding author:** Dr. Rajeevan Sritharan (R Sritharan) BDS (Bris), MFDS RCSEd, Dental Core Trainee in Oral & Maxillofacial Surgery, Broomfield Hospital, Mid & South Essex Healthcare Trust, Department of Oral & Maxillofacial Surgery, Court Rd, Broomfield, Chelmsford CM1 7ET, Tel: +44-74-2817-6494

Abstract

Ectopic wisdom teeth are a rare occurrence. Furthermore, it is highly unusual to see lower wisdom teeth in the ascending ramus of the mandible. This case report is about a 41-year-old male patient with right sided facial swelling. Presenting initially as suspected right sided parotitis, the source of the infection was quickly identified as an ectopic wisdom tooth located in the ramus of the mandible. This report describes the associated investigations, management (pre-, peri- and post-) and appropriate follow-up after discharge, for a symptomatic, ectopically placed third molar tooth. The current UK guidelines for wisdom teeth removal is published by NICE (National Institute of Clinical Excellence). In conclusion, the case highlights the importance of thorough investigation and possible amendment of current guidelines.

NICE guidelines [5] remain in place in the UK in regard to removing third molars with select criteria. The guidelines have come under scrutiny due to the inflexibility and nature of 'waiting for a problem to occur'. The case below highlights an unusual case of an ectopic molar located in the ascending ramus which became associated with a large facial/dental abscess and discussion focuses on whether NICE guidelines need adaptation to accommodate for these cases as well as emergency management of this case.

Case Report

This case details the presentation of a 41-year-old male patient with a 4-week history of a large facial swelling on the right hand-side and trismus with approximate mouth opening of one fingers breadth. The patient reported that he had no known prior medical conditions and had no allergies. The patient admitted to smoking 20 cigarettes a day. The patient reported intermittent swelling and pain on eating in the months leading up to hospital admission. He initially presented to the Ear, Nose and Throat department who suspected right parotitis with differentials of angio-oedema, trauma, infected cystic lesions and neoplastic causes also noted. Subsequently, an ultrasound scan of the swelling was requested which indicated an abscess and fluid collection. He was commenced on IV Antibiotics (co-amoxiclav) and IV dexamethasone to reduce the risk of airway compromise and admitted for fluids, monitoring and further treatment whilst the cause was being investigated. A further imaging of CT (Computer Tomography) neck was requested. The CT neck (Figure 1), revealed:

Introduction

The third molar (wisdom tooth), in all four quadrants, is usually the last tooth to erupt. Space is made when there is forward movement of the erupting dentition and resorption of bone at the back of the dental arch. However, third molars are not as straight forward in comparison to eruption to the other teeth as in several cases, there is often lack of space and therefore becomes impacted [1]. One study, carried out in Sweden, lists the incidence of at least one third molar being impacted as 72% [2]. Impaction is varied in presentation and patterns of impaction include from vertical, mesio-angular, disto-angular [3]. Time-to-time, pathology associated with lower wisdom teeth can result in a dental abscess owing to the immune response to a bacterial infection [4]. Patients will often present with facial swelling and pain ranging from mild to severe.



Citation: Sritharan R, Shaikh ZS, Liggins SJ (2020) An Infected Ectopic Wisdom Tooth in the Ascending Ramus. Res Rep Oral Maxillofac Surg 4:039. doi.org/10.23937/2643-3907/1710039

Accepted: August 08, 2020; **Published:** August 10, 2020

Copyright: © 2020 Sritharan R, et al. This is an open-access article distributed under the terms of the Creative Commons Attribution License, which permits unrestricted use, distribution, and reproduction in any medium, provided the original author and source are credited.

- A multi-loculated collection within the right masseter,
- Collection extending medial to the mandible involving the lateral pterygoid muscle, in close proximity to an impacted lower right wisdom tooth,
- Diffuse thickening and hypodensity of the right masseteric space extending along ramus extending superiorly up to the level of the zygomatic arch and infra-auricular region,
- The CT scan also showed that there was an associated cortical breach laterally.

After this investigation, the patient was transferred to the Oral and Maxillofacial Department. Clinical examination revealed a palpable right sided facial swelling in the buccal region. The swelling was warm to touch and firm. Intra-orally, no pus discharge could be elicited. The patient was afebrile on admission however, presented with raised inflammatory markers and neutrophilia. Subsequently, a DPT (Dental Panoramic Tomogram) (Figure 2) was taken for dental assessment and confirmed the tooth located high up in the ramus with associated radiolucency. A diagnosis of dental abscess secondary to the lower right wisdom tooth was made. Informed consent was gained and the patient was planned for emergency incision and drainage of the facial abscess the following morning.

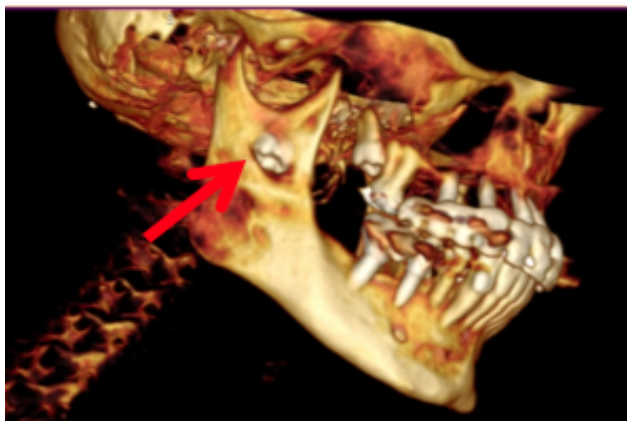


Figure 1: 3D volume reconstruction of CT mandible and Neck, Ectopic LR8 (denoted by Arrow).

Under GA (general anesthetic) the patient underwent incision and drainage and exploration of the right buccal space, sub masseteric space, Para-pharyngeal and submandibular spaces, the incision was made to ramus where the tooth was directly visualized. Approximately 100 ml of purulent fluid was drained and copious irrigation was performed with one liter of saline and hydrogen peroxide. Extra-oral drains were placed for dependent drainage. The patient stayed in hospital for a further two days post-op and seen for a review two weeks post-op where clinically there was resolution of the swelling and no further collection. The patient was presented with options of leaving the tooth in place or removing tooth with both intra-oral and sagittal split osteotomy options discussed. Informed consent was gained as risks and benefits were discussed. These included the benefits of leaving the tooth in place which avoided an osteotomy and reduced the risk of pathological fracture of mandible in future as well as permanent nerve damage. Conversely, leaving the tooth in place would be associated with a chance of subsequent severe infection and removal would help prevent associated infection with the tooth. The patient opted for removal of tooth and was placed on a waiting list for elective removal of the tooth in the Oral and Maxillofacial department.

Discussion

The case is uncommon and typically an ectopic wisdom tooth does not often present with severe symptoms and spreading infection. Further review of patient's previous radiographs taken by the patient's implant dentist may reveal pathological migration however this has not been explored. In any case, ectopic migration of the third molar to such an extent is a rare occurrence [6]. A literature search revealed 28 reported cases in the literature where third molars present high up in the ramus or condylar region [7-31]. Other regions of the mandible where ectopic wisdom teeth may present include the coronoid process, sigmoid notch and lower border of the mandible [32]. The incidence of spreading infection with these teeth is uncommon, however there are some cases in the literature. Currently the etiology of

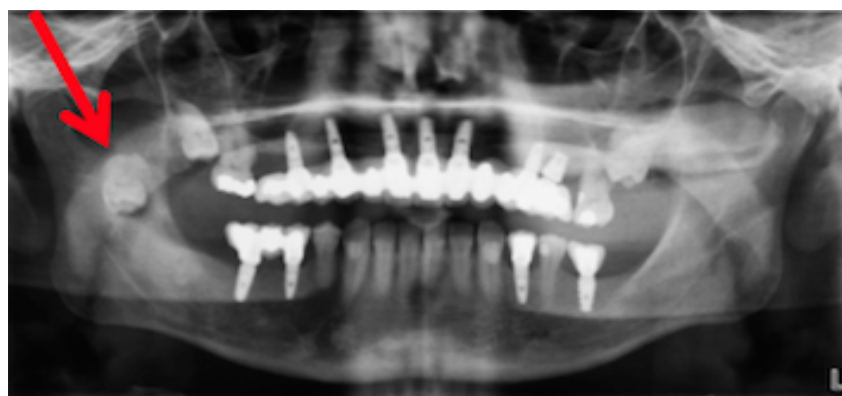

Figure 2: DPT, Ectopic LR8 (denoted by arrow).

presentation of ectopic teeth high in the ramus is poorly understood, available studies point to multiple factors including habitual location due to aborted eruption, displacement due to lesions such as cysts or osseous tumors or an alteration to the eruption process due to odontogenic tumors [33]. Ectopic wisdom teeth are associated with formation of enlarged dental follicle or a dentigerous cyst, developmental disturbances or iatrogenic activity [34]. In this case, it is likely infection was associated with breach of the cortical bone. Severe infection requires exploration of the head and neck spaces under GA and copious amounts of irrigation. A DPT should be considered part of the diagnosis work-up for all facial swellings, as a large proportion may have an underlying odontogenic cause. This is true for this case as it was initially thought that the patient presented with right unilateral parotitis. For treatment planning it is vital that a CT scan is performed for AP (anterior posterior) positioning of the tooth as well as relation to adjacent structures when considering surgical removal. CT scans are useful as they allow multiplanar reformation with volume reconstructions. A CBCT (Cone Beam Computer Tomography) may be used instead as it has the advantage of a lower radiation dose.

Currently, in the UK, NICE guidelines to remove wisdom teeth are limited to select criteria. As the patient remained largely asymptomatic prior to his hospital admission, it may be likely that early intervention and prophylactic intervention at an early stage may have prevented the events that followed. There remain some failings with use of NICE guidelines including the potential loss of both second and third molars due to caries as a result of reduction in prophylactic removal of wisdom teeth. NICE guidelines also fail to take into account that these patients are often older and as a result may have multiple comorbidities, which could increase the risk of peri-operative and post-operative complications [35].

Conclusion

This case presented several considerations for management of future cases. Presentation can often manifest as persistent facial swelling and may not directly present to a Dental Surgeon or Oral Surgeon initially. Although a rare occurrence, management requires careful planning and fundamental use of special investigations and systemic antimicrobials which present with severe orofacial infections. It is important to not only understand the etiology but also to appreciate the underlying cause of the infection and its unusual pathology.

Acknowledgements

Confirmation that all authors have viewed and agreed to the submission.

References

- Santosh P (2015) Impacted mandibular third molars: Review of literature and a proposal of a combined clinical and radiological classification. *Annals of Medical and Health Sciences Research* 5: 229.
- Dodson T, Srinivas S (2010) Impacted wisdom teeth. *BMJ Clin Evid* 1302.
- Selmi Yilmaz, Mehmet Zahit Adisen, Melda Misirlioglu, Serap Yorubulut (2016) Assessment of Third Molar Impaction Pattern and Associated Clinical Symptoms in a Central Anatolian Turkish Population. *Medical Principles and Practice* 25: 169-175.
- Robertson D, Smith A (2009) The microbiology of the acute dental abscess. *Journal of Medical Microbiology* 58: 155-162.
- NICE (2020) Overview Guidance on the Extraction of Wisdom Teeth.
- Kansy K, Gander E, Staff C, Hoffmann J, Freier K (2014) Ectopic wisdom tooth at the mandibular ascending ramus. *Oral Surgery* 7: 27-32.
- Procacci P, Albanese M, Sancassani G, Turra M, Morandini B, et al. (2011) Ectopic mandibular third molar: report of two cases by intraoral and extraoral access. *Minerva Stomatol* 60: 383-390.
- Burton DJ, Scheffer RB (1980) Serratia infection in a patient with bilateral subcondylar impacted third molars and associated dentigerous cysts: report of case. *J Oral Surg* 38: 135-138.
- Srivastava RP, Singh G (1982) An unusual impacted inverted molar in mandibular condyle with preauricular sinus (a case report). *J Indian Dent Assoc* 54: 67-69.
- Medici A, Raho MT, Anghinoni M (2001) Ectopic third molar in the condylar process: Case report. *Acta Biomed Ateneo Parmense* 72: 115-118.
- Tümer C, Eset AE, Atabek A (2002) Ectopic impacted mandibular third molar in the subcondylar region associated with a dentigerous cyst: A case report. *Quintessence Int* 33: 231-233.
- Wassouf A, Eyrych G, Lebeda R, Grätz KW (2003) Surgical removal of a dislocated lower third molar from the condyle region: case report. *Schweiz Monatsschr Zahnmed* 113: 416-420.
- Liau I, Han J, Cheng A, Duke P, Sambrook PJ, et al. (2017) Endoscopically Assisted Intraoral Removal of an Ectopic Third Molar in the Mandibular Subcondylar Region. *J Craniofac Surg* 28: 970-972.
- Gadre KS, Wanknis P (2010) Intra-oral removal of ectopic third molar in the mandibular condyle. *Int J Oral Maxillofac Surg* 39: 294-296.
- Suarez-Cunqueiro MM, Schoen R, Schramm A, Gellrich NC, Schmelzeisen R (2003) Endoscopic approach to removal of an ectopic mandibular third molar. *Br J Oral Maxillofac Surg* 41: 340-342.
- Bortoluzzi MC, Manfro R (2010) Treatment for ectopic third molar in the subcondylar region planned with cone beam computed tomography: a case report. *J Oral Maxillofac Surg* 68: 870-872.
- Wang C, Kok S, Hou L, Yang P, Lee J, et al. (2008) Ectopic mandibular third molar in the ramus region: report of a case and literature review. *Oral Surgery, Oral Medicine, Oral Pathology, Oral Radiology, and Endodontology* 105: 155-161.
- Payne K, Dickenson A, Patel M (2012) An unusually placed ectopic mandibular third molar: case report and discussion of management. *Oral Surgery* 5: 155-157.
- Keros J, Susic M (1997) Heterotopia of the mandibular third molar: A case report. *Quintessence Int* 28: 753-754.

20. Shivashankara C, Manjunatha B, Tanveer A (2011) Ectopic mandibular third molar in subcondylar region: Report of a rare case. *Oral and Maxillofacial Surgery* 16: 153-155.
21. Fernandez M, Terrones Meraz M (1992) Infected cyst in the coronoid process. *Oral Surgery, Oral Medicine, Oral Pathology* 73: 768.
22. Bux P, Lisco V (1994) Ectopic third molar associated with a dentigerous cyst in the subcondylar region: Report of case. *Journal of Oral and Maxillofacial Surgery* 52: 630-632.
23. Pace C, Holt D, Payne M (2010) An unusual presentation of an ectopic third molar in the condylar region. *Australian Dental Journal* 55: 325-327.
24. Lambade P, Lambade D, Dolas RS, Virani N (2013) Ectopic mandibular third molar leading to osteomyelitis of condyle: a case report with literature review. *Oral Maxillofac Surg* 17: 127-130.
25. Diana C, Bodh R, Sharma P, Verma A (2019) High lingual split access osteotomy for ectopic third molar in mandibular ramus region - A case report and literature review. *J Oral Biol Craniofac Res* 9: 187-189.
26. Okuyama K, Sakamoto Y, Naruse T, Kawakita A, Yanamoto S, et al. (2017) Intraoral extraction of an ectopic mandibular third molar detected in the subcondylar region without a pathological cause: A case report and literature review. *Cranio* 35: 327-331.
27. Ahmed N, Speculand B (2012) Removal of ectopic mandibular third molar teeth: Literature review and a report of three cases. *Oral Surgery* 5: 39-44.
28. Kansy K, Gander E, Staff C, Hoffmann J, Freier K (2014) Migration potential of lower third molars. *Oral Surgery* 7: 27-32.
29. Apaydin A, Salahattin M (2015) Ectopic Third Molar in Mandibular Ramus: Report of Two Cases and Literature Review. *Int J Oral Dent Health* 1: 007.
30. Salmerón JI, del Amo A, Plasencia J, Pujol R, Vila CN (2008) Ectopic third molar in condylar region. *Int J Oral Maxillofac Surg* 37: 398-400.
31. Scott N, Bater A, Wilson A (2012) An unusual cause of a facial swelling. *Journal of Surgical Case Reports* 2012: 10-10.
32. Findik Y, Baykul T (2015) Ectopic third molar in the mandibular sigmoid notch: Report of a case and literature review. *Journal of Clinical and Experimental Dentistry* 7: e133-e137.
33. Iglesias-Martin F, Infante-Cossio P, Torres-Carranza E, Prats-Golczer V, Garcia-Perla-Garcia A (2012) Ectopic third molar in the mandibular condyle: A review of the literature. *Medicina Oral Patología Oral y Cirugía Bucal* 17: e1013-e1017.
34. Nasseh I, Moussa S, Sokhn S (2015) Unusual Behavior of the Mandibular Canal Associated to a Dentigerous Cyst. *Journal of Dental Health, Oral Disorders and Therapy* 2.
35. Aristotelous C, Ryatt M, Majumdar A (2020) Migrating third molar. *British Dental Journal* 228: 228-228.