



## Association between Syncope and Myocardial Bridge

Lins TCB<sup>1\*</sup>, Valente LM<sup>2</sup>, Oliveira KTMN<sup>3</sup> and Brandão SCS<sup>4</sup>

<sup>1</sup>Department of Cardiology, Agamenon Magalhães Hospital (HAM), Brazil

<sup>2</sup>Department of Nephrology, Pernambuco Federal University (UFPE), Brazil

<sup>3</sup>Master's Course of Health Sciences, University of Pernambuco (UPE), Brazil

<sup>4</sup>Clinical Medicine Department and Health Sciences Post Graduation Course, Pernambuco Federal University (UFPE), Brazil

\*Corresponding author: Lins TCB, Department of Cardiology, Agamenon Magalhães Hospital (HAM), Recife, Brazil, E-mail: [tereza.lins@gmail.com](mailto:tereza.lins@gmail.com)

### Abstract

Myocardial bridge is a cause of sudden death in athletes, but syncope is somewhat related to this disease symptom. This paper reports a case of a young athlete, swimming practitioner with syncopal episodes related to physical exertion.

### Keywords

Myocardial bridge, Syncope, Athlete

repeated during a second exercise test performed 12 months later, when he also showed transient loss of consciousness, recovering after spending a few minutes in the supine position. During moderate-intensity aerobic activity, he presented with clammy skin and arterial hypotension was reported during resistance exercises of the upper limbs (thread-biceps). The diagnostic investigation continued suspicion of non-atherosclerotic coronary disease, such as anomalous coronary arteries. He underwent a computed tomographic coronary

### Introduction

Myocardial bridge (MB) is a congenital anomaly, described in 1737 by Reiman [1], characterized by intramyocardial tunneling of a segment of the epicardial coronary artery, which is compressed by surrounding myocardial fibers during systole [2]. It affects the Anterior Descending Artery (LAD) in roughly 67% to 98% of the cases [3].

The prevalence of MB is low, when the patients are assessed by coronary angiography, but when the assessment is done through Multiple-slice computed tomography (MSCT), the prevalence ranges from 15% to 50%, both in the general population and in special groups such as hypertrophic cardiomyopathy patients [4,5] or those diagnosed with left ventricular hypertrophy [5]. In sports medicine, myocardial bridge is recognized as a major cause of sudden death in young athletes [6].

We report a case of a young adult, swimming athlete, with syncopal episodes related to stress.

### Case Report

Male athlete, 23 years old, swimming practitioner in competitive level, with history of faint feeling in the final stages of the competition, followed by syncope after the race.

The episode was repeated six months later, when he returned to compete. While in diagnostic investigation, during conventional exercise testing, he presents an abrupt blood pressure drop in the recovery phase, without associated ECG changes. This was all

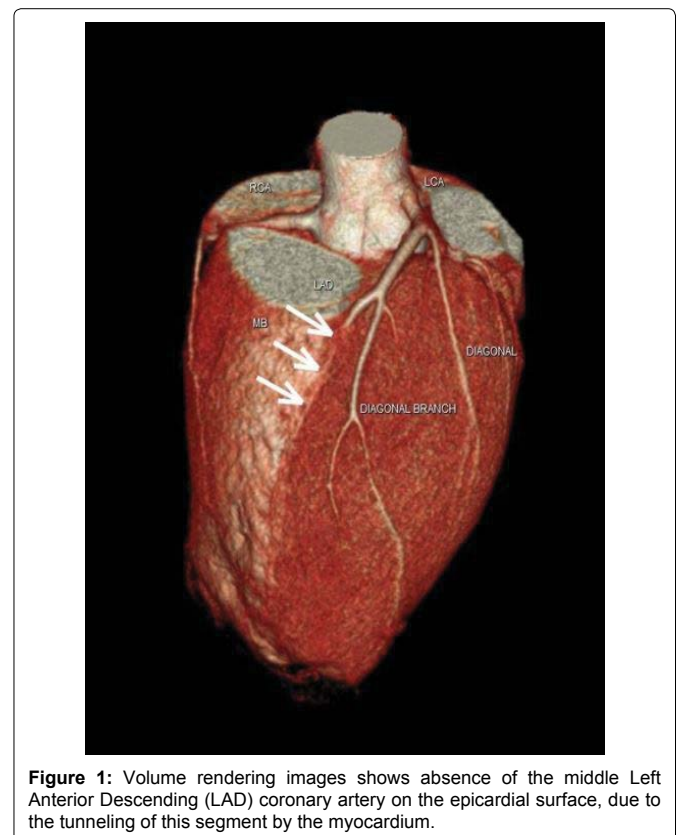
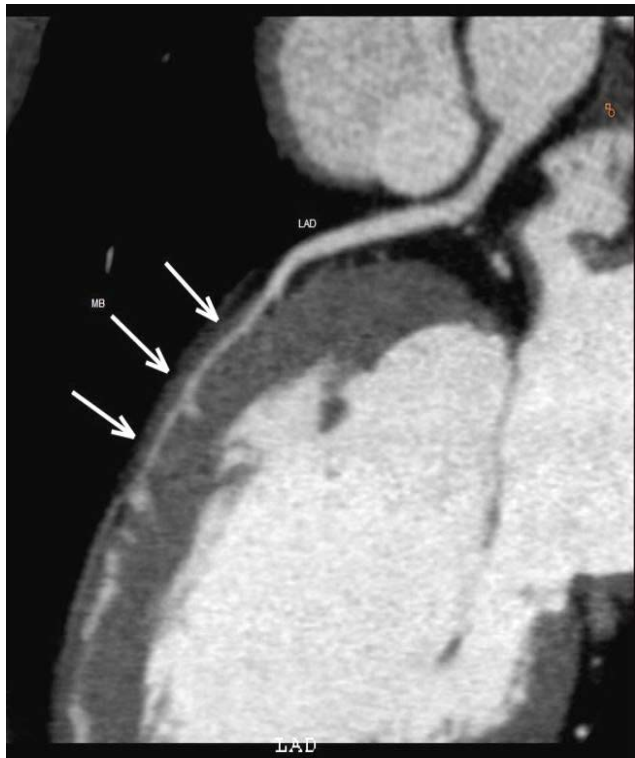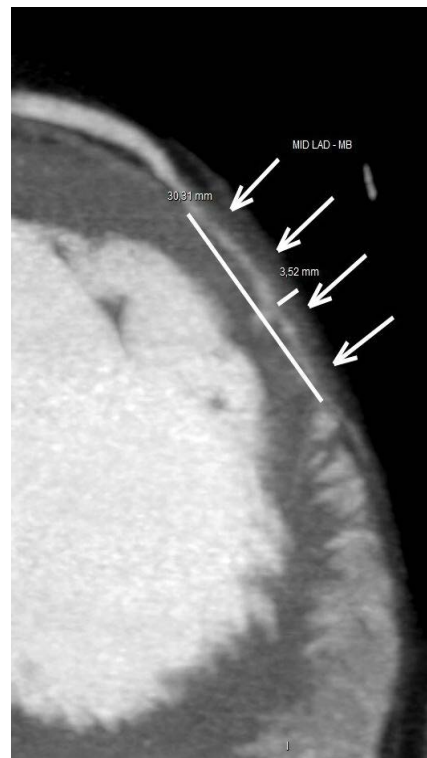


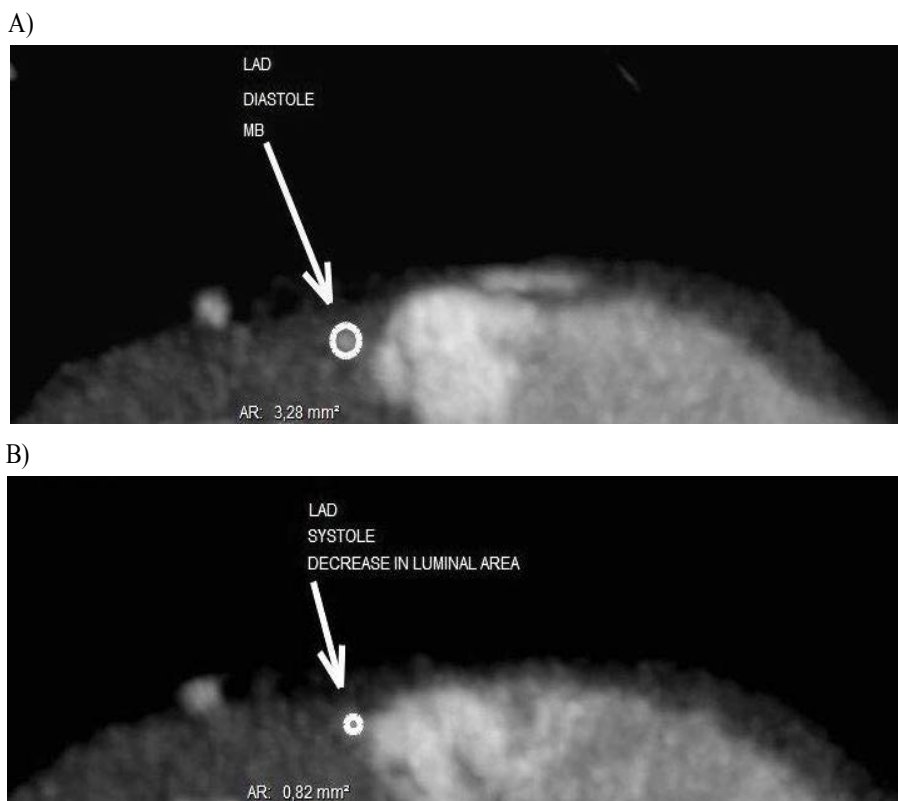
Figure 1: Volume rendering images shows absence of the middle Left Anterior Descending (LAD) coronary artery on the epicardial surface, due to the tunneling of this segment by the myocardium.



**Figure 2:** Left Anterior Descending Artery (LAD) completely surrounded by myocardium bridge (MB) on long axis multiplanar reformed image.



**Figure 3:** Maximum intensity projection image showing tunneled portion of mid Left Anterior Descending Artery (LAD).



**Figure 4:** Multiple-slice computed tomography (MSCT) images show short-axis plane during Diastole (A) and Systole (B). We observe a significant decrease in middle Left Anterior Descending (LAD) lumen area in systolic acquisition (B).

angiography, which revealed the myocardial bridge in the middle Left Anterior Descending coronary artery (Figure 1), for a length of approximately 30mm and depth of about 3.5 mm (Figures 2,3), with signs of significant reduction of systolic lumen (Figure 4A,4B). The patient was treated with beta-blocker, besides the detraining for 6 months, with regression of symptoms.

## Discussion

Myocardial bridging patients are usually asymptomatic, but this congenital anomaly may be associated with effort angina, ventricular arrhythmias, acute coronary syndromes, complete AV block, syncope or eventually sudden death [7]. However syncope is an infrequent

symptom, Ural and collaborators (2009) [8] found a prevalence of 5% of individuals with MB and severe systolic compression of the Left Anterior Descending coronary artery in a prospective cohort. In addition, Erdogan (2012) [9], on case studies reported the presence of syncope in adult patients with atrioventricular (AV) block and MB promoting severe stenosis in the LAD.

The hemodynamic impact on the coronary luminal flow depends on the contractile force of the bridge, the thickness and length, and orientation of the myocardial fibers, the connective and adipose tissues around the coronary artery [7]. In this case, an explanation of syncope could be based on Frank Starling's law. As a high performance athlete, with a greater venous return, he would acquire a greater end-diastolic volume, which would result in a greater stretch of myocardial fibers and myocardial contraction, consequently, a higher mechanical systolic pressure over the bridge would be expected. This would promote a longer occlusion of the tunneled segment, leading to a disproportion between the time of relaxation and ventricular contraction, reducing cardiac output. Consequently, the low cardiac output would cause low cerebral blood flow leading to syncope [10]. In this case, the bridge seems to alter the luminal blood flow, as it speeds in early diastole and abruptly slows after mid diastole, phenomenon known as "fingertip" as the result of secondary lower distal coronary resistance, which leads to the imbalance between oxygen supply and demand [2]. Moreover, the tachycardia caused by exercise also contributes to this phenomenon [6]. This explains the sudden income drop at the end of the race and the regression of symptoms after detraining. Finally, another less plausible explanation would be a total AV block secondary to a sub-vagal [2] reaction vessel. In this case, while in diagnostic investigation, electrocardiographic changes were not detected, making it difficult to justify this last hypothesis.

The diagnostic investigation with conventional coronary angiography, underestimates the prevalence of MB with minimal systolic compression is overlooked. However, with the use of intravascular ultrasound (IVUS) and intracoronary pressure devices, morphological and functional features of myocardial bridging can be visualized and quantified [11].

Multiple-slice computed tomography (MSCT) is an ideal technique because it enables visualization of the coronary artery lumens as well as the artery walls and the neighboring myocardium [12,13]. Stress single-photon emission computed tomography can detect reversible myocardial perfusion defects in patients with myocardial bridging and relate the amount of ischemia to the degree of systolic luminal narrowing [7].

Among the drugs used, the beta-blocker has an important role, by reducing heart rate promoting increased ventricular relaxation time and decreasing systolic compression of the coronary artery. Calcium channel blockers are frequently used also contraindication to the use of beta-blockers or when there is suspicion of vasospasm. The patient was treated with Metoprolol 25mg/daily, since this drug is cardioselective and promotes less adverse effects.

Myotomy or CABG may be the treatment of choice for patients who have symptomatic myocardial bridging refractory to medical therapy, 75% systolic coronary compression on angiography, or evidence of myocardial ischemia or infarction [14].

Prognosis in patients with isolated myocardial bridging is generally good [15].

Retrospective study of cases of sudden death in sport activity, myocardial bridge was the cause of death in some cases. Pereira et al. found a prevalence of 3% mortality related to myocardial bridge. In the long run there is insufficient data, obtained from a large group of symptomatic patients for definitive conclusions [16].

## Conclusion

Myocardial bridge subjected to vigorous compression during ventricular systole promoted by intense exercise can cause life-threatening symptoms and therefore athletes with myocardial bridge

should be suspended from competition. This case, along with other previous reports, suggests that syncope associated with the effort may be secondary to myocardial bridging.

## References

1. Reyman HC (1737) *Disertatio de vasis cordis propriis* [dissertation]. Göttingen: Med Diss Univ: 1-32.
2. Möhlenkamp S, Hort W, Ge J, Erbel R (2002) Update on myocardial bridging. *Circulation* 106: 2616-2622.
3. Qian JY, Zhang F, Dong M, Ma JY, Ge L, et al. (2009) Prevalence and characteristics of myocardial bridging in coronary angiogram—data from consecutive 5525 patients. *Chin Med J (Engl)* 122: 632-635.
4. Achrafi H (1992) Hypertrophic cardiomyopathy and myocardial bridging. *Int J Cardiol* 37: 111-112.
5. Sharma J, Hellenbrand W, Kleinman C, Mosca R (2011) Symptomatic myocardial bridges in children: a case report with review of literature. *Cardiol Young* 21: 490-494.
6. Yukio I, Yoko K, Ehiichi K, Toshiharu I (2009) (1) coronary events caused by myocardial bridge. *Ann Vasc Dis* 2: 79-94.
7. Corban MT, Hung OY, Eshtehardi P, Rasoul-Arzrumly E, McDaniel M, et al. (2014) Myocardial bridging: contemporary understanding of pathophysiology with implications for diagnostic and therapeutic strategies. *J Am Coll Cardiol* 63: 2346-2355.
8. Ural E, Bildirici U, Celikyurt U, Kilic T, Sahin T, et al. (2009) Long-term prognosis of non-interventionally followed patients with isolated myocardial bridge and severe systolic compression of the left anterior descending coronary artery. *Clin Cardiol* 32: 454-457.
9. Erdogan HI, Gul EE, Gok H (2012) Relationship between myocardial bridges and arrhythmic complications. *J Invasive Cardiol* 24: E300-302.
10. Brignole M (2007) Diagnosis and treatment of syncope. *Heart* 93: 130-136.
11. Ge J, Jeremias A, Rupp A, Abels M, Baumgart D, et al. (1999) New signs characteristic of myocardial bridging demonstrated by intracoronary ultrasound and Doppler. *Eur Heart J* 20: 1707-1716.
12. Vernuccio F, Fazio G, Lo Re G, Grutta G, Insalaco A, et al. (2013) Diagnosis, prognosis and treatment of "myocardial bridging": state of the art and unresolved issues. *Recenti Prog Med* 104: 493-497.
13. de Agustín JA, Marcos-Alberca P, Gómez de Diego JJ, Pérez de Isla L2 (2013) Importance of definition and technique when using noninvasive coronary angiography to diagnose myocardial bridging. *Response. Rev Esp Cardiol (Engl Ed)* 66: 325.
14. Wu QY, Xu ZH (2007) Surgical treatment of myocardial bridging: report of 31 cases. *Chin Med J (Engl)* 120: 1689-1693.
15. Lozano I, Baz JA, López Palop R, Pinar E, Picó F, et al. (2002) Long-term prognosis of patients with myocardial bridge and angiographic milking of the left anterior descending coronary artery. *Rev Esp Cardiol* 55: 359-364.
16. Pereira AB, Castro DS, Menegotto ET, Amaral WM, Castro GS (2010) Myocardial bridging: therapeutic and clinical development. *Arq Bras Cardiol* 94: 175-18, 188-94, 178-84.