



CASE REPORT

Middle Aortic Syndrome Presented in Pregnancy-Treated with Percutaneous Intervention Followed by Successful Management of the Complications

Jayakrishna Niari^{1*}, Avinash A Gutte², Nagesh Waghmare¹, Kalyan S Munde¹, Samkit Mutha¹ and Hariom Kolapkar¹

¹Department of Cardiology, Grant Govt. Medical College and Sir JJ Group of Hospitals, Mumbai, India

²Department of Radiology, Grant Govt. Medical College and Sir JJ Group of Hospitals, Mumbai, India

*Corresponding author: Jayakrishna Niari, Senior Resident, Department of Cardiology, Grant Govt. Medical College and Sir JJ Group of Hospitals, Room no 538, 300 Resident Hostel, Mumbai, Maharashtra-400008, India, Tel: 9776147192



Abstract

Introduction: Mid-aortic syndrome is a clinical condition characterized by segmental narrowing of the abdominal or descending thoracic aorta, often resulting in severe hypertension. It can manifest as either a congenital abnormality or as one of several acquired conditions. Given the limited evidence available on the treatment of this syndrome, various approaches have been reported, including surgical intervention and endovascular treatments such as stent placement and medical management alone.

Case presentation: We present the case of a 21-year-old female who developed life-threatening hypertension during the 21st week of pregnancy, a condition that went unrecognized before gestation due to the rarity of this syndrome. Unfortunately, in our patient, arterial hypertension proved resistant to a 4-drug antihypertensive regimen and there is evidence of end organ damage and fetal compromise. However following termination of pregnancy, a successful endovascular repair of mid-aortic syndrome was achieved using a self-expanding stent, along with bilateral renal artery stenting. Following the procedure, patient developed haemorrhagic stroke which was managed successfully and patient discharged in a stable condition.

Conclusion: Patient is doing well for the last 11 months. Mid-aortic syndrome presented in pregnancy can be successfully managed with percutaneous intervention.

Keywords

Mid-aortic syndrome, Pregnancy, Percutaneous intervention

Abbreviations

G1P1L0: Gravida One, Para One, Live Zero; MTP: Medical Termination of Pregnancy; CT: Computed Tomography; USG: Ultrasonography; ESR: Erythrocyte Sedimentation Rate; CRP: C-Reactive Protein; ANA: Antinuclear Antibody; SMA: Superior Mesenteric Artery; IMA: Inferior Mesenteric Artery; CoA: Coarctation of Aorta; GA: Gestational Age

Introduction

Mid-aortic syndrome is a rare vascular abnormality that often leads to life-threatening arterial hypertension. It may result from a congenital abnormality in aorta development or be associated with acquired conditions such as infection, Takayasu arteritis, neurofibromatosis, obliterative panarteritis, retroperitoneal fibrosis, fibromuscular dysplasia and mucopolysaccharidosis [1]. Arterial hypertension associated with mid-aortic syndrome typically proves resistant to all classes of antihypertensive medications. In some cases, underlying causes of preexisting hypertension may only become apparent during pregnancy. Furthermore, females with aortic coarctation planning pregnancy should undergo repair before conception to minimize risks such as aortic dissection, aneurysm rupture, or stroke during pregnancy [1,2]. Although the risk of these complications is low, maternal mortality significantly

rises if they occur. To our knowledge, only a few cases of mid-aortic syndrome repair during pregnancy have been described to date and no cases of complication following percutaneous repair has been reported although these patients are prone to complications because of peculiar nature of physiological changes in pregnancy associated with CoA. Here, we present a case involving endovascular treatment with self-expanding stents after termination of pregnancy, followed by bilateral renal artery stenting due to uncontrollable hypertension. The patient experienced a haemorrhagic stroke just after the procedure, which was successfully managed and patient discharged in an ambulatory condition.

Case Presentation

A 21-year-old female, G1P1L0, married for 2 years, presents at 21 weeks of gestation with a history of uncontrolled hypertension, headaches, lower limb claudication, and dyspnea on exertion over the last month. Upon examination, the pulse rate is 82/min in both upper limbs, with feeble pulses in the lower limbs. Radio-femoral delay is present. The blood pressure in the right upper limb measures 220/140 mmHg, while in the left upper limb, it is 210/140 mmHg. The lower limb pressure is unrecordable by the cuff measurements. Fundus - Grade IV hypertensive retinopathy, 2D ECHO - Severe concentric left ventricular hypertrophy, EF 60%. The abdominal aortic flow was compatible with coarctation, showing severe narrowing of the abdominal aorta with a gradient of 107 mmHg. ESR, CRP and ANA profile were negative (ruling out Takayasu's Arteritis and connective tissue disorders). Serum creatinine- 1.4 mg/dL. USG abdomen revealed a single live intrauterine gestation, cephalic, GA 21 weeks, with features of mild intrauterine growth restriction and severe narrowing of the middle segment of the abdominal aorta.

The patient was initiated on Tab. Labetolol 200 mgbd and Tab. Nifedipine 20 mgtds. However, her blood pressure remained uncontrolled. Tab. Prazosin 5 mg tds and Moxonidine 0.2 mgod were added. Despite being on four antihypertensives (Nicardipine + Labetalol + Prazosin + Moxonidine), the patient continued to be hypertensive (> 190/110 mmHg). The options of Medical Termination of Pregnancy (MTP) followed by aortoplasty versus continuation of pregnancy and aortoplasty were discussed with the patient and family, outlining the risks and benefits. They opted for MTP followed by aortoplasty.

Post MTP, the USG showed no evidence of retained products of conception. A CT Aortogram revealed a short segment of significant luminal narrowing (3.7 cm) in the suprarenal segment of the descending aorta, complete 100% occlusion (length 3.9 cm) in the infrarenal abdominal aorta, suggestive of Mid Aortic Syndrome. Prominent mesenteric and abdominal collaterals were noted, SMA, IMA and bilateral renal arteries were normal (Figure 1).

The procedure, performed under local anesthesia, involved a right femoral artery puncture. Heparin (100 IU/kg) was administered intravenously. A headhunter catheter was passed through the right femoral artery, revealing a distal flap in the infrarenal part, causing confusion regarding true or false lumen (Figure 2). To clarify, a left brachial artery access was taken, confirming the true lumen. The catheter was advanced, confirming total cutoff in the infra-renal aorta (Figure 3). Further, a terumo 0.035 wire was passed through the catheter and snared out through the right femoral artery access, and a multi-marker pigtail catheter was passed over it.

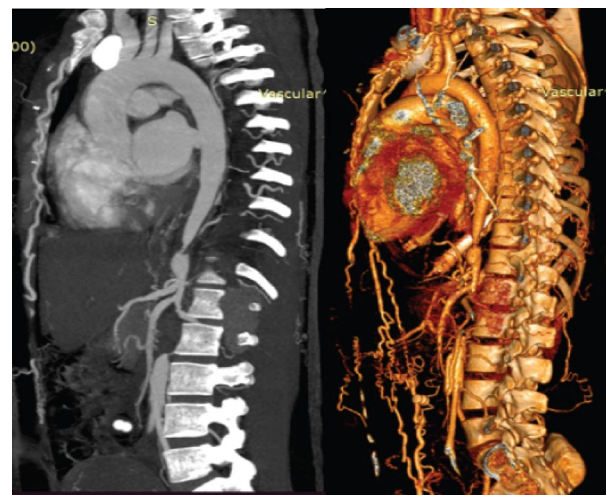


Figure 1: Left side image- CT Aortogram showing short segment of significant luminal narrowing (3.7 cm) in the suprarenal segment of the descending aorta, complete 100% occlusion (length 3.9 cm) in the infrarenal abdominal aorta; Right side image- 3D reconstruction image of the same findings.

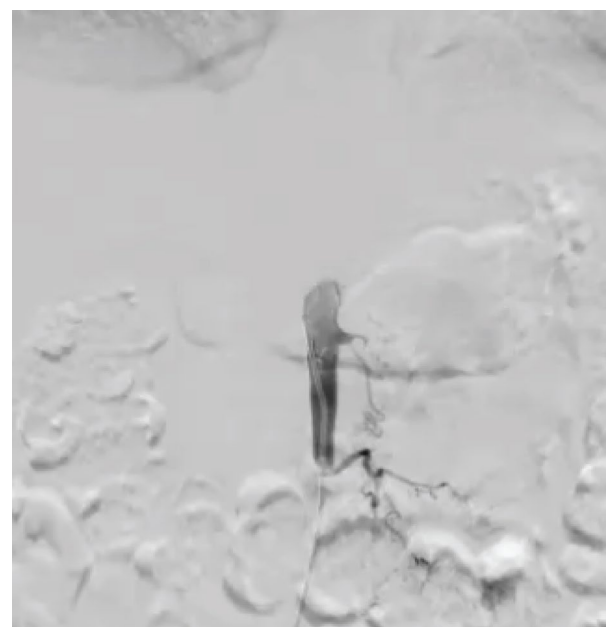

Figure 2: Headhunter catheter passed through the right femoral artery access, revealing a distal flap in the infrarenal part, causing confusion regarding true or false lumen.

A check shoot by pigtail shows similar findings as the CT aortogram. The lesion in the aorta was sequentially balloon-dilated with Cordis POWERFLEX PRO 12 mm × 6 cm balloon. Post-balloon dilatation check shoot shows improved distal flow. The suprarenal segment was stented with the Cordis SMART CONTROL NITINOL stent 14 mm × 60 mm, and the infrarenal segment was

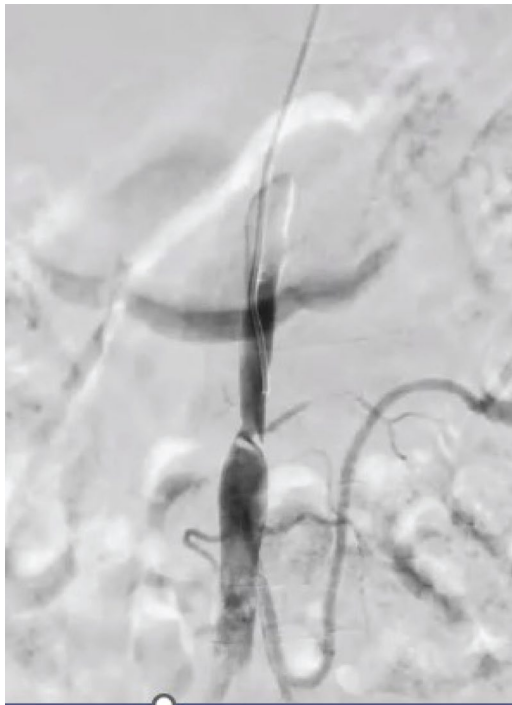


Figure 3: Showing Catheter through left brachial artery access confirming the true lumen and total cut-off in the infra-renal aorta.

stented with the SMART CONTROL STENT 12 mm × 80 mm, with around 10 mm overlapping with the first stent (Figure 4-left image). The post-stent angiogram reveals good flow across the aorta with improved distal circulation with slow flow in right renal artery which we thought would improve by anticoagulation (Figure 4-right image). Five days after aortic angioplasty, the patient complained of persistent abdominal pain, and hypertension persisted. So, we decided to conduct a repeat CT Aortogram. The repeat CT Aortogram revealed a patent stent with good flow, and the celiac, SMA, IMA, bilateral common, external, and internal iliac were normal. There was a critical stenosis (> 80% ostial stenosis) in the left renal artery and right renal artery total cut off from ostium (Figure 5). Consequently, we proceeded with PTR. A check shoot with a sim catheter showed similar finding as of CT Aortogram. A 0.014 wire was crossed, and the right renal artery ostium was dilated using a 4.5 × 20 mm PIPIT balloon. The right renal artery was stented with a RENOFIT 5 × 15 mm stent. The left renal artery was stented with a RENOFIT 6 × 15 mm stent. Post-angioplasty revealed bilateral good-caliber renal arteries with good flow (Figure 6). Thirty minutes after the procedure, the patient developed right hemiparesis. On examination, the patient was conscious, oriented, with power of 2/5 in both upper limbs and lower limbs. NCCT showed left ganglio-capsular intraparenchymal bleed, which was managed conservatively. Post-renal stenting, the patient's abdominal pain diminished and blood pressure significantly came down. After 10 days, the patient was discharged with power of 4/5 in both upper and lower

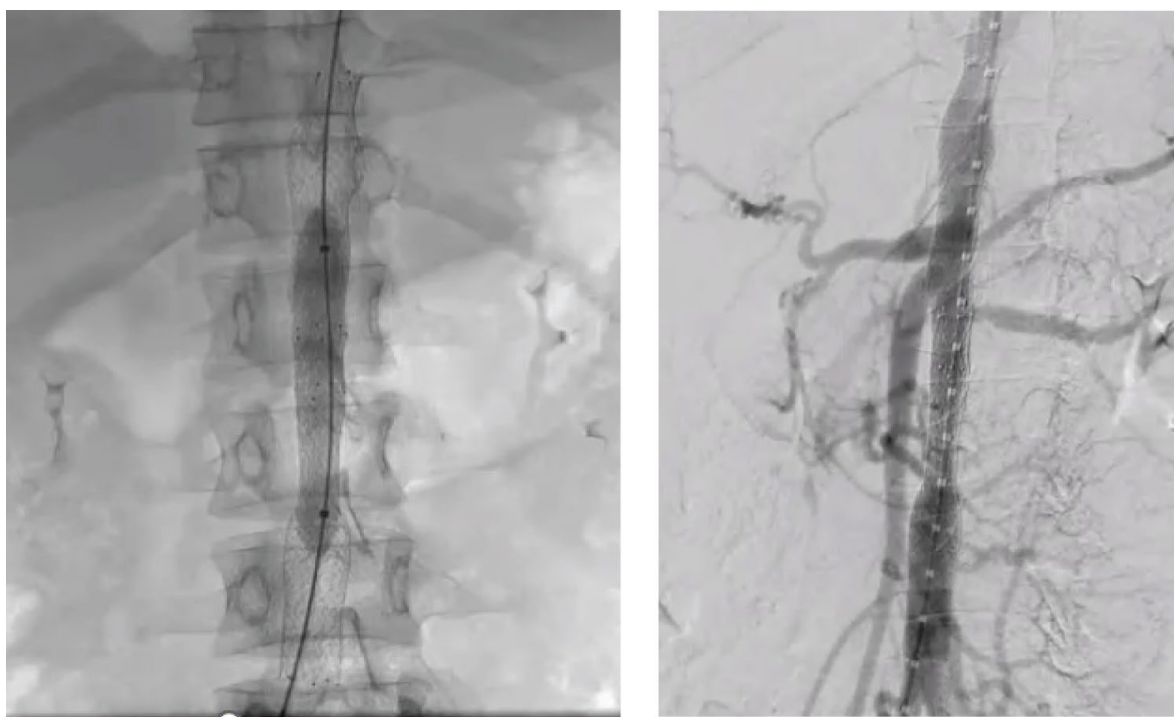


Figure 4: Left side- Suprarenal segment was stented with the Cordis SMART CONTROL NITINOL stent 14 mm × 60 mm, and the infrarenal segment were stented with the SMART CONTROL STENT 12 mm × 80 mm, with around 10 mm overlapping with the first stent; **Right side image-** Post-stenting angiogram reveals good flow across the aorta with improved distal circulation.

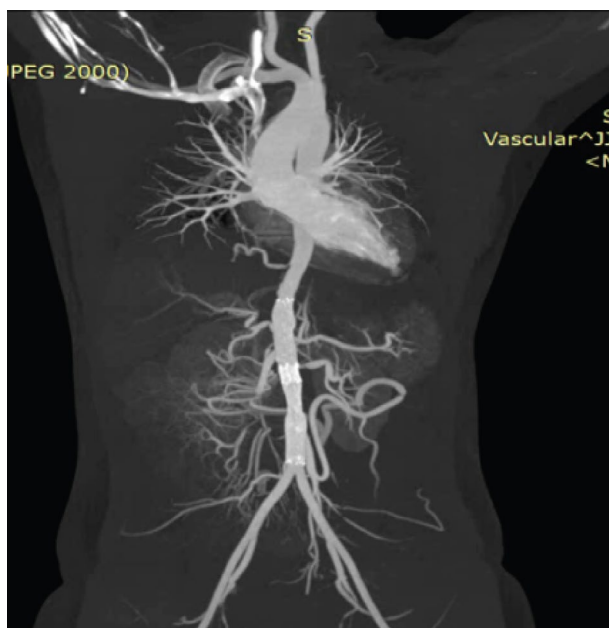


Figure 5: Repeat CT Aortogram revealed a patent stent with good flow, and the celiac, SMA, IMA, bilateral common, external, and internal iliac were normal. There was a critical stenosis (> 80% ostial stenosis) in the left renal artery and right renal artery total cut off from ostium.

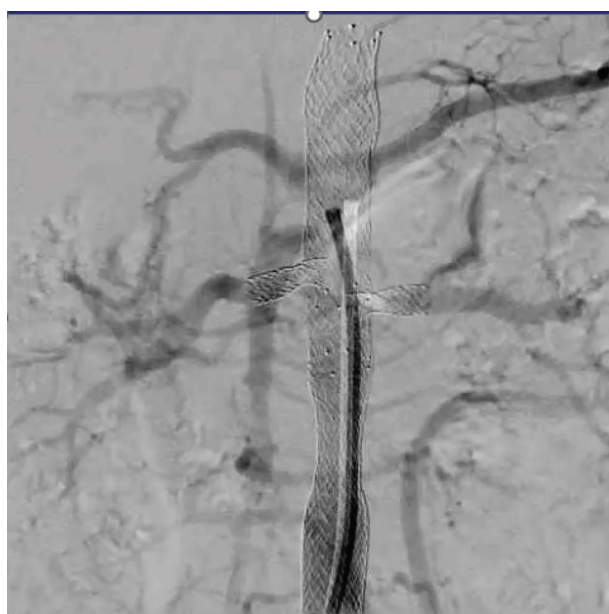

Figure 6: Post- B/L renal angioplasty revealed bilateral good-caliber renal arteries with good flow.

limbs in an ambulatory condition. Hypertension was well controlled with only amlodipine 5 mg. The patient has been doing well for the last 11 months with a single antiplatelet agent.

Discussion

The mid-aortic syndrome poses a life-threatening risk due to potential complications arising from upper limb arterial hypertension. Diagnosis during pregnancy is rare, with only few reported cases [3-7]. Secondary hypertension in pregnancy occurs in 5 to 10% of cases

and should be considered when drug resistance is observed [5,8]. Treatment becomes imperative when blood pressure exceeds 170/90 mmHg [9]. However, aggressive hypertension treatment in patients with aortic coarctation should be approached cautiously to prevent placental hypoperfusion [2]. It is important to note that all antihypertensive drugs are presumed to cross the placenta and reach fetal circulation. Although routine antihypertensive agents are not documented to be teratogenic, ACE inhibitors and ARBs are considered fetotoxic and should be avoided in pregnant women [9]. In our case, we initiated treatment with labetalol and nifedipine, later incorporated prazosin and moxonidine. Various treatment strategies are employed based on the experience of the medical unit in managing mid-aortic syndrome [10]. Surgery is widely accepted, particularly in older patients and cases of complex mid-aortic syndrome associated with renal and visceral arterial stenosis [11,12]. Surgical options may include thoracoabdominal to infrarenal aortic bypass with renal artery reimplantation, splenorenal bypass, aortorenal bypass, and auto-transplantation. Over the past decade, experience has demonstrated that percutaneous techniques, such as balloon angioplasty or stent implantation, can effectively treat this pathology, depending on the patient's anatomy and age [1,13,14]. While there are sporadic cases of mid-aortic syndrome diagnosed during pregnancy successfully managed with medication alone [3,4,15,16], percutaneous intervention for undiagnosed coarctation is feasible during pregnancy. However, it is associated with a higher risk of aortic dissection than outside pregnancy and should only be considered if severe hypertension persists despite maximal medical therapy, and there is maternal or fetal compromise [2,17]. In this case, the patient is refractory to four antihypertensives, and there is evidence of end-organ damage and fetal compromise. Therefore, we decided to manage it with percutaneous intervention. Pregnant patients with unrepaired CoA are classified as modified World Health Organisation (mWHO) IV, indicating a high risk of maternal mortality and morbidity, contraindicating pregnancy [4].

Pregnant patients with CoA undergo significant pregnancy-related cardiovascular changes, adding stress to coarctation physiology and making them more susceptible to complications such as hypertensive crisis, aortic dissection, aortic rupture, cerebrovascular accidents (both infarct and bleeding), and congestive cardiac failure during pregnancy [2]. Additionally, important fetal complications may arise, including intrauterine growth restriction and premature birth due to placental abruption or ischemia [2]. In this case, the patient is refractory to four antihypertensives, and there is evidence of end-organ damage and fetal compromise. Therefore, we decided to manage it with percutaneous intervention. However, whether to proceed with the

intervention while continuing the pregnancy or to offer the option of termination is a matter of debate.

The management of unrepaired Coarctation of the Aorta (CoA) during pregnancy is influenced by various factors, including the extent and characteristics of the coarctation. Due to a lack of data, decisions often rely on expert opinion and consensus. According to European guidelines on the management of cardiovascular diseases in pregnancy, termination should be discussed if there is a high risk of maternal morbidity or mortality and/or fetal abnormality [2,18].

In our patient's case, we offered the option of MTP because she remained severely hypertensive despite being on four antihypertensives, showing evidence of end-organ damage, and with signs of fetal compromise. This approach aimed to reduce the risks of maternal morbidity and mortality. This decision proved to be appropriate, as the patient underwent percutaneous intervention twice and experienced a life-threatening complication, which could have increased the chances of maternal mortality if the pregnancy had continued. As these patients are prone for having cerebral artery aneurysms, a CT brain angiogram or MRI brain angiogram should be done before proceeding with percutaneous intervention, to prevent cerebral complications during and after the procedure. Which we missed in our case because of lack of proper literature about this type of case. This case emphasizes that mid-aortic syndrome presented in pregnancy can be successfully and safely managed by percutaneous intervention with good assessment of the maternal and fetal condition and looking at the pros and cons of each procedure to be done.

Conclusion

Mid-aortic syndrome during pregnancy poses a significantly higher risk of maternal and fetal mortality, but it can be safely managed with percutaneous intervention. The decision of whether to proceed with intervention during the continuation of pregnancy or after abortion should be individualized based on the specific circumstances of each case. In situations where complications have already developed or there is evidence of fetal compromise, the option of MTP may be considered to reduce the chances of maternal morbidity and mortality during and after the procedure. A CT brain angiogram should be mandatory to detect any aneurysms of the cerebral arteries to prevent post-procedural cerebral complications. After the intervention, patients require close follow-up due to the high-risk nature of pregnancy and the increased chances of complications post-procedure. Any arising symptoms should prompt appropriate investigations and prompt management. Regular monitoring and timely intervention are crucial for optimizing outcomes in these cases. Since it is a very rare condition in pregnancy

and very few case reports has been published, we need a large number of case reports and follow ups to arrive at a consensus about best modalities treatment in this group of patients.

Consent

Patient consent for publication has been obtained by the authors.

Conflict of Interest

The authors declare no conflict of interest.

Funding

The research received no external funding.

Authors Contributions

This work was carried out in collaboration among all authors. All authors read and approved the final manuscript.

References

- Cherpak B, Davydova I, Ditkivskyy I, Yaschuk N, Batsak B, et al. (2016) A case of endovascular repair of mid-aortic syndrome diagnosed during pregnancy. *Perinatologiya I Pediatriya* 3: 10-14.
- Regitz-Zagrosek V, Roos-Hesselink JW, Bauersachs J, Blomström-Lundqvist C, Cifková R, et al. (2018) 2018 ESC Guidelines for the management of cardiovascular diseases during pregnancy. *Eur Heart J* 39: 3165-3241.
- Willner JB, Hatfield TJ, Hameed AB (2009) Successful pregnancy after aortic stent-graft in a patient with middle aortic syndrome. *Am J Obstet Gynecol* 200: e4-e5.
- Hajsadeghi Sh, Chitsazan M, Rahbar H (2010) Suprarenal abdominal aortic coarctation diagnosed during pregnancy. *Int Cardiovasc Res J* 4: e61911.
- Stone S, Beattie D, Jolly MC (2009) A case of congenital mid-aortic syndrome in pregnancy. *J Hum Hypertens* 23: 143-145.
- Shah NC (2008) A young hypertensive woman with a rare diagnosis of middle aortic syndrome. *J Clin Hypertens* 10: 795-798.
- Pandiyan NDP (2019) Middle aortic syndrome in pregnancy: A case report. *Univ J Surg Surg Spec* 5.
- Durgin JM, Slatnick BL, Vakili K, Kim HB, Cuenca AG (2021) Midaortic syndrome and renovascular hypertension. *Semin Pediatr Surg* 30: 151124.
- James PR, Nelson-Piercy C (2004) Management of hypertension before, during and after pregnancy. *Heart* 90: 1499-1504.
- Porras D, Stein DR, Ferguson MA, Chaudry G, Alomari A, et al. (2013) Midaortic syndrome: 30 years of experience with medical, endovascular and surgical management. *Pediatr Nephrol* 28: 2023-2033.
- Fink-Josephi G, Gutierrez-Vogel S, Hurtado-López LM, Calderón C (2008) Endovascular surgery by means of a Talent endoprosthesis implant in adult patients with thoracic aorta coarctation. *J Cardiovasc Surg* 49: 483-487.
- Rabenstein AP, Salhab KF, Spentzouris G, Paruchuri V, Hines G, et al. (2019) Middle aortic syndrome in a child-bearing age patient. *Aorta* 7: 87-89.

13. Sievrt H, Qureshi S, Wilson N, Hijazi ZM (2007) Percutaneous interventions for congenital heart disease. Informa UK Ltd.
14. Lazea C, Al-Khzouz C, Sufana C, Miclea D, Asavoai C, et al. (2022) Diagnosis and management of genetic causes of middle aortic syndrome in children: A comprehensive literature review. *Ther Clin Risk Manag* 18: 233-248.
15. Beauchesne LM, Connolly HM, Ammash NM, Warnes CA (2001) Coarctation of the aorta: Outcome of pregnancy. *J Am Coll Cardiol* 38: 1728-1733.
16. Chaudhary R, Tiwari T, Sharma R, Goyal S (2021) Midaortic syndrome in a middle-age female. *BMJ Case Rep* 14: e246530.
17. Zabal C, Attie F, Rosas M, Buendía-Hernández A, García-Montes JA (2003) The adult patient with native coarctation of the aorta: Balloon angioplasty or primary stenting? *Heart* 89: 77-83.
18. Nashat H, Patel R, Johnson MR, Rafiq I (2023) Percutaneous intervention of severe native coarctation of the aorta presenting in pregnancy: A case report. *Eur Heart J Case Rep* 7: yta079.