



# Successful Surgical Embolectomy for Acute Massive Pulmonary Embolism in Pregnant Woman

**Nobuhiko Hiraiwa\*, Kohei Abe, Kunihiko Yoshino, Manabu Yamasaki and Hiroyasu Misumi**

Department of cardiovascular surgery, St. Luke's International Hospital, Japan

\*Corresponding author: Nobuhiko Hiraiwa, MD, Department of cardiovascular surgery, St. Luke's International Hospital, 9-1 Akashi-cho, Chuo-ku, Tokyo, Japan, Tel: +81-3-3541-5151, Fax: +81-3-5550-7139, E-mail: [nobhiraiwa@gmail.com](mailto:nobhiraiwa@gmail.com)

### Abstract

A 28-year-old pregnant woman was admitted to our hospital with tonic seizure and dyspnea, and was diagnosed with acute massive pulmonary embolism. An emergency surgical embolectomy was performed under cardiopulmonary bypass (CPB). Several fragments of the thrombi were carefully removed from the right and the main pulmonary arteries, and sufficient back-flow from the pulmonary artery was established. The postoperative course was uneventful. After the embolectomy, the ratio of pulmonary to systemic arterial pressure (Pp/Ps) was decreased from 0.5 to 0.25. There were no complications including maternal or fetal loss and major bleeding complications. A Trans-abdominal ultrasound performed after the surgery revealed secure fetal heartbeat and no abnormality. The patient was discharged on subcutaneous injection therapy of unfractionated heparin (UFH). Surgical embolectomy is a good option even in critically diseased high-risk pregnant women.

### Keywords

Pulmonary embolism, Pregnant, Surgical embolectomy

Creatine kinase (CK) was 22 IU/L, CK-MB was less than 5 IU/L. Troponin T was almost normal value at 0.017 ng/ml. The plasma level of d-dimer was elevated at 18.4 µg/ml. An electrocardiogram showed sinus tachycardia with typical S1Q3T3 pattern. A trans-thoracic echocardiography (TTE) showed a dilated hypokinetic right ventricle with flattened interventricular septum, which indicates pulmonary hypertension. TTE revealed no patent foramen ovale (PFO). A brain computed tomography (CT) demonstrated no bleeding lesions or cerebral infarction. A contrast-enhanced CT showed a large pulmonary embolus in the left main pulmonary artery and an occlusion of the right segmental arteries (Figure 1 and Figure 2). There were no obvious findings that showed the primary source of embolus. We assessed acute massive PE induced unstable hemodynamics and her tonic seizure. Considering the hemodynamic instability and the possible risk of maternal major bleeding complications and fetal death in thrombolytic therapy, we selected an emergency surgical embolectomy. Only circulatory support with catecholamines was followed by immediate surgery, and extracorporeal membrane oxygenation or intra-aortic balloon pumping support was not necessary.

### Introduction

The incidence of venous thromboembolism (VTE) in pregnant women, derived from retrospective cohort studies, is estimated to be 5-12 events per 10000 pregnancies antenatally, seven to ten times higher than the incidence in age-matched controls [1].

Pulmonary embolism (PE) is the leading cause of maternal mortality in the developed world [2].

Treatment for massive PE during pregnancy is complicated and challenging. However there are no conclusive data regarding the optimal treatment for massive PE with pregnant women. We report a successful case of surgical embolectomy for acute massive PE in pregnant woman.

### Case Report

A 28-year-old female (body weight was 50 kg) presented with acute onset of tonic seizure in her 12 weeks of gestation. On clinical examination, she was dyspneic, cyanotic, hemodynamically unstable, hypotensive (systolic blood pressure 68 mmHg), and tachycardia (120 beats/min), with low oxygen saturation (60%) with Venturi mask (10 L/min). There was no elevation of cardiac biomarkers.

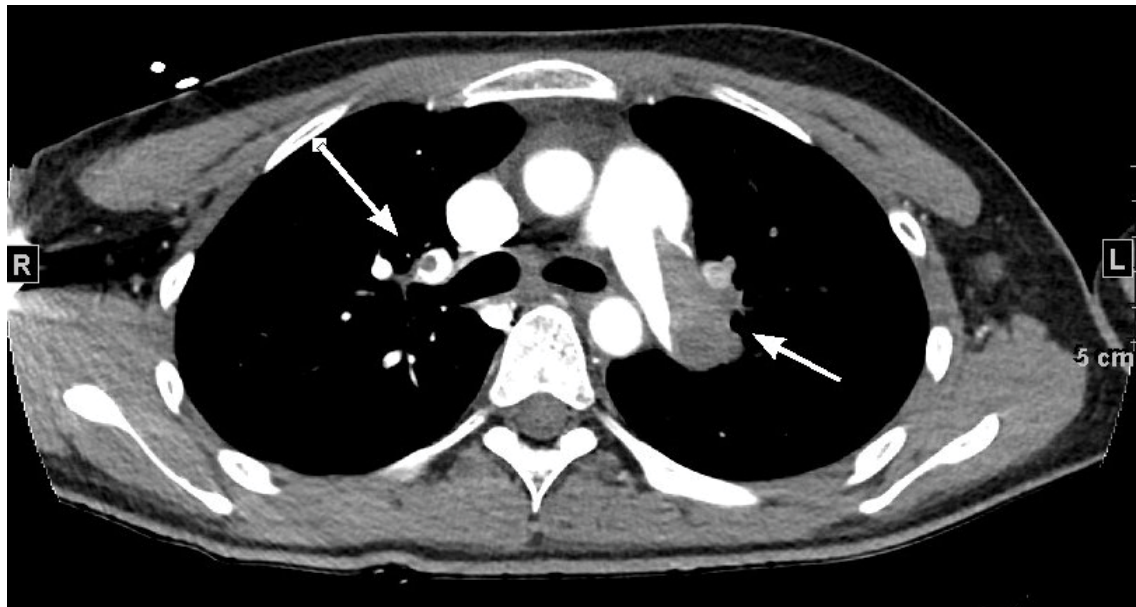
Median sternotomy was made. The right atrium and ventricle were found to be remarkably enlarged. After an arterial cannula was placed in the ascending aorta, and a venous cannula were placed in the right atrium, CPB was established with normothermia. Under beating heart (without aortic cross clamp), the right and the main pulmonary arteries were incised. Several fragments of the thrombus were carefully removed using a pair of forceps and external suckers (Figure 3), and sufficient back-flow from the pulmonary artery was ensured. After the closure of the pulmonary arteries, the CPB could be weaned without any difficulty. CPB time was 37 minutes. Protamine was given to reverse heparin, and hemostasis was confirmed. After embolectomy, the ratio of pulmonary to systemic arterial pressure (Pp/Ps) was decreased from 0.5 to 0.25.

She weaned from the respirator without any problems, and there were no maternal neurological, or major bleeding complications. Trans-abdominal ultrasound revealed secure fetal heartbeat and no abnormality. Because a venous duplex study of the lower extremity showed no evidence of deep venous thrombosis including the iliac veins, we didn't insert inferior vena cava filter. The patient was given subcutaneous injection of unfractionated heparin (UFH) (10000 units per 12 hours) to maintain the ratio of the activated

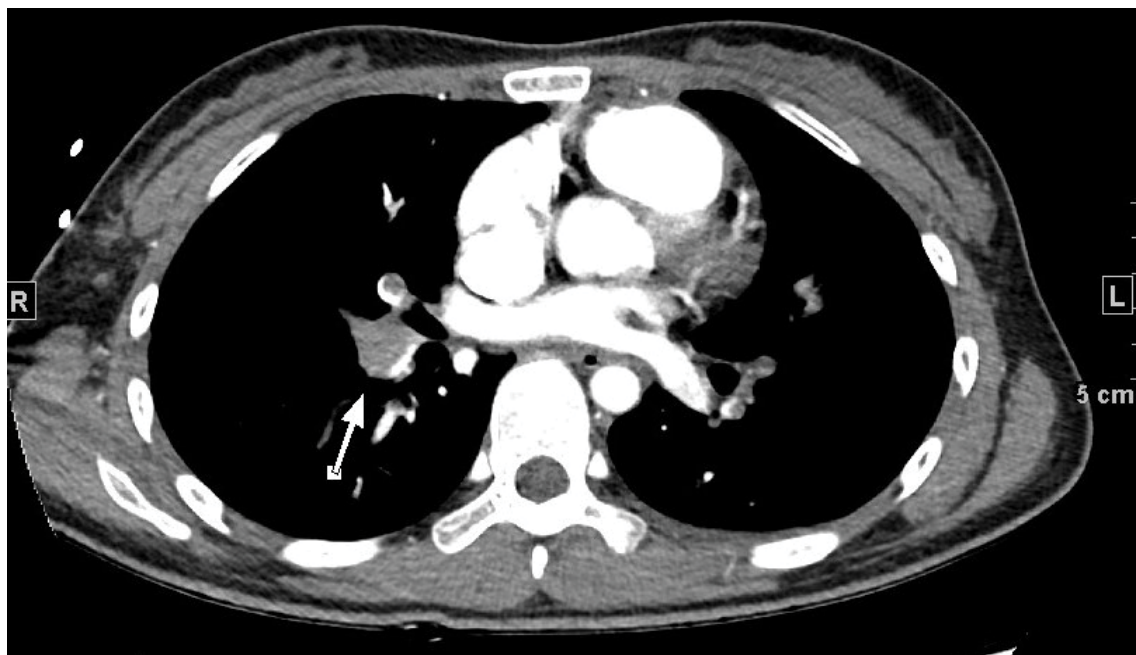
**Citation:** Hiraiwa N, Abe K, Yoshino K, Yamasaki M, Misumi H (2016) Successful Surgical Embolectomy for Acute Massive Pulmonary Embolism in Pregnant Woman. Int J Clin Cardiol 3:083

**Received:** June 26, 2016; **Accepted:** July 27, 2016; **Published:** July 30, 2016

**Copyright:** © 2016 Hiraiwa N, et al. This is an open-access article distributed under the terms of the Creative Commons Attribution License, which permits unrestricted use, distribution, and reproduction in any medium, provided the original author and source are credited.



**Figure 1:** A contrast-enhanced computed tomography showed a large pulmonary embolus in the left main pulmonary artery.



**Figure 2:** A contrast-enhanced computed tomography showed an occlusion of the right segmental arteries.

partial thromboplastin time (aPTT) between 1.5 and 2.0, and the postoperative course was without complications. She was discharged home under subcutaneous injection of UFH on postoperative day 11.

## Discussion

Pregnant women are exposed to an increased risk for developing PE, which are the leading cause of maternal mortality in the developed world and the third cause of maternal death in Japan.

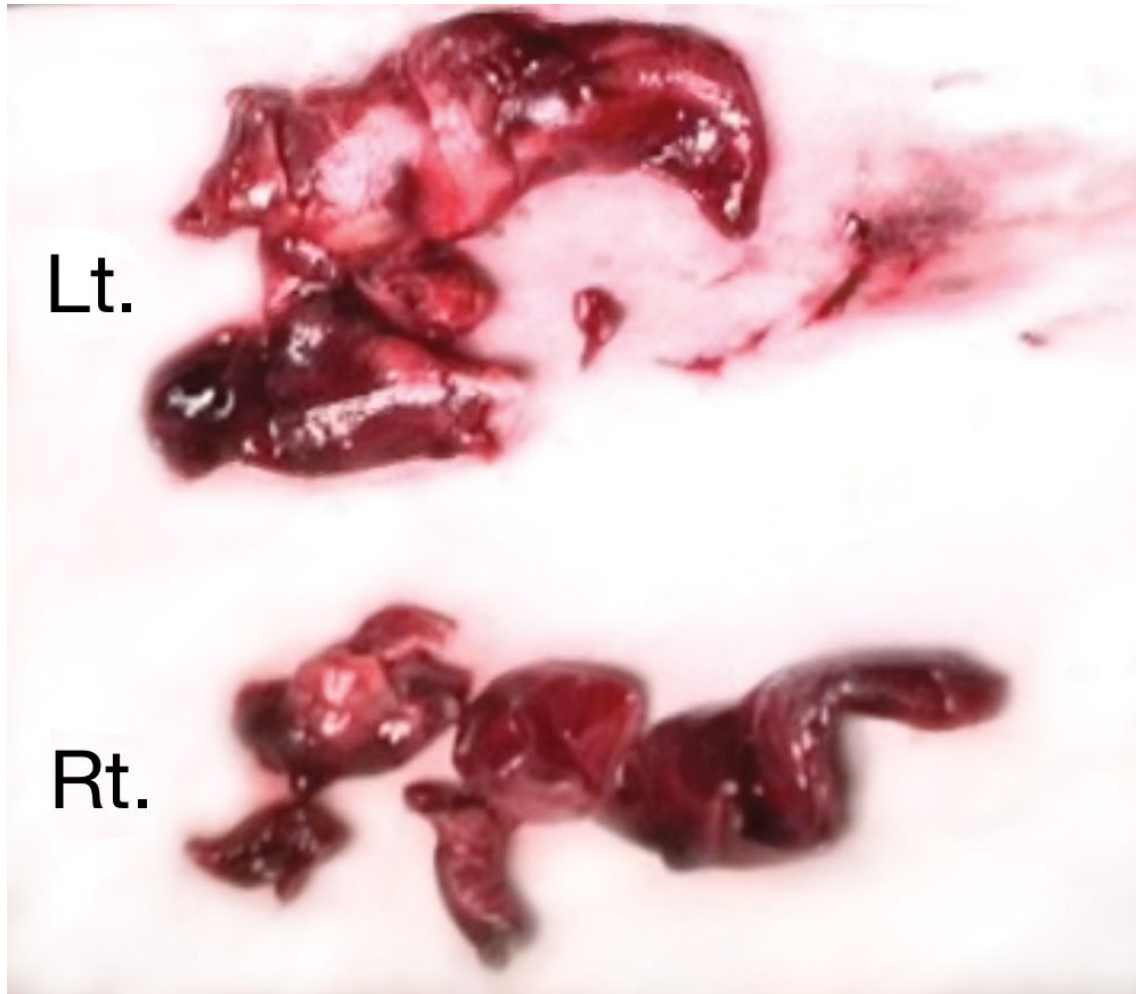The incidence of venous thromboembolism (VTE) in pregnant women, derived from retrospective cohort studies, is estimated to be 5-12 events per 10000 pregnancies antenatally (from conception to delivery), seven to ten times higher than the incidence in age-matched controls [1].

Thrombolytic therapy can be considered for the treatment of patients with massive PE, who are hemodynamically unstable and with refractory hypoxaemia or right ventricular dysfunction. Some thrombolytic agents like streptokinase, urokinase and recombinant

tissue plasminogen activator (rt-PA) are used. rt-PA, which is the most commonly used, is a large polypeptide (72 000 kd) that does not penetrate the placenta. Streptokinase is also a large molecule derived from group C streptococci that does not penetrate the placenta in sufficient amounts to cause fibrinolysis in the fetus. Urokinase is a small nonantigenic molecule purified from human urine that penetrates the placenta [3].

Raa and colleagues [4], in their literature review, reported 13 cases of thrombolytic therapy for pregnant patients with PE. There were no maternal deaths, four non-fatal major bleeding (30.8%; 95% CI [9.1-61.4]), two fetal deaths (15.4%; 95%CI [1.9-45.5]), and five preterm deliveries (38.5%; 95%CI [13.9-68.4]). Although the maternal survival rate of thrombolytic therapy is excellent, there are some disadvantages of maternal bleeding complications and fetal mortality.

Catheter-directed thrombolysis, either alone or with thromboembolic mechanical fragmentation, has potential advantages, such as more rapid



**Figure 3:** Several fragments of massive embolus which were removed from the left and the right pulmonary arteries.

clot lysis with consequent improvement in pulmonary blood flow, normalization of hemodynamic status, uterine perfusion, and lower risk of bleeding. However, there is no convincing evidence that catheter-directed thrombolytic therapy is superior to treatment with systemic thrombolytics or standard heparin [5]. The consequence of radiation exposure during pregnancy is also unknown.

Surgical embolectomy is indicated when conventional therapy or thrombolytic therapy fails, or when there is a contraindication against thrombolytic therapy. In cardiac surgery using CPB during pregnancy, there are possible side effects of CPB, including embolism, coagulopathy, non-pulsatile flow, hypothermia and hypotension.

Fukuda and colleagues [6], in their literature review from 1970 through 2015, reported eight cases of surgical pulmonary embolectomy in pregnant women. In those eight cases, there were no maternal deaths, but two fetal deaths (25%) and two preterm deliveries (40%).

Unfortunately, there isn't any conclusive data on the appropriate treatment of massive PE and only limited case reports of surgical embolectomy for pregnant women. However, surgical embolectomy has its role in complicated emergency situations and may be a good option in critically diseased high-risk pregnant women.

### Conflicts of Interest and Funding

There are no conflicts of interest to declare and no grants or funding was received by any of the authors for this study.

### References

1. Ray JG, Chan WS (1999) Deep vein thrombosis during pregnancy and the puerperium: a meta-analysis of the period of risk and the leg of presentation. *Obstet Gynecol Surv* 54: 265-271.
2. Bourjeily G, Paidas M, Khalil H, Rosene-Montella K, Rodger M (2010) Pulmonary embolism in pregnancy. *Lancet* 375: 500-512.
3. Ahearn GS, Hadjiliadis D, Govert JA, Tapson VF (2002) Massive pulmonary embolism during pregnancy successfully treated with recombinant tissue plasminogen activator: a case report and review of treatment options. *Arch Intern Med* 162: 1221-1227.
4. te Raa GD, Ribbert LS, Snijder RJ, Biesma DH (2009) Treatment options in massive pulmonary embolism during pregnancy; a case-report and review of literature. *Thromb Res* 124: 1-5.
5. Saeed G, Möller M, Neuzner J, Gradaus R, Stein W, et al. (2014) Emergent surgical pulmonary embolectomy in a pregnant woman: case report and literature review. *Tex Heart Inst J* 41: 188-194.
6. Fukuda W, Chiyoya M, Taniguchi S, Daitoku K, Fukuda I (2016) Management of deep vein thrombosis and pulmonary embolism (venous thromboembolism) during pregnancy. *Gen Thorac Cardiovasc Surg* 64: 309-314.