



CASE REPORT

Single-Access Technique and Manta Device in Acute Myocardial Infarction Related Cardiogenic Shock

Andrea Bezzeccheri, MD, Antonietta Di Iorio, MD, Mario Scarpelli, MD and Carlo Briguori, MD, PhD, FACC, FSCAI*



Interventional Cardiology Unit, Mediterranea Cardiocentro, Naples, Italy

*Corresponding author: Carlo Briguori, MD, PhD, FACC, FSCAI, Interventional Cardiology Unit, Mediterranea Cardiocentro, Via Orazio 2, 80121 Naples, Italy, Tel: +390817259764

Abstract

Cardiogenic shock (CS) occurs up to 10% of patients with acute myocardial infarction (AMI) and is associated with a high (> 50%) in-hospital mortality. Mechanical circulatory support (MCS) devices, such as Impella CP, are increasingly being used in patients with AMI complicated by CS. Recent data highlighted the issue of vascular complication and bleeding events in cardiogenic shock patients treated with Impella. In this setting, the “Single-access for High-risk PCI” (SHiP) technique and the use of safe and effective vascular closure devices (VCD) could be useful to reduce the vascular complication rate. We report a case of AMI-related CS in which a single femoral access, used for both Impella CP and percutaneous coronary intervention (PCI) of critical left main stenosis, was successfully closed by the MANTA VCD using a depth locator tool. This strategy allows to limit the number of arterial access sites and to reduce the profile of interventional tools through femoral and iliac artery. Furthermore, the use of MANTA VCD is an important innovation to achieve hemostasis after removal of large-bore sheath needed to MCS in AMI complicated by CS, reducing vascular complication and arterial access site bleeding.

Keywords

Cardiogenic shock, Acute myocardial infarction, Mechanical circulatory support, Vascular closure device, Vascular access site, High-risk percutaneous coronary intervention, Case report

Abbreviations

CS: Cardiogenic Shock; AMI: Acute Myocardial Infarction; MCS: Mechanical Circulatory Support; SHiP: Single-Access for High Risk PCI; VCD: Vascular Closure Device; PCI: Percutaneous Coronary Intervention; STEMI: ST-Elevation Myocardial Infarction; LVED: LV Ejection Fraction; SCAI: Society for Cardiovascular Angiography and Interventions

Introduction

Cardiogenic shock (CS) occurs in 5 to 10% of patients with acute myocardial infarction (AMI) and is associated with a high (> 50%) in-hospital mortality [1]. Mechanical circulatory support (MCS) devices are increasingly being used in patients with AMI complicated by CS, although their clinical advantage is still controversial [2]. The Impella CP (Abiomed, Danvers, MA) is a continuous-flow MCS device with a microaxial pump that decompresses the left ventricle and delivers a maximum flow of 4.0 L/min into the ascending aorta. In the setting of CS, the Impella device unloads the ventricle, reduces ventricular end-diastolic pressure, increases mean arterial pressure and decreases myocardial oxygen consumption. In April 2016, the US Food and Drug Administration approved the Impella device for use in AMI-related CS based on circulatory support effect, not based on improved clinical outcomes [2]. Though, recent data highlighted the issue of vascular complication and bleeding events in cardiogenic shock patients treated with Impella, occurring respectively in 7.4% and 15.2% of the cases [3]. In this setting, the “Single-access for High-risk PCI” (SHiP) technique and the use of safe and effective vascular closure devices (VCD) could be useful to reduce the vascular complication rate [4,5]. We report a case of AMI-related CS in which a single femoral access, used for both Impella CP and percutaneous coronary intervention (PCI), was successfully closed by the MANTA VCD.

Case Description

A 72-year-old female without known risk factors nor previous cardiac history was admitted to the emergency department of a spoke centre for relapsing chest pain episodes over the last 24 h. On the 12-lead electrocardiogram a diagnosis of sub-acute anterior ST-elevation myocardial infarction (STEMI) was made and the patient was transferred to our catheterization laboratory to undergo invasive treatment. At presentation, systolic blood pressure was 85 mmHg, heart rate was 105 beats/min, arterial oxygen saturation was 92%, and lactate level was 1.4 mmol/L. The echocardiographic assessment performed at baseline revealed severe left ventricular dysfunction (LV ejection fraction [LVEF] = 25%) and preserved right ventricular function (tricuspid annular plane systolic excursion = 21 mm; fractional area change = 36%). According to the high-risk features that frame the clinical case as stage B cardiogenic shock ("Beginning" CS or pre-shock/compensated shock) according to Society for Cardiovascular Angiography and Interventions (SCAI) consensus, we chose to perform elective LV unloading before reperfusion by using Impella CP device [2,6].

The Impella 14F sheath was advanced into the right common femoral artery under fluoroscopic guidance, and the Impella CP device was placed in the left ventricle according to the recommendations. Subsequently, a micropuncture access needle was used to pierce the hemostasis valve in the superior portion of the Impella sheath (with care to avoid piercing the Impella catheter) and a 6F sheath was advanced through a 0.035" guidewire, according to the ShiP technique [5], in order to perform coronary angiography and eventual PCI (Figure 1). A tight (> 80%) distal left main stenosis involving the ostium of left anterior descending in a left dominance system was documented. We therefore performed an Impella-assisted PCI. Using a 6F extra back-up 4 Launcher guide catheter (Medtronic, Minneapolis, MN), a provisional stenting of left main and proximal left anterior descending was performed with final kissing balloon to optimize stent apposition. The final angiographic result was good (residual stenosis < 10% and TIMI 3 antegrade flow). The procedure was carried out without complications. Hemodynamic conditions were stable during the entire procedure and vasopressors were not required. MCS was maintained

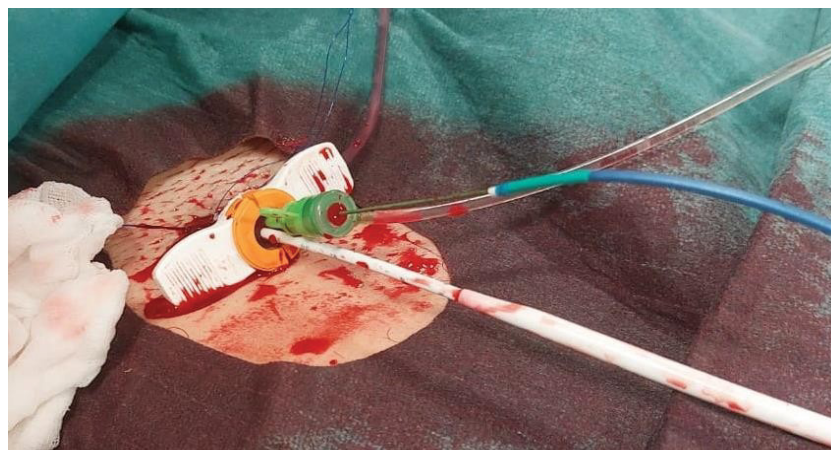

Figure 1: Single-access technique. The Impella 14 F sheath was advanced into the right common femoral artery. Two catheters were introduced into the 14F sheath: a) The Impella CP catheter (white catheter) and b) a 6F sheath (green) through which perform coronary angiography and percutaneous coronary intervention.

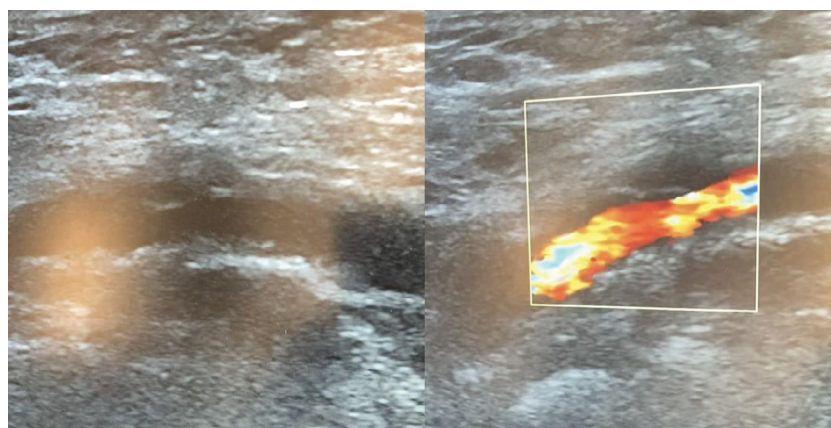


Figure 2: Ultrasound examination. Effective sealing of the access site in the right common femoral artery assessed by two-dimensional and Color-Doppler examination.

for 24 hours. Hemostasis of the right femoral arterial access was achieved using a 14F MANTA VCD (Teleflex, Wayne, PA): After removing the 14F Impella sheath over a 0.035" guidewire, we used the 14F puncture location dilator (depth locator) to measure the length of the subcutaneous track from the skin to the endovascular lumen (Video 1). A 2D-color Doppler exam of the right femoral access site showed effective access site closure (Figure 2). The patient was discharged after 5 days with an almost complete recovery of left ventricle function.

Discussion

To the best of our knowledge, this is the first description of an Impella-assisted PCI in an AMI-related CS patient using a single arterial access which was successfully managed with a 14F MANTA VCD and the new 14F puncture location dilator.

Cardiogenic shock is still a clinical setting weighed on by a high rate of in-hospital mortality although MCS could play an important role favoring left ventricular unloading and systemic effective perfusion [2]. Unfortunately, bleeding and vascular major complication are quite frequent and correlated to large sheath needed to place mechanical circulatory support devices [7].

Strategies to reduce bleeding and vascular complications include: 1) limiting the number of arterial access sites; 2) optimize artery puncture technique; 3) use of effective and safe VCD. SHiP technique has been proposed to allow for rapid and safer single access utilizing only the Impella access site [5]. The Impella 14F sheath is labeled to be used as access for 6F and 7F femoral sheath, in order to reduce the number of puncture sites and to reduce the profile of interventional tools through femoral and iliac artery; sheathless guiding in the Impella 14F sheath has been described [8].

Current approach to achieve hemostasis after large-bore sheath removal includes a suture-based "Preclose" technique, where one (or two) suture device is used at the beginning, before large-bore access sheath positioning [9]. This approach however is time consuming. Indeed, compared to patients undergoing elective or scheduled procedures, in emergency setting such as cardiogenic shock, a dedicated, meticulous access approach may be precluded and associated with a significant failure rate.

An alternative approach is the use of the 14F MANTA VCD. This implies the initial assessment of the artery puncture site depth by the 8 Fr puncture location dilator provided by the MANTA VCD. This approach, however, requires 1) The availability of a separate sterile package of the location dilator, under penalty of wasting a MANTA device; 2) The risk of inaccuracy due to the presence of hematoma developed after femoral artery puncture; 3) The need to remember or keep the value

of puncture site depth for several hours or days. Indeed, the median duration of support with Impella device in studies focusing on AMI complicated by CS ranged from 38 to 49 hours [10].

The new 14F puncture location dilator allows to assess artery puncture site depth when the mechanical support is suspended. The availability of the 14F puncture location dilator therefore obviates to all the above issues and represents an important innovation to achieve hemostasis after removal of large-bore sheath needed to MCS in AMI complicated by CS.

Conclusion

In AMI-related CS an Impella-assisted PCI may be carried out through a single arterial access which may be successfully managed with a 14F MANTA VCD and the new 14F puncture location dilator.

Acknowledgment

All authors listed have made a substantial, direct and intellectual contribution to the work, and approved it for publication.

Conflict of Interest

The authors declare that the research was conducted in the absence of any commercial or financial relationships that could be construed as a potential conflict of interest.

References

- Wayangankar SA, Bangalore S, McCoy LA, Jneid H, Latif F, et al. (2016) Temporal trends and outcomes of patients undergoing percutaneous coronary interventions for cardiogenic shock in the setting of acute myocardial infarction: A report from the CathPCI Registry. *JACC Cardiovasc Interv* 9: 341-351.
- Naidu SS, Baran DA, Jentzer JC, Hollenberg SM, van Diepen S, et al. (2022) SCAI SHOCK stage classification expert consensus update: A review and incorporation of validation studies: This statement was endorsed by the American College of Cardiology (ACC), American College of Emergency Physicians (ACEP), American Heart Association (AHA), European Society of Cardiology (ESC) Association for Acute Cardiovascular Care (ACVC), International Society for Heart and Lung Transplantation (ISHLT), Society of Critical Care Medicine (SCCM), and Society of Thoracic Surgeons (STS) in December 2021. *J Am Coll Cardiol* 79: 933-946.
- Thiele H, Jobs A, Ouweneel DM, Henriques JPS, Seyfarth M, et al. (2017) Percutaneous short-term active mechanical support devices in cardiogenic shock: A systematic review and collaborative meta-analysis of randomized trials. *Eur Heart J* 38: 3523-3531.
- Mocchetti F, Brinkert M, Seelos R, Ockert S, Bossard M, et al. (2019) Insights from a multidisciplinary introduction of the MANTA vascular closure device. *JACC Cardiovasc Interv* 12: 1730-1736.
- Wollmuth J, Korngold E, Croce K, Pinto DS (2020) The single-access for Hi-risk PCI (SHiP) technique. *Catheter Cardiovasc Interv* 96: 114-116.

6. Kapur NK, Alkhouli MA, DeMartini TJ, Faraz H, George ZH, et al. (2019) Unloading the left ventricle before reperfusion in patients with anterior ST-segment-elevation myocardial infarction. *Circulation* 139: 337-346.
7. Johannsen L, Mahabadi AA, Totzeck M, Krueger A, Jánosi RA, et al. (2019) Access site complications following Impella-supported high-risk percutaneous coronary interventions. *Sci Rep* 9: 17844.
8. Whitbeck MG, Chambers JW (2021) Single-access during Impella hemodynamic support utilizing the railway system. *Catheter Cardiovasc Interv* 97: 675-678.
9. Lata K, Kaki A, Grines C, Blank N, Elder M, et al. (2018) Pre-close technique of percutaneous closure for delayed hemostasis of large-bore femoral sheaths. *J Interv Cardiol* 31: 504-510.
10. Ouweneel DM, Eriksen E, Sjauw KD, van Dongen IM, Hirsch A, et al. (2017) Percutaneous Mechanical Circulatory Support Versus Intra-Aortic Balloon Pump in Cardiogenic Shock After Acute Myocardial Infarction. *J Am Coll Cardiol* 69: 278-287.