



## CASE REPORT

# Metastatic Tfe3-Overexpressing Renal Cell Carcinoma: Case Report and Literature Review

**Paulo Victor Zattar Ribeiro<sup>1</sup>, Leonora Zozula Blind Pope<sup>2</sup>, Beatriz Granelli<sup>1</sup>, Milena Luisa Schulze<sup>1\*</sup>, Andréa Rodrigues Cardovil Pires<sup>3</sup> and Mateus da Costa Hummelgen<sup>1</sup>**

<sup>1</sup>University of Joinville's Region, UNIVILLE, Brazil

<sup>2</sup>Dona Helena Hospital, Blumenau Street, Brazil

<sup>3</sup>Diagnostic Medicine Fonte, São Sebastião, Brazil

\*Corresponding author: Milena Luisa Schulze, Department of Medicine, University of Joinville's Region, UNIVILLE, Paulo Malschitzki Street, 10 - Zona Industrial Norte, 89249-710 Joinville – SC, Brazil



## Abstract

**Background:** Renal cell carcinoma (RCC) associated with Xp11.2 translocation/TFE3 gene fusion (Xp11.2 RCC) is a rare subtype of RCC which is delineated as a distinct entity in the 2004 World Health Organization renal tumor classification.

**Objective:** To highlight a rare case, with few publications on the topic, in addition to providing scientific explanations about it.

**Method:** This is a case report of a 58-year-old white male with the diagnosis of renal clear cell carcinoma (RCC). The immunohistochemistry was performed and showed positivity for anti-CD10, vimentine and antibody TFE-3, corresponded to Xp11.2 RCC. For the case report writing we performed a Fluorescence in situ hybridization (FISH) that was negative for the diagnosis of Xp11.2 RCC.

**Results:** Since the translocations lead to over expression of the TFE3 protein, immunohistochemical staining for TFE3 is widely used as a surrogate marker for the Xp11.2 translocations. However, recent studies have found that the positive predictive value of positive TFE3 staining for Xp11.2 RCC is very low as well as highly false positive results.

**Conclusion:** It's recently know that TFE3 is an immunohistochemical marker of metastasis and poor survival. That fact it's an important explanation of the prognosis and findings of our case report and others published wrongly as Xp11.2 translocations. With this article we intend to bring that into evidence.

## Keywords

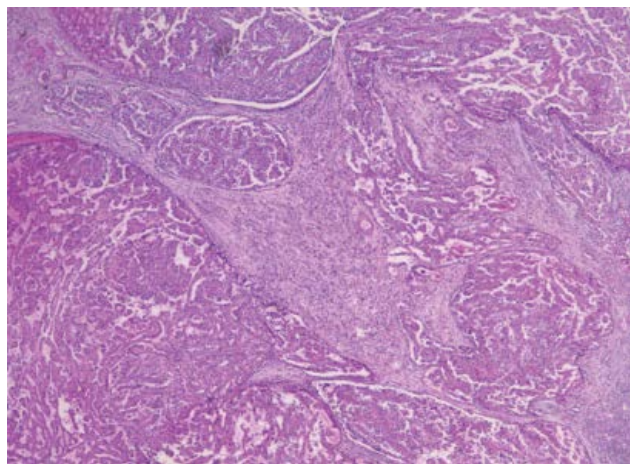
Translocation, Genetic, Carcinoma, Renal cell, *In situ* hybridization, Neoplasms

## Introduction

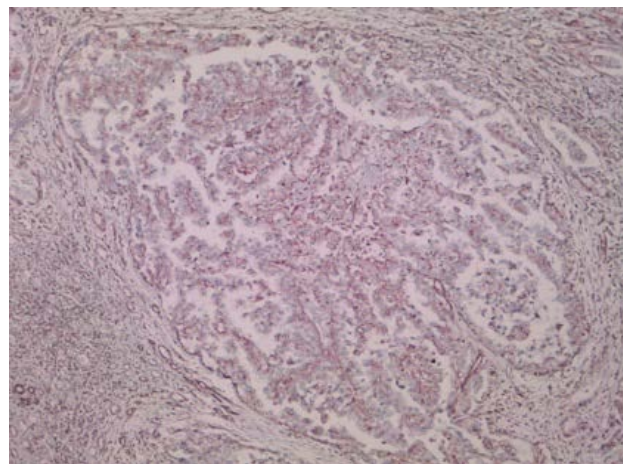
Renal cell carcinoma (RCC) associated with Xp11.2 translocation/TFE3 gene fusion (Xp11.2 RCC) is a rare subtype of RCC which is delineated as a distinct entity in the 2004 World Health Organization renal tumor classification. Its morphology and clinical manifestations often overlap with those of conventional RCCs [1]. Children are more affected by this subtype than adults, accounts for 20-40% of pediatric RCC and 1-1.6% of RCC in adults [2]. The exact incidence of TFE3 translocation renal cell carcinoma among adults remains debatable but estimates range from 1 to 4% of all renal cell carcinoma, with approximately 2500 new cases diagnosed every year [3-5].

A subset of patients might also develop translocation renal cell carcinoma after chemotherapy and/or treatment for neuroblastoma [6]. Although chemotherapeutic agents have varying mechanisms of action, most cytotoxic agents cause DNA damage that might consequently initiate a repair process that in turn could facilitate a chromosomal translocation [1,2]. In adults, TFE3 translocation renal cell carcinoma is an aggressive tumor with overall survival similar to that of clear cell renal cell carcinoma [4,7,8]. The incidence of TFE3 RCC is higher in children than in adults; its prognosis is also better in children [1,9].

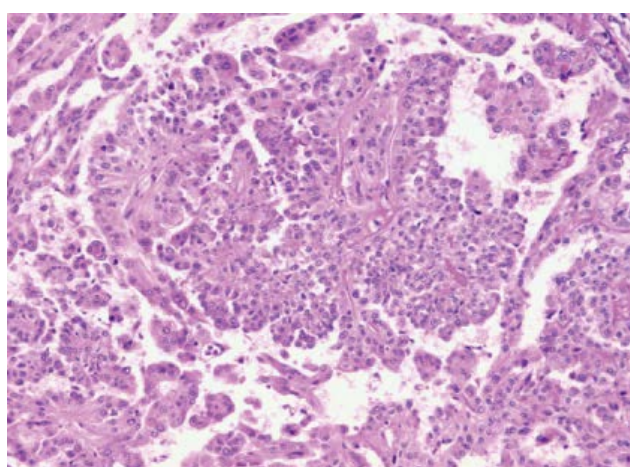
Clinically, patients with Xp11.2 translocation RCC are typically admitted to the hospital because of hematu-



**Figure 1:** Microscopic appearance of renal cell carcinoma (RCC) with typical papillary architecture.



**Figure 3:** Immunohistochemistry shows immunopositivity for anti-CD10, vimentine and antibody TFE-3.



**Figure 2:** Microscopic appearance of renal cell carcinoma (RCC) with typical papillary architecture.

resis, abdominal pain, or an abdominal mass, and the presence of occupying lesions is confirmed using radiography, kidney color doppler ultrasonography, and CT. As this presentation is similar to that of common adult RCC subtypes such as conventional clear cell RCC and papillary RCC (PRCC), the frequency of Xp11.2 translocation RCCs in adults may be underestimated. One single-institution study subjected 433 adult patients to cytogenetics and TFE3 immunohistochemical analyses and found that Xp11.2 translocation RCCs accounted for 1.6% of the cases [10]. With that in view Xp11.2 translocation RCC should be considered when tumors exhibit a suspicious pattern [11]. But as shown by a systematic review and meta-analysis of observational studies, no significant differences were observed in the prognosis between children and adults, and between female and male [12] (Figure 1 and Figure 2).

### Case Report: Methods and Results

This is a case report of a 58-year-old white male, previously healthy, which presented hematuria. The macroscopy search, product of left nephrectomy, revealed a renal mass of 9.5 × 6.0 × 5.0 cm located on the middle

third of the kidney with dissemination for the renal cortex and peri-renal fat and renal sinus. With a total of 60% of necrosis area. As a microscopy find analysis by immunohistochemistry was seen a micropapillary pattern characterized as stage 3 Fuhrman nuclear, in addition a positivity for anti-CD10, vimentine and antibody TFE-3, corresponded to Xp11.2 RCC. The results came to a diagnosis conclusion of renal clear cell carcinoma (RCC) with lymphnode metastasis, established as pT3N1MX. Three months later, the patient followed with dyspnea, in consequence a pleural biopsy was made and revealed malignant neoplasm confirmed as RCC metastasis. The patient passed away follow seven days, after presenting signs of ascites due to peritoneal carcinomatosis. For the case report writing it was performed Fluorescence *in situ* hybridization (FISH) that concluded negative for the diagnosis of Xp11.2 RCC (Figure 3).

### Discussion

Xp11.2 RCC is a rare subtype of RCC which results from gene fusions between the transcription factor E3 (TFE3) gene and at least 5 fusion partners including ASPL-TFE3, PRCC-TFE3, PSF-TFE3, CLTC-TFE3, and Nono-TFE3 [13,14]. Due to the translocations lead to overexpression of TFE3 protein, detection of TFE3 protein by IHC assay is currently the most commonly used diagnostic technique in clinical practice [10]. Gaillot-Durand, et al. showed that nuclei stained with an intensity of ++ to +++ in IHC assay was necessary to suspect the diagnosis of Xp11.2 RCC [15]. However, recent studies have found that the positive predictive value of positive TFE3 staining for Xp11.2 RCC is very low as well as highly false positive results [16]. In that way, definite diagnosis of Xp11.2 RCC should be not only made by IHC assay but also by such strict criteria as FISH assay and other molecular biology [16].

So it's know that Xp11 translocation renal cell carcinoma is cytogenetically characterized by chromosomal translocations involving breakpoints in the TFE3 gene, which maps to the Xp11.2 locus. Histologically, a wide

spectrum of morphology has been described in these tumors, emphasizing the need to consider these carcinomas in the differential diagnosis of unusual renal cell carcinomas occurring in either children or adults [3]. Strong nuclear TFE3 immunohistochemical expression is a reasonably sensitive and specific marker for Xp11 translocation renal cell carcinoma [17]. However, fluorescence *in situ* hybridization (FISH) assays have been demonstrated to be more reliable [18].

The gross features of Xp11.2 translocation RCC are similar to those of conventional clear cell RCC. Macroscopically, the cut surfaces of the tumors are greyish-yellow in color and exhibit hemorrhaging and necrosis. Morphologically, the tumors comprise a combination of nested and papillary structures with clear-to-granular eosinophilic cytoplasm [11]. In contrast, the different subtypes of Xp11.2 translocation RCC are histopathologically distinct. Typically, cells of the alveolar soft part sarcoma chromosome region (*ASPS*)-*TFE3* subtype are characterized by a higher amount of clear-to-eosinophilic cytoplasm relative to the other subtypes, and exhibit discontinuous cell boundaries, vesicular nuclei, and obvious nucleoli. In contrast, the typical features of *PRCC-TFE3* Xp11.2 translocation RCC include a diminished cytoplasm, fewer psammoma bodies and hyaline globules, and a more nested structure [19].

## Conclusion

Because of the rarity of Xp11.2 translocation RCCs, the prognosis and outcome in these patients are not fully understood. In addition, for the same reasons, there is currently no standard treatment strategy for this malignancy [20]. In contrast to conventional RCC, the appropriate treatment strategies for Xp11 translocation RCC remain unclear, because the natural course of this tumor is not yet fully understood. However, there is a general agreement that Xp11 translocation RCC is associated with a high malignant potential and poor prognosis [21]. The treatment results of patients with Xp11 translocation RCCs have been previously reported [22-24]. However, although various treatments have been applied, no effective treatment has yet been established. In short, adequate prolongation of survival by cytotoxic chemotherapy, radiation, and/or immunotherapy has never been accomplished. Moreover, there is one previous report of over expression of phosphorylated S6, a marker of elevated mammalian target of rapamycin (mTOR) pathway activation, and increased levels of stable HIF1 $\alpha$  in Xp11.2 translocation RCC [25]. Furthermore, Xp11.2 translocation/*TFE3* gene fusion has been reported to up regulate the mesenchymal-epithelial transition tyrosine kinase receptor, consequently leading to the activation of the phosphatidylinositol-3 kinase and mTOR pathways [26,27]. Considering these reports, it has been suggested that mTOR inhibitors may be effective for Xp11.2 translocation RCC. Moreover, it has been speculated that targeted agents such as su-

nitinib, sorafenib, and everolimus may be effective and improve progression-free survival for Xp11.2 translocation/*TFE3* gene fusion RCC [28]. However, more detailed information regarding treatment strategies are necessary [27]. Furthermore, based on the specific pathological pathways involved in Xp11.2/*TFE3* gene fusion, elaborate treatment strategies should be developed to improve the prognosis of these patients, owing to their molecular and genetic heterogeneity [21].

## Sources of Support

We declare no financial support and no material support.

## Conflict of Interest

All authors declare that there are no conflicts of interest. All authors had an equally contribution.

## References

1. Bruder E, Passera O, Harms D, Leuschner I, Ladanyi M, et al. (2004) Morphologic and molecular characterization of renal cell carcinoma in children and young adults. *Am J Surg Pathol* 28: 1117-1132.
2. Kmetec A, Jeruc J (2014) Xp 11.2 translocation renal carcinoma in young adults; recently classified distinct subtype. *Radiol Oncol* 48: 197-202.
3. Argani P (2015) MiT family translocation renal cell carcinoma. *Semin Diagn Pathol* 32: 103-113.
4. Sukov WR, Hodge JC, Lohse CM, Leibovich BC, Thompson RH, et al. (2012) *TFE3* rearrangements in adult renal cell carcinoma: Clinical and pathologic features with outcome in a large series of consecutively treated patients. *Am J Surg Pathol* 36: 663-670.
5. Zhong M, DeAngelo P, Osborne L, Paniz-Mondolfi AE, Geller M, et al. (2012) Translocation renal cell carcinomas in adults: a single-institution experience. *Am J Surg Pathol* 36: 654-662.
6. Falzarano SM, McKenney JK, Montironi R, Eble JN, Osunkoya AO, et al. (2016) Renal cell carcinoma occurring in patients with prior neuroblastoma: A heterogenous group of neoplasms. *Am J Surg Pathol* 40: 989-997.
7. Srigley JR, Delahunt B, Eble JN, Egevad L, Epstein JI, et al. (2013) The International Society of Urological Pathology (ISUP) Vancouver Classification of Renal Neoplasia. *Am J Surg Pathol* 37: 1469-1489.
8. Hora M, Urge T, Trávníček I, Ferda J, Chudacek Z, et al. (2014) MiT translocation renal cell carcinomas: Two subgroups of tumours with translocations involving 6p21 [t (6; 11)] and Xp11.2 [t (X;1 or X or 17)]. *Springerplus* 3: 245.
9. Geller JI, Ehrlich PF, Cost NG, Khanna G, Mullen EA, et al. (2015) Characterization of adolescent and pediatric renal cell carcinoma: A report from the Children's Oncology Group study AREN03B2. *Cancer* 121: 2457-2464.
10. Komai Y, Fujiwara M, Fujii Y, Mukai H, Yonese J, et al. (2009) Adult Xp11 translocation renal cell carcinoma diagnosed by cytogenetics and immunohistochemistry. *Clin Cancer Res* 15: 1170-1176.
11. Xu ZY, Wang JP, Zhang Y, Wu SW, Ma L, et al. (2019) "Xp11.2 translocation/*TFE3* gene fusion renal cell carcinoma with a micropapillary pattern: Cases report and literature review". *American Journal of Translational Research* 11: 327-339.

12. Cheng X, Gan W, Zhang G, Li G, Guo H (2016) Clinical characteristics of XP11.2 translocation/TFE3 gene fusion renal cell carcinoma: A systematic review and meta-analysis of observational studies. *BMC* 16: 40.
13. Wang W, Ding J, Li Y, Wang C, Zhou L, et al. (2014) Magnetic Resonance Imaging and Computed Tomography Characteristics of Renal Cell Carcinoma Associated with Xp11.2 Translocation/TFE3 Gene Fusion. *PLoS One* 9: e99990.
14. Liu K, Xie P, Peng W, Zhou Z (2014) Renal carcinomas associated with Xp11.2 translocations/TFE3 gene fusions: findings on MRI and computed tomography imaging. *J Magn Reson Imaging* 40: 440-447.
15. Gaillot-Durand L, Chevallier M, Colombel M, Couturier J, Pierron G, et al. (2013) Diagnosis of Xp11 translocation renal cell carcinomas in adult patients under 50 years: Interest and pitfalls of automated immunohistochemical detection of TFE3 protein. *Pathol Res Pract* 209: 83-89.
16. Klatte T, Streubel B, Wrba F, Remzi M, Krammer B, et al. (2012) Renal cell carcinoma associated with transcription factor E3 expression and Xp11.2 translocation: incidence, characteristics, and prognosis. *Am J Clin Pathol* 137: 761-768.
17. Argani P, Lal P, Hutchinson B, Lui MY, Reuter VE, et al. (2003) Aberrant nuclear immunoreactivity for TFE3 in neoplasms with TFE3 gene fusions: A sensitive and specific immunohistochemical assay. *Am J Surg Pathol* 27: 750-761.
18. Green WM, Yonescu R, Morsberger L, Morris K, Netto GJ, et al. (2013) Utilization of a TFE3 break-apart FISH assay in a renal tumor consultation service. *Am J Surg Pathol* 37: 1150-1163.
19. Argani P, Antonescu CR, Couturier J, Fournet JC, Sciot R, et al. (2002) PRCC-TFE3 renal carcinomas: morphologic, immunohistochemical, ultrastructural, and molecular analysis of an entity associated with the t(X;1)(p11.2;q21). *Am J Surg Pathol* 26: 1553-1566.
20. Kakoki K, Miyata Y, Mochizuki Y, Iwata T, Obatake M, et al. (2017) Long-term Treatment with Sequential Molecular Targeted Therapy for Xp11.2 Translocation Renal Cell Carcinoma: A Case Report and Review of the Literature. *Clinical Genitourinary Cancer* 15: e503-e506.
21. Argani P, Ladanyi M (2003) Recent advances in pediatric renal neoplasia. *Adv Anat Pathol* 10: 243-260.
22. Geller JI, Argani P, Adeniran A, Hampton E, Marzo AD, et al. (2008) Translocation renal cell carcinoma: Lack of negative impact due to lymph node spread. *Cancer* 112: 1607-1616.
23. Wu A, Kunju LP, Cheng L, Shah RB (2008) Renal cell carcinoma in children and young adults: Analysis of clinicopathological, immunohistochemical and molecular characteristics with an emphasis on the spectrum of Xp11.2 translocation-associated and unusual clear cell subtypes. *Histopathology* 53: 533-544.
24. Malouf GG, Camparo P, Oudard S, Schleiermacher G, Theodore C, et al. (2010) Targeted agents in metastatic Xp11 translocation/TFE3 gene fusion renal cell carcinoma (RCC): A report from the Juvenile RCC Network. *Ann Oncol* 21: 1834-1838.
25. Argani P, Hicks J, De Mrzo AM, Albadine R, Illei PB, et al. (2010) Xp11 translocation renal cell carcinoma (RCC): extended immunohistochemical profile emphasizing novel RCC markers. *Am J Surg Pathol* 34: 1295-1303.
26. Moumen A, Patané S, Porras A, Dono R, Maina F (2007) Met acts on Mdm2 via mTOR to signal cell survival during development. *Development* 134: 1443-1451.
27. Sudour-Bonnange H, Leroy X, Chauvet M, Classe M, Robin PM (2014) Cutaneous metastases during an aggressive course of Xp11.2 translocation renal cell carcinoma in a teenager. *Pediatr Blood Cancer* 61: 1698-1700.
28. Macher-Goeppinger S, Roth W, Wagener N, Hohenfellner M, Penzel R, et al. (2012) Molecular heterogeneity of TFE3 activation in renal cell carcinomas. *Mod Pathol* 25: 308-315.