



## RESEARCH ARTICLE

## A Prospective Study to Evaluate the Outcome of Pars Plana Vitrectomy for Intra-Ocular Foreign Bodies

Natwar Singh Parihar\*, Mominul Islam, Nazmun Nahar and Mostafizur Rahman

Royal Free Hospital London, Pond Street, London, NW32QH



\*Corresponding author: Natwar Singh Parihar, Royal Free Hospital London, Pond Street, London, NW32QH

### Abstract

**Introduction:** Ocular trauma is an important cause of visual morbidity and blindness, mainly in the group of working-age population a record based study was carried out to gather baseline information of the cases of intraocular foreign bodies treated by pars plana vitrectomy and to evaluate the short-term outcome of the cases.

**Methods:** One year data from June 2017 to June 2018 was taken from records of the tertiary eye care hospital in Bangladesh. Total 28 cases were included in the study. Data was calculated in percentage.

**Results:** Most common age group was 21-40 years (57.15%) with male predominance (96.43%). Right eye was involved in 53.57%. Out of 28 FBs, 26 were iron particles. Location of the FB was retina in 53.57% cases and vitreous in 46.43% cases. Most common complication was cataract.

**Conclusion:** All cases had improved visual acuity after pars plana vitrectomy. 23-Gauge PPV is a feasible, effective approach in the surgical management of the patients with posterior segment intraocular foreign bodies.

### Keywords

IOFB-Intra ocular foreign body, PPV-Pars Plana Vitrectomy

initial damage, IOFBs are often associated with corneal and scleral penetrating injury, hyphema, vitreous haemorrhage, lens injury, retinal damage or detachment, and even more serious complications such as endophthalmitis. Several studies have reported the outcome of pars plana vitrectomy (PPV) for posterior segment IOFBs [3]. The advancement in microsurgical vitreoretinal surgery techniques and instrumentation has allowed managing traumatized eyes with IOFBs skillfully with good anatomical and cosmetic outcomes. This study is done to gather and examine the baseline information for cases with intra-ocular foreign bodies which were treated by 23-gauge PPV.

### Aim

To study the outcome of pars plana vitrectomy in patients of intra-ocular foreign bodies.

### Objectives

- To study the anatomical outcome in patients of IOFB treated with pars plana vitrectomy.
- To study the visual outcome in patients of IOFB treated with pars plana vitrectomy.

### Materials and Methods

The study is a short term Prospective study availed from institute Ispahani Islamia Eye Institute, Dhaka, Bangladesh. The data collection was done after getting an approval from ethical committee and permission from the concerned authority. Data for the period of one year, from June 2017 to June 2018 was taken from records for 28 cases. We have taken information con-

### Background

Open globe injury with or without intraocular foreign body (IOFB) often has a poor visual outcome [1]. Open globe injuries are complicated with the presence of intraocular foreign body (IOFB) in 10 to 41% of cases [2]. IOFB injuries are a relatively common form of ocular injury especially in young men [3]. A foreign body is an object, or more than one object, that has entered and is present in the body but does not belong there and was not placed there by a surgeon [4]. In addition to the



**Citation:** Parihar NS, Islam M, Nahar N, Rahman M (2020) A Prospective Study to Evaluate the Outcome of Pars Plana Vitrectomy for Intra-Ocular Foreign Bodies. Int J Ophthalmol Clin Res 7:122. doi.org/10.23937/2376-346X/1410122

**Accepted:** December 29, 2020; **Published:** December 31, 2020

**Copyright:** © 2020 Parihar NS, et al. This is an open-access article distributed under the terms of the Creative Commons Attribution License, which permits unrestricted use, distribution, and reproduction in any medium, provided the original author and source are credited.

taining age, gender, side of the injured eye, IOFB characteristics, ocular lesions, initial and final visual acuities, complications and duration between injury and surgery. All the cases of intra-ocular foreign bodies which were treated with pars plana vitrectomy during a period of one year from 1<sup>st</sup> June 2017 to 31<sup>st</sup> May 2018 were included in the study. Visual acuity was measured with Snellen's chart and Logmar chart on days 1, week 1 and week 6 post-operatively respectively.

At presentation we analyzed relative afferent pupillary defect (RAPD), Snellen best corrected visual acuity (BCVA), anterior segment by slit lamp bio-microscopy, intraocular pressure (IOP), and posterior segment by fundus-scopy. Ancillary tests like B-mode ultrasonography and computed tomography (CT) were performed to analyze ocular and orbital status and to detect the localization of the IOFBs. All patients were treated by 23-gauge pars plana vitrectomy by a single physician. Postoperatively all patients received antibiotics and steroid eye drops for four weeks with gradual tapering.

### Surgical approach

**23 G PPV and IOFB removal and phacoemulsification:** Surgeries were performed under general anaesthesia, and phacoemulsification was performed prior to PPV. Phacoemulsification was performed via a 2.8 mm clear corneal tunnel with a standard phaco-chop technique. A foldable hydrophilic acrylic IOL was implanted in the bag in the event that the posterior capsule was intact. In cases with posterior capsule defects, a polymethyl methacrylate IOL with an overall diameter of 13 mm was placed in the ciliary sulcus. The incision was sutured with 10-0 nylon.

**23 G PPV and IOFB removal:** Surgery was performed under general anaesthesia or local anaesthesia. The cannula was then inserted at a 10-30° angle 3.5 mm from the limbus through the conjunctiva, sclera, and pars plana. The cannulas were placed in the inferotemporal, supero-temporal, and supero-nasal quadrants. The cannulas were inserted using beveled trocars, a single-step procedure. An illumination probe was placed at the supero-nasal quadrant, and a 23-G infusion cannula was placed at the inferotemporal quadrant. All surgical procedures were carried out using the 3-port, 23-gauge vitrectomy system using standard 23-gauge vitrectomy techniques. Pars plana vitrectomy (PPV) was performed using a 23-G high-speed vitrector. The vitrectomy was performed from posterior vitreous- to vitreous base. The posterior hyaloid was removed using active aspiration in cases without complete posterior vitreous detachment. To remove the foreign body, one of the sclerotomy sites was enlarged like the T or L letters. With the 20-gauge forceps, the IOFB was removed without any difficulty. Endo-laser treatment was applied with a curved 23-G laser probe to the retinal entrance of the foreign body and other retinal breaks.

**23 G PPV and IOFB removal and retinal detachment:** In patients with retinal detachment the vitrectomy begins with the removal of the vitreous humour, followed by displacement of the subretinal fluid by a heavy tamponade and scarring of the retina by laser coagulation. The vitreous is then replaced by a tamponade, which holds the retina against the underlying retinal pigment epithelium until a scar has formed around the retinal hole. As endo-tamponade, silicone oil was injected with a 23-gauge cannula system and 10 mL injector. Silicone oil was used as a tamponade. At the end of surgery an absorbable 7-0-vicryl suture was used to close the expanded sclerotomy site and the conjunctiva. The remaining two 23-gauge micro cannulas were then removed and sclerotomy sites were also closed with 7-0-vicryl suture. Postoperative examinations were conducted at first day, first week, and at the end of 6 weeks.

**Inclusion criteria:** All cases of intra ocular foreign bodies undergoing pars plana vitrectomy during the period of one year from 1<sup>st</sup> June 2017 to 31<sup>st</sup> May 2018.

**Exclusion criteria:** Cases of IOFBs not treated with pars plana vitrectomy. Those with foreign bodies in anterior vitreous.

**Statistical analysis:** Statistical analysis was done by using Microsoft Excel and SPSS version 25.

**Ethical issues:** All precaution & care was taken to maintain confidentiality & secrecy of the personal health related information. The requisite permission from the respective authorities has been obtained and ethical clearance was obtained.

### Results

Total 28 cases of IOFB which were treated by PPV were analysed. Out of total 28, majority 16 (57.15%) were in the age group of 21-40 years followed by 9 (32.14%) from the age group of 1-20 years. Age ranges from 2.5 to 60 years. Median age was 24.5 years (Table 1).

Males were more in number (27; 96.43%) than females (1; 3.57%).

Right eye was more commonly involved.

Iron particle (26/28) was the most common type of foreign body followed by glass and tree branch.

Most of the FBs were located in retina (15; 53.57%) (Table 2).

Cataract was the most common complication followed by endophthalmitis, corneal opacity, retinal detachment etc. (Table 3).

All the cases were operated as penetrating type of pars plana vitrectomy. Average interval between trauma and surgery was 12.88 days with minimum of 4 days to maximum of 31 days (Table 4).

**Table 1:** Demographic profile of the cases.

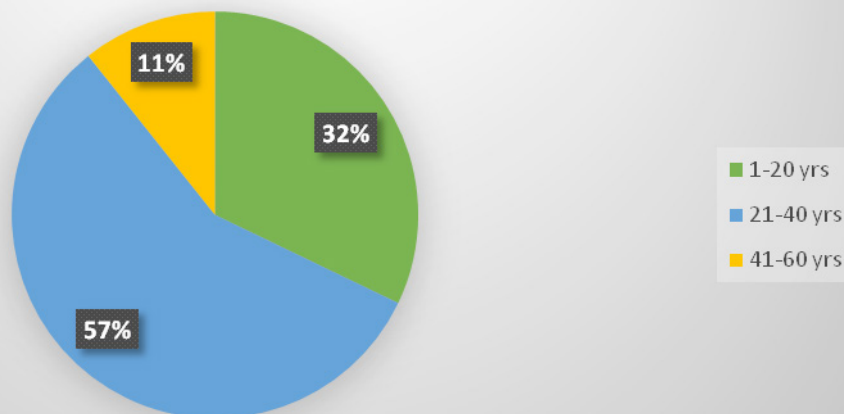
Variables	Groups	Frequency	%
Age in years	1-20	9	32.14
	21-40	16	57.15
	41-60	3	10.71
Gender	Male	27	96.43
	Female	1	3.57
Eye	Right eye	15	53.57
	Left eye	13	46.43
Total		28	100

Out of total 28, majority 16 (57.15%) were in the age group of 21-40 years followed by 9 (32.14%) from the age group of 1-20 years. Age ranges from 2.5 to 60 years. Median age was 24.5 years.

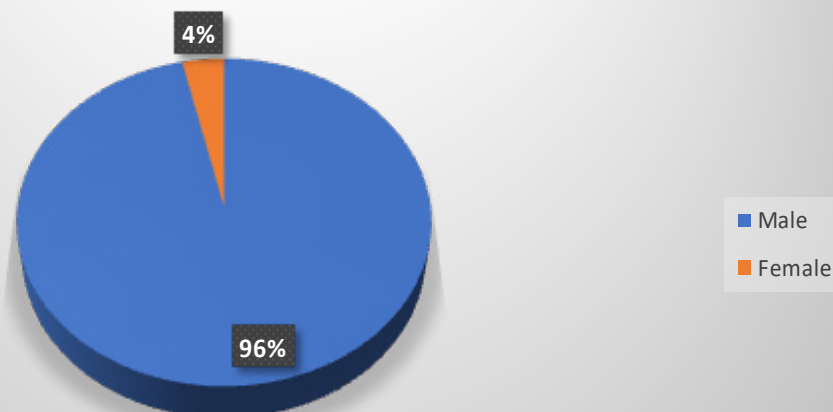
Males were more in number (27; 96.43%) than females (1; 3.57%).

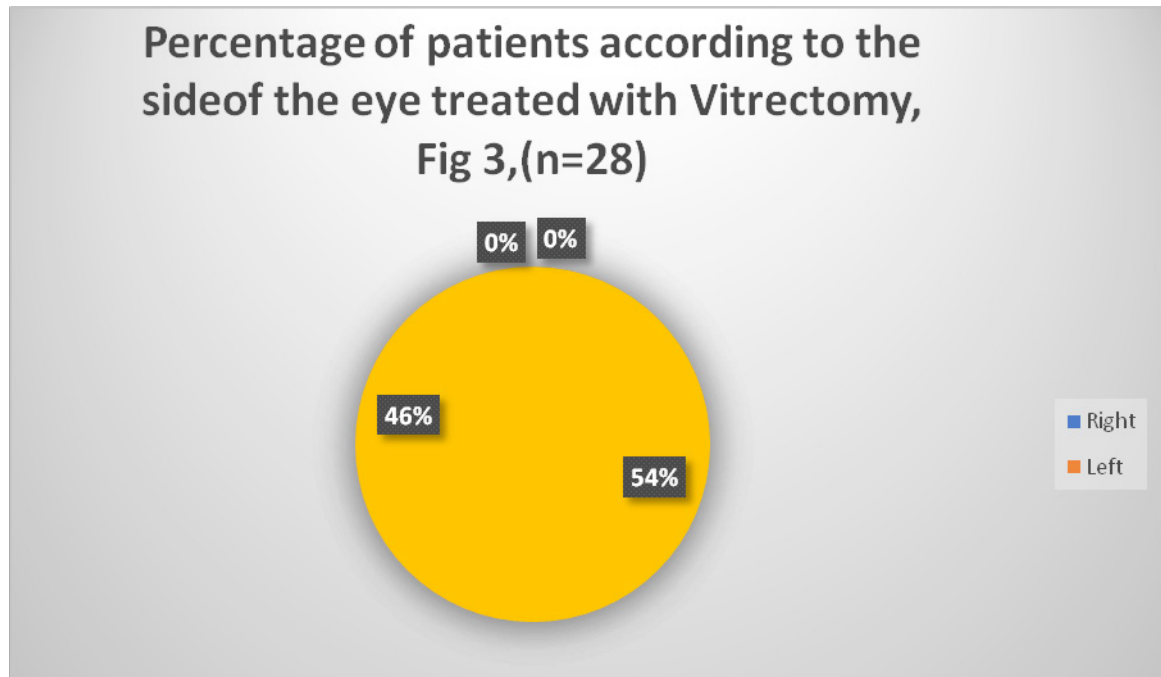
Right eye was more commonly involved.

### Age group of patients with IOFB who were treated with Vitrectomy, Fig 1, (n=28)



### Gender wise distribution of patients with IOFB treated with Vitrectomy, Fig 2, (n=28)

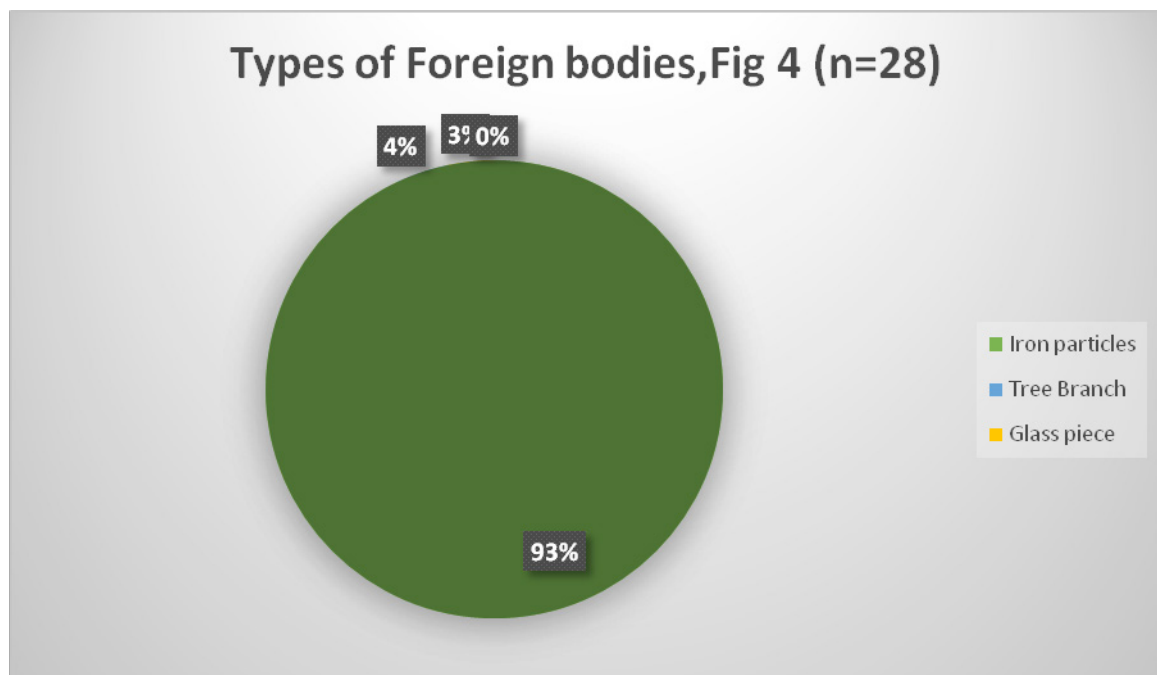


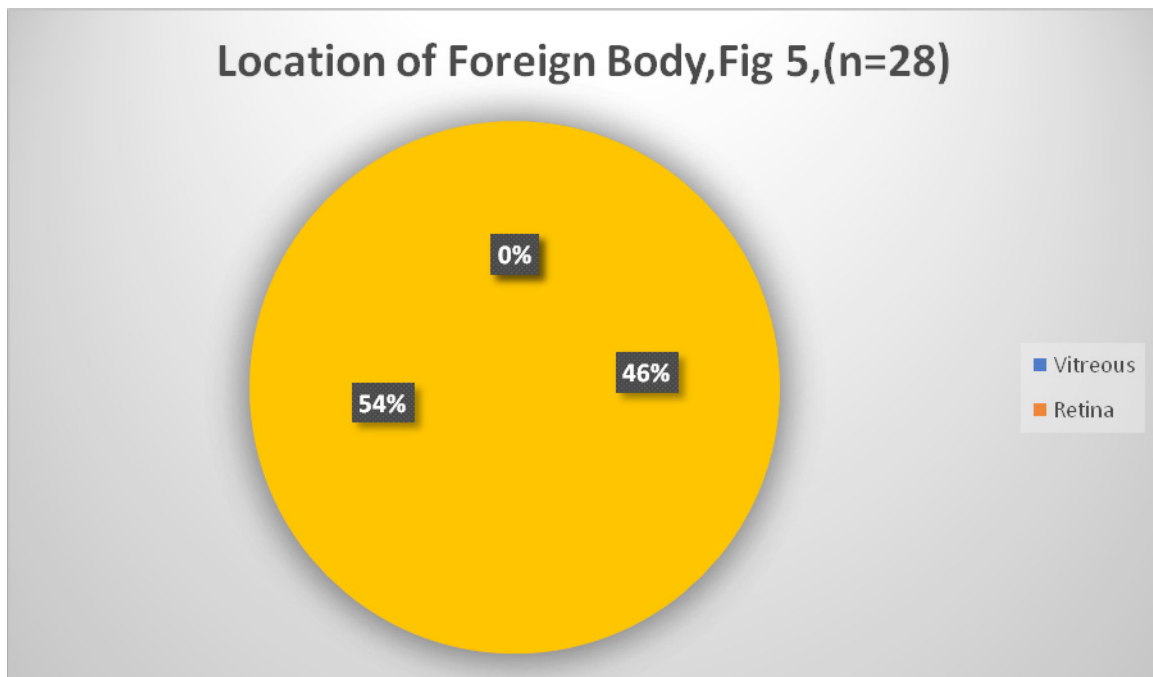


**Table 2:** Characteristics of foreign bodies (FB).

Characteristics	Groups	Frequency	%
Type of F.B.	Iron particles	26	92.86
	Tree branch	1	3.57
	Glass piece	1	3.37
Location of foreign body	Vitreous	13	46.43
	Retina	15	53.57
<b>Total</b>		<b>28</b>	<b>100</b>

Iron particle (26/28) was the most common type of foreign body followed by glass and tree branch. Most of the FBs were located in retina (15; 53.57%).



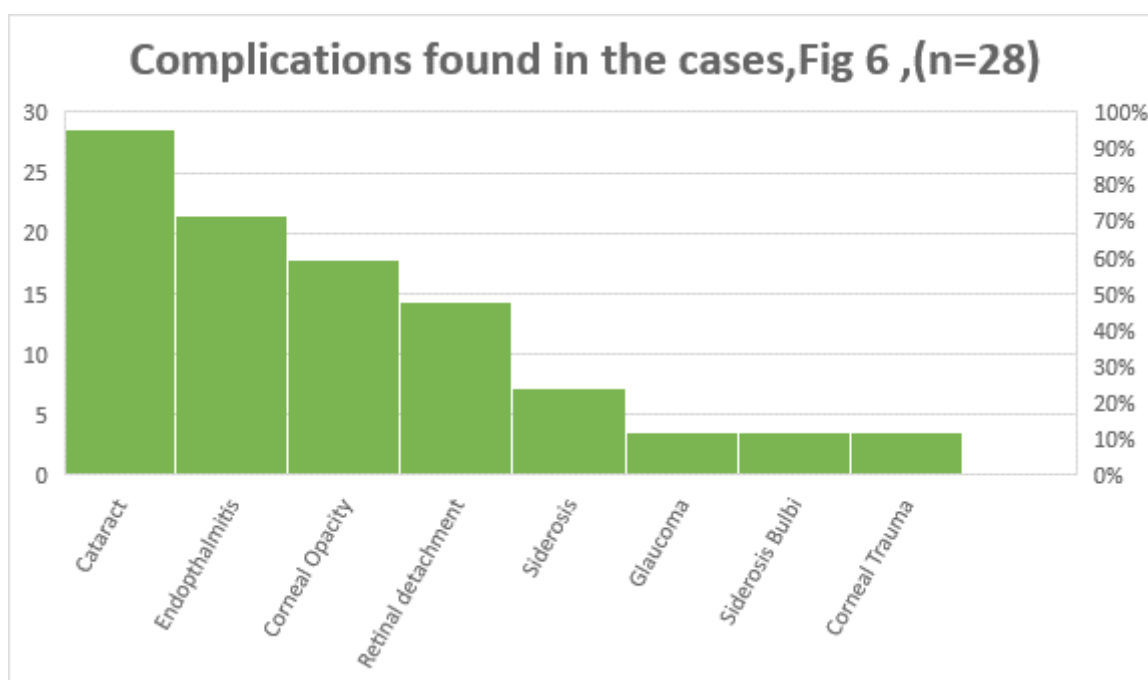


**Table 3:** Complications found in the cases

Complication	Frequency	%
Cataract	8	28.57
Endophthalmitis	6	21.42
Corneal opacity	5	17.85
Retinal detachment	4	14.28
Siderosis	2	7.14
Glaucoma	1	3.58
Siderosis bulbi	1	3.58
Corneal trauma	1	3.58
Total	28	100

Cataract was the most common complication followed by endophthalmitis, corneal opacity, retinal detachment etc.

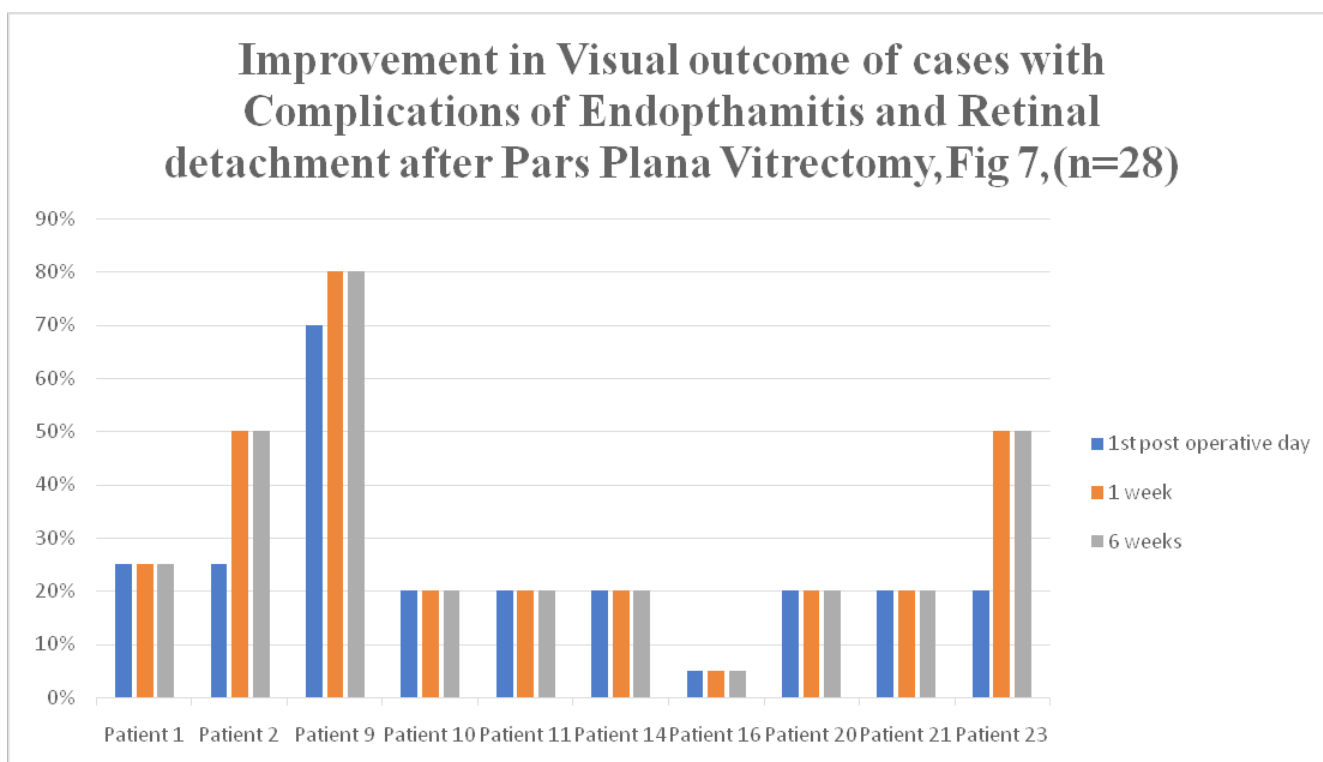
All the cases were operated as penetrating type of pars plana vitrectomy. Average interval between trauma and surgery was 12.88 days with minimum of 4 days to maximum of 31 days.



**Table 4:** Visual outcomes of the cases

1	FOLLOW FINGER	Endophthalmitis	FF	FF	FF
2	PL + PR +	Retinal Detachment	FF	FC 1 MT	FC 1 MT
3	FC 1 METER	Cataract	6\12	6\12	6\12
4	PL + PR +	Glaucoma	PL + PR +	PL + PR +	PL + PR +
5	PL + PR +	Siderosis	HM CF	HM CF	HM CF
6	PL + PR +	Cataract	PL + PR +	FC 1 MT	FC 1 MT
7	PL + PR +	Siderosis	FC CF	FC 1 MT	FC 1 MT
8	FC 1/2 M	Cataract	FC 3 MT	FC 3 MT	FC 3 MT
9	6\60	Retinal Detachment	6\36	6\24	6\24
10	HM CF	Retinal Detachment	HM CF	HM CF	HM CF
11	HM CF	Endophthalmitis	HM CF	HM CF	HM CF
12	HMCF	Cataract	FC 2 MT	FC 4 MT	FC 4 MT
13	6\60	Cataract	6\36	6\12	6\12
14	HM CF	Endophthalmitis	HMCF	HMCF	HMCF
15	PL + PR +	Corneal Trauma	HMCF	HMCF	HMCF
16	NO PL	Endophthalmitis	NO PL	NO PL	NO PL
17	FC 1 METER	Siderosis Bulbi	PL + PR +	FC 1 MT	FC 1 MT
18	FC1 MT	Cataract	PL + PR +	FC 1 MT	FC 3 MT
19	PL + PR +	Cataract	PL + PR +	FC 3 MT	FC 3 MT
20	PL + PR +	Endophthalmitis	PL + PR +	PL + PR +	PL + PR +
21	PL + PR +	Endophthalmitis	PL + PR +	PL + PR +	PL + PR +
22	PL + PR +	Cataract	PL + PR +	6\60	6\24
23	PL + PR +	Re Retinal Detachment	PL + PR +	FC 1 MT	FC 1 MT
24	PL + PR +	Corneal Opacity	PL + PR +	FC 1 MT	FC 1 MT
25	6\60	Corneal Opacity	6\24	6\6	6\6
26	PL + PR +	Corneal Opacity	PL + PR +	6\60	6\60
27	PL + PR +	Corneal Opacity	PL + PR +	6\12	6\12
28	PL + PR +	Corneal Opacity	PL + PR +	2\60	2\60

PL- PERCEPTION OF LIGHT, PR – PROJECTION OF RAYS, HMCF- HAND MOVEMENT CLOSE TO FACE, FC- FINGER COUNTING



5%- No Projection of Light (PL), 20%- Hand Movement close to face (HMCF), 25%- Follow finger, 50%- Finger counting at 1 Meter, 70%- 6/36 on Snellen's chart, 80%- 6/24 on Snellen's chart.

All cases have shown improvement or remained the same in the visual acuity after operation as compared to that in pre op.

## Discussion

Ocular trauma is an important cause of visual morbidity and blindness, mainly in the group of working-age population. In this context, it was proved that intraocular foreign bodies (IOFBs) can lead to increased ocular morbidity [5]. Here we have studied 28 cases of intraocular foreign body which were treated by PPV. To our Knowledge, this is the first study which studies the visual outcome of surgical management of ocular trauma in Bangladesh.

IOFBs are seen most often in adults and most frequently occur at work sites [6]. Our study has also shown more involvement of young adults (21-40 yrs). Most of the studies [1,5] have shown male predominance which is in accordance with our study which shows 96.43% of males. Iron particles make up 92.86% of foreign bodies; tree branch 3.57% and glass piece make up 3.37% of the foreign bodies. The endophthalmitis risk in the IOFB cases varies between three and 30%, according to the different studies [5]. Endophthalmitis was present in 6 of the 21 IOFBs in the study by Nicoara SD, et al. (28.57%). Our study has shown endophthalmitis in 6 out of 28 (21.42%) which is similar to that shown by Nicoara SD, et al. [5]. Also in our study, retinal detachment was seen in 4/28 eyes.

Before the development of PPV, all the magnetic foreign bodies were extracted from the eye with the external magnet [5]. About 55-60% of these eyes achieved visual acuities of 20/40 or better [5]. The drawback comes from the high risk of retinal detachment in eyes that develop vitreous organization and shortening of the pre-retinal fibrous bands. Majority the IOFBs on our series were magnetic similar to the study by Nicoara SD, et al. [5]. The severity of IOFBs is given by the risk of infection, toxic reactions and ocular lesions produced during their intraocular trajectory [5]. The argument in favour of PPV in the management of IOFBs is that removing the damaged vitreous decreases the risk of retinal detachment [5]. Also, a fibrin capsule develops within hours around the foreign body, preventing its extraction with the external magnet. Moreover, during the application of the external magnet on the eye wall, significant traction may develop from the adherences between the IOFB and the retina, with high risk of iatrogenic retinal breaks. Also, if the foreign body is embedded in the retina, it cannot be extracted with the extraocular magnet. Furthermore, the IOFBs are often accompanied by vitreous haemorrhage and sometimes retinal breaks and

detachment are identified [5].

In our study, Patient 1 had pre-operative end-ophthalmitis and had positive finger following a day after, 1 and 6 weeks after the operation. In patients 11 and 14 with pre-operative endophthalmitis, hand movement close to face remained the same on Day 1 and weeks 1 and 6 post-operatively. In Patient 16 with pre-operative endophthalmitis, No projection of light as the visual outcome remained the same post-operatively on day 1, Weeks 1 and 6 that is there was no worsening. In Patients 20 and 21 with Pre-operative endophthalmitis, Projection of Lights and Rays remained the same with no worsening post operatively on Day 1, weeks 1 and 6.

In another study [6], anatomical success was achieved in 9/11 cases (81.8%). Out of the 4 cases where endophthalmitis was seen, 3 eyes had post-operative visual outcome better than 6/60 whereas one case had post-operative visual detachment and visual acuity of light perception. In another study [7], the final visual acuity was 6/12 or better in 144 eyes (48.3%), 6/12-6/60 in 90 eyes (30.2%) or less than 6/60 or less in 46 eyes (15.5%).

The use of PPV dramatically decreased the risk of retinal detachment in the period following IOFB extraction. Thus, in older studies, retinal detachment rates after primary surgery was up to 79%, whereas in more recent ones, 11-23% [5] Nicoara SD, et al. had reported in their study that, retinal detachment occurred in 1 of the 13 [5] our study has 14.28% of retinal detachment. In our study, In Patient 2 with pre-operative retinal detachment, had positive Projection of light and Projection of rays as visual outcome pre-operatively which improved to Finger following one day post-operation and gradually improved to positive finger counting at 1 meter on weeks 1 and 6. In patient 9 with pre-operative retinal detachment and 6/60 as visual outcome on Snellen's chart, improved to 6/36 on day one post-operation and slowly to 6/24 on weeks 1 and 6. In patient 10, with pre-operative retinal detachment, the patient exhibited Hand movement close to face visual outcome both Pre and post-operatively on Day 1, weeks 1 and 6. In patient 23, with Pre-operative Retinal detachment visual outcome improved from Positive Projection of Rays and Light on day 1 to Finger counting at 1 Meter on week 1 and 6 post-operatively.

We removed all the IOFBs located in the posterior segment by PPV. This attitude allowed us to identify retinal lesions that the foreign body may have produced along its trajectory and that may have been missed without PPV, and to address them adequately.

## Timing

It is agreed that IOFBs need to be removed, because of the risk of endophthalmitis (3-30% of IOFBs) and toxic reactions [5]. Timing is controversial. Previous studies showed that the delay in IOFBs removal is associated

with a higher risk of endophthalmitis [5]. Most studies recommend the prompt removal of the IOFBs, within 24-48 h after trauma [5]. This is also the approach by study by Nicoara SD, et al. [5] our study had interval of around 12 days between trauma and surgery. It may be due to the fact that our hospital is a tertiary care centre so most of the patients came as referred cases and presented late and had already developed complications. So, we had more complications like cataract, endophthalmitis etc despite of treatment with PPV.

23-gauge 3 port Pars Plana approach generally allows a less traumatic appearance, less conjunctival damage, less intraocular inflammation, and more rapid healing of sclerotomies when compared with 20-gauge PPV, although these advantages could seem irrelevant in patients with severe ocular trauma. Different studies have reported no significant difference in endophthalmitis rates between 20 and 23 gauges, thanks to improvement in wound making and trocar/cannula entry systems used. Furthermore the design of small gauge and the higher cut rates can ensure a complete vitrectomy reducing the chances of iatrogenic retinal breaks [1]. In our study, considering the facilities available a good visual outcome was achieved with 23-gauge 3-port Pars Plana vitrectomy.

### Limitations

This is a cross sectional study with a follow-up of only 6 weeks post-operatively. So long term prognosis could not be studied which would have added value to the long term usefulness of the operative approach.

### Conclusion

Intra-ocular foreign bodies are more common in young adult males. Most common foreign bodies were metallic. IOFB should be removed as early as possible to

avoid complications. Visual acuity is better after removal of IOFB by PPV.

### Conflicts of Interest

The authors declare that they have no competing interests.

### References

1. Mahapatra SK, Rao NG (2010) Visual outcome of pars plana vitrectomy with intraocular foreign body Removal through sclero-corneal tunnel and sulcus-fixated intraocular lens Implantation as a single procedure, in cases of metallic intraocular foreign Body with traumatic cataract. *Indian J Ophthalmol* 58: 115-118.
2. Rejdak R, Choragiewicz T, Wielgos JM, Wrzesinska D, Borowicz D, et al. (2017) Intraoperative macula protection by perfluorocarbon Liquid for the metallic intraocular foreign body removal during 23-gauge vitrectomy. *J Ophthalmol* 1-5.
3. Falavarjani KG, Hashemi M, Modarres M, Parvaresh MM, Naseripour M, et al. (2013) Vitrectomy for Posterior Segment Intraocular Foreign Bodies, Visual and Anatomical Outcomes. *Middle East Afr J Ophthalmol* 20: 244-247.
4. Asbell RL (2017) Coding for intraocular foreign body removal.
5. Nicoara SD, Iriescu I, Calinici T, Cristian C (2015) Intraocular foreign bodies extracted by pars plana vitrectomy: Clinical characteristics, management, outcomes and prognostic factors. *BMC Ophthalmology* 15: 151.
6. Shah RK, Byanju R, Pradhan S (2017) Management of Posterior segment intraocular Foreign body with Vitrectomy: Visual and anatomical outcome. *Journal of Universal College of Medical Sciences* 5.
7. Cillino S, Casuccio A, Di Pace F, Pillitteri F, Cillino G (2008) A five-year retrospective study of the epidemiological characteristics and visual outcomes of patients hospitalized for ocular trauma in a Mediterranean area. *BMC Ophthalmology* 8: 6.