



CASE REPORT

Non-Familial Acrokeratosis Verruciformis of Hopf: A Rare Case Report

Tummidhi Santosh^{1*} and Manoj Kumar Patro²

¹Associate Professor, Department of Pathology & Laboratory Medicine, AIIMS, Kalyani, W.B., India

²Associate professor, Department of Pathology, MKCG Medical College & Hospital, Berhampur, Odisha, India

*Corresponding author: Dr Tummidhi Santosh, MD, DNB, PDF, PDCC, MIAC, MNAMS, Associate Professor, Department of Pathology & Lab Medicine, AIIMS, Kalyani, W.B., India



Abstract

Background: Acrokeratosis verruciformis of Hopf is a rare genodermatosis with an autosomal dominant mode of inheritance. It is a disorder of keratinization, characterized by multiple, flat-topped, skin-coloured keratotic lesions resembling plane warts typically observed on the dorsum of the hands and feet.

Case presentation: We report a rare sporadic case of a 36-year-old Hindu male presented with multiple, grouped, hyperkeratotic, whitish, flat papules on the dorsum of the palm, which had been present for more than one year. Histopathological examination showed typical findings of acrokeratosis verruciformis of Hopf. Our case is unique because the patient had no familial history of similar skin lesions.

Discussion & conclusion: Histopathologically, these lesions show considerable hyperkeratosis, acanthosis, and papillomatosis, mimicking a “church spire”, and a thickened granular layer. It arises in early life, often at birth or infancy.

Keywords

Non-familial acrokeratosis verruciformis, Hopf disease, Church spire

Introduction

Acrokeratosis verruciformis (AKV) is a rare hyperkeratotic genodermatosis that was first described by Hopf in 1931 [1]. It typically presents as multiple, small, flat, wart-like papules on the dorsum of the hands and feet and arises in early life often at birth or infancy with no sexual predilection [2,3]. Histologically, it is characterized by hyperkeratosis without parakeratosis, marked papillomatosis without vacuolization, which resembles a “church spire”. It exhibits an autosomal

dominant inheritance pattern and shows incomplete penetrance. Because of this, there may not always be a family history. However, a few sporadic cases have also been reported [4]. We herein report on a rare case of AKV, which developed in a young adult without familial history.

Case History

We report a rare sporadic case of a 36-year-old Hindu male presented with multiple raised skin-coloured lesions in his hand and trunk which had been present for more than one year. On examination, the lesions were multiple brownish bullous papules to plaque-like grouped, hyperkeratotic, whitish, flat papules on the bilateral dorsum of the hands. The lesions in the trunk were more flat skin coloured to hyper pigmented lesions of 2-5 mm size. Palmer’s aspect was spared (Figure 1). There were no complaints of itching, pain or burning sensation. The lesion did not have any seasonal variations or any systemic complaints. The Fitzpatrick skin type in our patient was V. Skin sensitivity test for the possibility of allergic dermatitis was done and negative. Clinical differentials were epidermodysplasia verruciformis, Darier’s disease, and AKV.

Skin punch biopsy from the macule over the left hand was taken. Histopathology showed an epidermis with compact hyperkeratosis, acanthosis, papillomatosis, mild spongiosis, and a thickened granular layer. The typical circumscribed epidermal elevation “Church Spire-like pattern” was noted, with the absence of parakeratosis (Figure 2). No intracytoplasmic inclusions, corps/rounds were noted. The papillary dermis showed



Citation: Santosh T, Patro MK (2024) Non-Familial Acrokeratosis Verruciformis of Hopf: A Rare Case Report. Int J Pathol Clin Res 10:149. doi.org/10.23937/2469-5807/1510149

Accepted: May 16, 2024; **Published:** May 18, 2024

Copyright: © 2024 Santosh T, et al. This is an open-access article distributed under the terms of the Creative Commons Attribution License, which permits unrestricted use, distribution, and reproduction in any medium, provided the original author and source are credited.

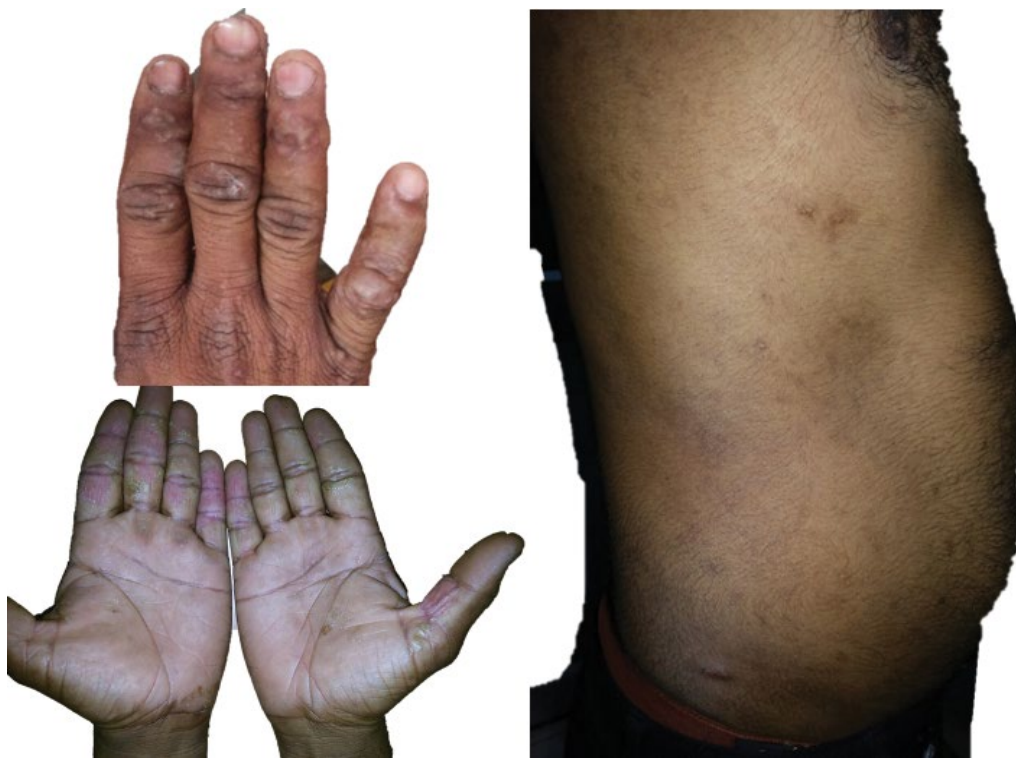

Figure 1: Numerous variably sized flesh hyperkeratotic papules on the dorsal aspect of hand, and trunk along with sparing of palm.

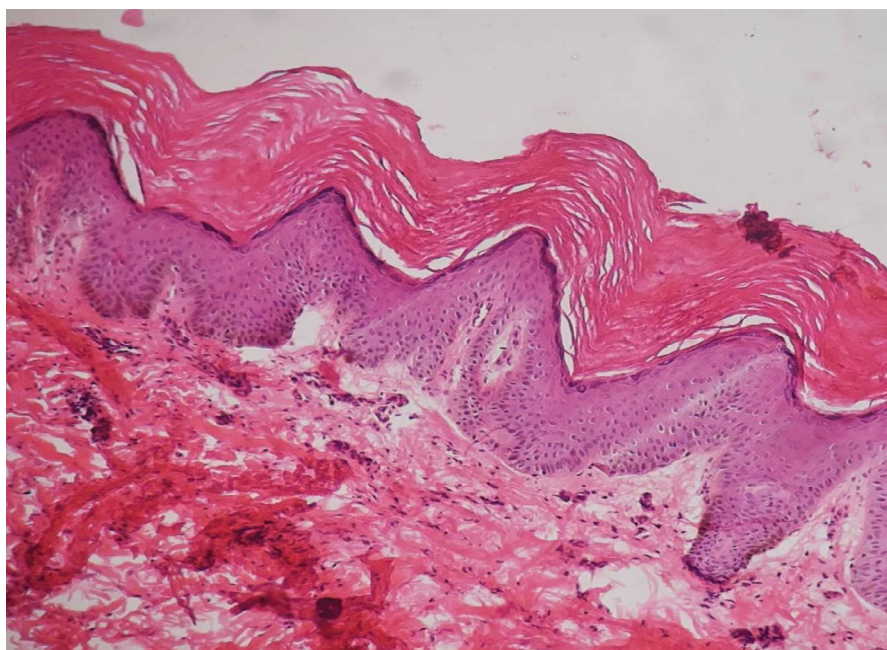


Figure 2: Sections examined show epidermis with hyperkeratosis, acanthosis and hypergranulosis, and papillomatosis with a "church spire" pattern (H&E, $\times 20$).

mild oedema with sparse perivascular lymphocytic cuffing. The reticular dermis and sub cutis were unremarkable (Figure 3). Based on the clinical and histopathology findings, a diagnosis of Acrokeratosis verruciformis of Hopf. Given financial constraints the patient was not able to undergo genetic testing.

Discussion

AKV is a rare genodermatosis that develops at birth

or during early childhood. However, non-familial cases like our case have been reported in the literature [4,5]. Characteristic findings of AKV include asymptomatic flesh-coloured or reddish-brown flat papules resembling flat warts. Typically it arises in the dorsal aspect of the hands, and feet. It may extend to the forearms and lower legs. Punctate keratoses of the palms and soles have often been detected in AKV. Clinically, they can be confused with verruca plana, lichen planus,

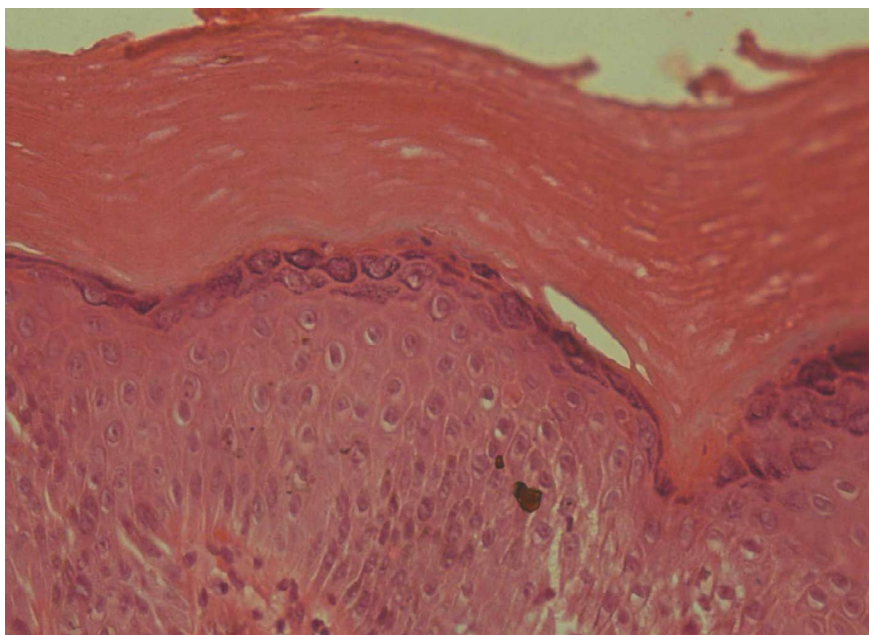


Figure 3: The section examined shows pure compact hyperkeratosis, acanthosis, and papillomatosis without parakeratosis, dyskeratosis, and vacuolization (H&E, ×40).

epidermodysplasia verruciformis, especially with Darier's disease [1].

The pathogenesis behind AKV is the same as that of Darier's disease with minor allelic variation. The P602L mutation in ATP2A2 leads to defective calcium transport in the endoplasmic reticulum. This defect causes disordered keratinization leading to verrucous lesions and papules on the hand and feet. Given a dominant mutation, the disease has a chronic course without remission [1]. There have been reports of HPV-17 association with AKV and rarely malignant transformation to squamous cell carcinoma [5].

Histopathologically, AKV shows an exaggeration of the epidermal layer and thickening of the granular layer. These layers show a blunt domed pattern within concavities of the wavy stratum corneum, a so-called "church spire" [6]. There can be some degree of acantholysis, but not parakeratosis, dyskeratosis, or basal layer change. Clinically mimicking diseases can be ruled out with histopathologic findings. The hypertrophic variant of seborrheic keratosis might present an identical histological finding; however, clinical findings of seborrheic keratosis are far from those of AKV [7].

As a result of similar clinical and histologic findings, some authors have suggested a possible relationship between AKV and Darier's disease. Histopathologically, AKV may be distinguishable from Darier's disease. The unique finding of AKV is a "church spire"; otherwise, Darier's disease is benign dyskeratosis with corps round [1].

In terms of the clinical features and histopathological findings, there is no difference between familial AKV and non-familial cases. Clinically, both show asymptomatic

flesh-coloured to reddish-brown flat papules resembling flat warts on the dorsal palm and trunk. In addition, there is a histologically unique finding of a "church spire" [6]. In our case, the late onset age and absence of a familial history were confusing; however, with the typical clinical and histopathological findings, we were able to diagnose our patient as non-familial AKV.

We found eight previously reported cases of sporadic AKV in English literature (Table 1). Like ours all these cases showed typical clinical and histopathological findings and lacked a familial history. The onset age of classical AKV is different from that of sporadic AKV. Classical AKV often occurs during childhood; however, the onset age of sporadic AKV is much later than that of classical AKV. In addition, palmar and plantar keratoses have frequently been reported in classical AKV, 12, but not in sporadic AKV.

The differentials for AKV include EDV, Darier disease, verruca plana, lichen planus, and seborrheic keratosis. However, the lack of crops and roads, viral cytopathic changes in the granular layers, lichenoid changes, and comedo-like openings with milia cysts help diagnose AKV [1,7].

Superficial ablation has been reported to be effective in AKV. Other methods include cryotherapy, laser therapy, keratolytic solution, and surgical excision. The use of oral isotretinoin has been suggested. Regular follow-up is needed to prevent the possibility of a rare chance of transformation to squamous cell carcinoma [1,8,9].

Conclusion

AKV is a rare genodermatosis that usually develops

Table 1: Sporadic cases of AKV.

Case	Author	Onset of age	Site	Palmo-plantar pitting	Nail involvement
1	Schuller, et al.	40	Dorsal feet and anterior aspect of the legs	Scattered punctate keratosis on the palm	Brittle, but not to an unusual degree
2	Berk, et al.	11	Dorsal hand, wrist feet and ankle	Not involved	Not involved
3	Farro et al	56	Extremities	Not involved	Not involved
4	Serarslan, et al.	14	Dorsal hands and feet	Not involved	Not involved
5	Kaliyadan, et al.	20	Chiefly over the limbs with scattered lesions over the forearms	No other significant skin lesions	No other significant skin lesions
6	Wang, et al	45	Dorsal hand and extensor aspects of forearms	Not involved	Not involved
7	Bang, et al.	44	Dorsal feet and anterior aspects of legs	Not involved	Not involved
8	Faina, et al.	52	Dorsal hand	Not involved	Not involved
9	Present case	36	Dorsal hand, trunk	Not involved	Not involved

in childhood but has rarely been reported in adulthood. Histopathologically, these lesions show considerable hyperkeratosis, acanthosis, and papillomatosis, mimicking a “church spire”, and a thickened granular layer. Superficial ablation has been reported to be effective.

Declarations

Ethics approval and consent to participate

Not applicable.

Consent for publication

Written informed consent was obtained from the patient to publish this case report and any accompanying images. A copy of the written consent is available for review by the Editor-in-Chief of this journal.

Availability of supporting data

All the data regarding the findings are available within the manuscript.

Competing interests

The authors declare that they have no competing interests.

Funding

Not applicable.

Authors' contributions

TS carried out concepts & design, literature search, participated in clinical study and will stand as guarantor also. MKP carried out data acquisition, data analysis & manuscript preparation. All the authors have read & approved the final manuscript.

Acknowledgements

Not applicable.

References

- Hopf G (1931) Über eine bisher nicht beschriebene disseminierte. Keratose (Akrokeratosis verruciformis). *Dermatologische Zeitschrift* 60: 227-250.
- Williams GM, Lincoln M (2023) Acrokeratosis verruciformis of hopf. In: *Stat Pearls, Treasure Island (FL): Stat Pearls Publishing*.
- Verma J, Gopinath H, Josephain K, Bharti JN, Santosh T (2022) Acrokeratosis verruciformis of hopf in an adult - a rare case report with review of literature. *Indian J Dermatol* 67: 792-794.
- Bang CH, Kim HS, Park YM, Kim HO, Lee JY (2011) Non-familial acrokeratosis verruciformis of hopf. *Ann Dermatol* 23: S61-S63.
- Matsumoto A, Gregory N, Rady PL, Tyring SK, Carlson JA (2017) Brief report: HPV-17 infection in darier disease with acrokeratosis verruciformis of hopf. *Am J Dermatopathol* 39: 370-373.
- Faina V, Magri F, Sernicola A, Chello C, Gagliostro N, et al. (2019) Late-onset non-familial acrokeratosis verruciformis of Hopf: A case report. *Clin Ter* 170: e418-e420.
- Ranjan E, Sandhu S, Sharma AS (2023) Acrokeratosis verruciformis of Hopf: A series of 3 cases with clinical, histopathological and dermoscopic features. *Indian J Dermatol* 68: 489.
- Lohanee K, Thapa DP (2021) Acrokeratosis verruciformis of hopf: An unusual presentation. *Indian Dermatol Online J* 12: 928-929.
- Genedy R, Taha A (2021) Acrokeratosis verruciformis of hopf: Dermoscopic and histopathological study of two sibilings. *Clin Exp Dermatol* 46: 1313-1314.