



CASE REPORT

Incidental Extra-Colonic Findings in CT Colonography at Riyadh Region

Muhannad Alanazi^{1*} and Nasir Ahmed Ali²

¹Department of Radiology, Aljouf University, Saudi Arabia

²Department of Health Education and promotion, Jazan University, Saudi Arabia

*Corresponding author: Muhannad Alanazi, Department of Radiology, Aljouf University, Aljouf City, Saudi Arabia



Abstract

Introduction: Computed tomography colonography (CTC) is a new radiologic technique for examination of the colorectum. The search for, analysis and interpretation of extra-colonic findings (ECFs) are a matter of permanent debate and review, given the arguments for and against them.

Objective: To assess the prevalence and type of extracolonic findings (ECFs) in a screening population undergoing computed tomography colonography (CTC) in Riyadh region.

Methods: This retrospective study was conducted in Riyadh region. To achieve the objectives of this study 305 subjects medical records were reviewed, where male represented 55% of participants and female represented only 45%.

Results: About 21% of subjects had any type Extra Colonic Findings (ECFs) where about 74 incidental findings were identified in 65 patients. Out of these findings; 6 patients (9%) required immediate medical attention or urgent imaging/intervention, these included high suspicious of extracolonic malignancy or active infection, 16 patients (25%) required either further imaging and characterization, or follow up imaging, these included undetermined masses or nodules, while 43 patients (66%) required either reassurance or life style modification, which included extensive atherosclerotic changes, fatty liver or spondylolisthesis.

Conclusion: Colon cancer is one of the leading causes of mortality and morbidity in our Saudi Arabia community. Early detection of colon cancer and its precursor (i.e. polyps) is essential for successful management.

Keywords

Computed tomography colonography (CTC), Extracolonic findings (ECFs), Riyadh region, Saudi Arabia

Introduction

Many years ago, the first human trials of virtual colonoscopy, or computed tomography (CT) colonography, were performed [1]. CT colonography (CTC), as it is now called, is a low radiation dose CT examination of the abdomen and pelvis following bowel purgation cleansing and colon and rectum inflation. High spatial resolution CT datasets of the abdomen and pelvis are obtained in position that patient is lying in the prone and supine positions, with the entire procedure lasting about ten minutes. The conducted images are interactively reviewed on a dedicated computer workstation using 2D multiplanar images and 3D endoluminal displays of the colon. Over the past decade, rapid technological advancements in image acquisition, 3D display techniques, colonic insufflation, and stool tagging (i.e., labeling of stool with ingested radio-opaque contrast) have occurred, which have greatly improved the ability of CT colonography to detect colorectal polyps and cancer.

Study Importance

Probably due to physician-researchers conducting early CT colonography research, the importance of incidental findings (IFs) discovered during CT colonography was quickly recognized. Several early studies suggested that the incidence of extracolonic findings that require further medical investigation or medical/operative treatment was 10-11 percent and surpassed the incidence of large colorectal polyps in asymptomatic research subjects undergoing CT colonography [2].

Moreover, while the benefits of identifying extracolonic findings were potentially life-saving in a small

percentage of patients (0.5-1.3 percent) [3], such benefit came with a cost and potential morbidity [4]. From perspective of an individual patient's, the medical procedures follows the recognition of a significant extra-colonic incidental researches finding can be dramatic, often necessitating further imaging, or less likely, invasive or surgical techniques. On other hand imaging studies can frequently be conducted to quickly arrive at a definitive diagnosis, the medical procedure scan be protracted and require long-term imaging follow up. These procedures may also result in morbidity if invasive procedures are employed.

The Study Objectives

- To assess the prevalence of extracolonic findings (ECFs) in a screening population undergoing computed tomography colonography (CTC).
- To identify the type of extracolonic findings (ECFs).

Literature Review

Computed tomography colonography (CTC) is a new radiologic technique for examination of the colorectum. The examination usually is performed in the prepared colon by using a low-dose CT technique in both supine and prone positions [4-6]. By using advanced imaging software (axial and multiplanar 2-dimensional reformatting and 3-dimensional-endoluminal view), images of the colon are reviewed to provide a thorough and non-invasive evaluation of the entire colorectum [4-7]. Recent studies indicate CTC likely will be competitive with other full structural examinations of the colorectum [4,5,8]. A unique capability of CTC over other colorectal examinations is the display of the entire abdominal and pelvic contents [9]. Detection of important abdominal

and pelvic extracolonic abnormalities could potentially benefit patients undergoing colorectal screening. At risk is the possible increase in the cost of this examination by the discovery and work-up of clinically insignificant findings. Several reports of extracolonic findings at CTC have been published, but none exist in a screening population that most likely might benefit from the procedure [9,10] (Table 1).

Subjects and Methods

This was a retrospective study was conducted in King Faisal specialist hospital and research center in Riyadh, between 2007-2017 where the medical records of 305 patients who underwent screening CT colonography were reviewed for the purpose of this study. All participants were screened using the virtual colonoscopy program to ensure that the indication for CTC is appropriate. Many demographic characteristics of participants such as (age and gender) were obtained.

Incidental extra-colonic findings (IECF) were collected and categorized into the following groups: (1) Needs immediate clinical attention or urgent dedicated imaging, (2) Needs further imaging characterization of the findings in routine bases, or (3) Needs reassurance and life style modification, incidental findings which did not carry clinical significance were not included.

Ethical Considerations

All ethical issues were considered during the process of this study.

Results

As shown in Figure 1, male represented 55% of participants while female represented only 45%.

Table 1: ECF classification.

Importance	Definition	Examples
Low/Null	Disorders considered benign, which hardly require further workups	<ul style="list-style-type: none"> • Vascular calcifications • Granulomas • Diverticulosis • Simple cysts in solid organs • Small or middle hiatal hernias • Fatty abdominal hernias
Moderate	Disorders that do not require immediate treatment, but probably necessitate further research or treatment in the future	<ul style="list-style-type: none"> • Stones in different organs • Adrenal masses • Pancreatic pseudocysts • Indeterminate cyst formations • Uterine enlargement in postmenopausal women • Coronary calcifications
High	Disorders requiring surgical procedures, medical treatment or further workups	<ul style="list-style-type: none"> • Indeterminate masses in solid organs • Unknown AAA > 3 cm • Aneurysms in renal or splenic arteries • Indeterminate pulmonary nodules • Adenomegalies • Pancreatic masses

Source: Andrés J Quaranta, et al. RAR - Volume 75 - Número 2 - 2011.

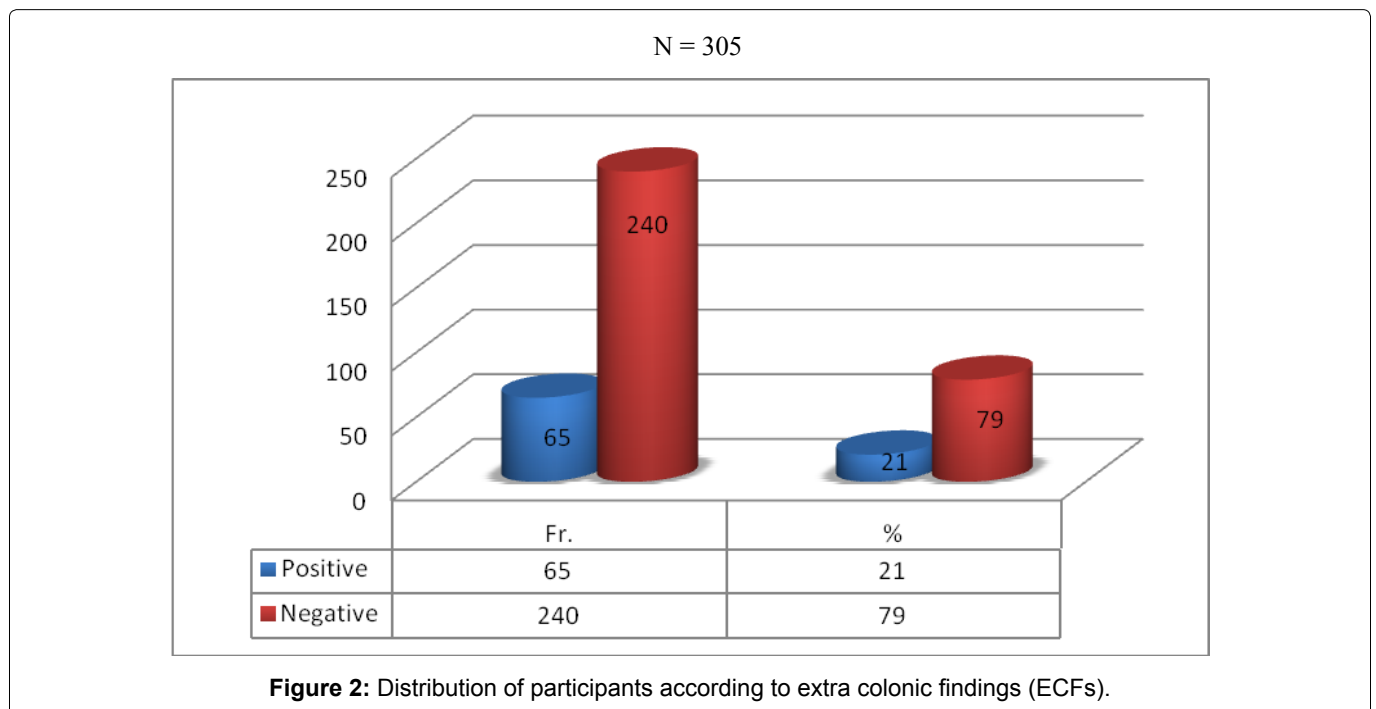
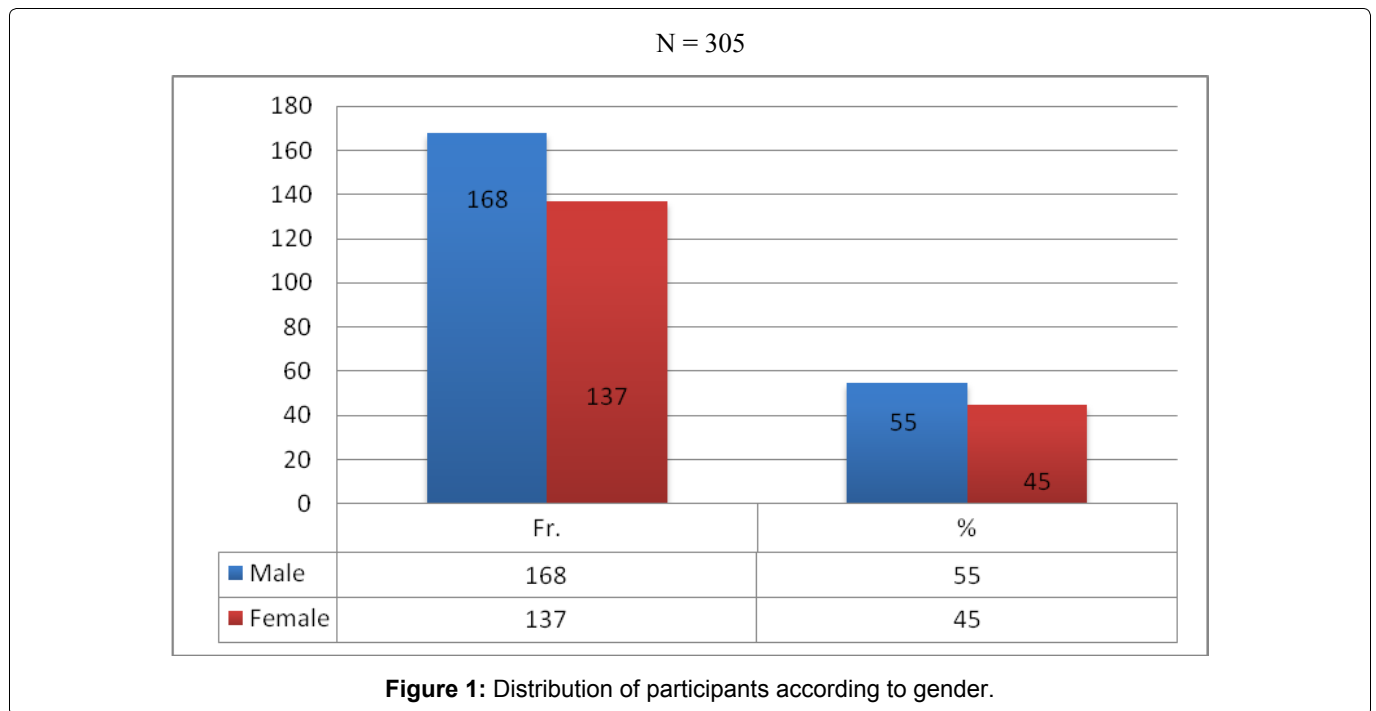


Table 2: Distribution of participants according to action required for extra colonic findings (ECFs).

N = 65				
Action required for extra colonic findings (ECFs)	Fr.	%	Finding at CTC	Total incidental findings
Required immediate medical attention or urgent imaging/ intervention	6	9	High suspicious of extra-colonic malignancy or active infection	74
Further imaging and characterization, or follow up imaging	16	25	Undetermined masses or nodules	
Reassurance or life style modification	43	66	Extensive atherosclerotic changes, fatty liver, spondylolisthesis	

As shown in Figure 2, 21% of participants had any type Extra Colonic Findings (ECFs).

As mentioned in Table 2, about 74 incidental findings were identified in 65 patients. Out of these findings; 6 patients (9%) required immediate medical attention or urgent imaging/intervention, these included high suspicious of extracolonic malignancy or active infection, 16 patients (25%) required either further imaging and characterization, or follow up imaging, these included undetermined masses or nodules, while 43 patients (66%) required either reassurance or life style modification, which included extensive atherosclerotic changes, fatty liver or spondylolisthesis.

Discussion

This retrospective study was conducted in Riyadh region to assess the prevalence of extracolonic findings (ECFs) in subjects who undergoing computed tomography colonography (CTC) and to identify the type of extracolonic findings (ECFs). To achieve the objectives of this study 305 subjects medical records were reviewed, where male represented 55% of participants and female represented only 45%, 21% of subjects had any type Extra Colonic Findings (ECFs) where about 74 incidental findings were identified in 65 patients. Out of these findings; 6 patients (9%) required immediate medical attention or urgent imaging/intervention, these included high suspicious of extracolonic malignancy or active infection, 16 patients (25%) required either further imaging and characterization, or follow up imaging, these included undetermined masses or nodules, while 43 patients (66%) required either reassurance or life style modification, which included extensive atherosclerotic changes, fatty liver or spondylolisthesis.

Similar study conducted by Hassan Siddiki and his colleagues [1] in 2008 found Significant extracolonic findings requiring further investigation or medical or surgical intervention 8% of subjects and 19% of subjects who need subsequent medical or surgical intervention. In a Danish population consisting of asymptomatic patients undergoing polyp/cancer surveillance, B Ginnerup Pedersen, et al. [11] in 2003 found extracolonic abnormalities by MDCTC in 65% of cases, with the need for further workup in 12% and surgery in 3%. In an American population consisting of patients undergoing CRC Hara, et al. [6] found incidental extracolonic findings in 41% of 264 patients and "highly important" findings in 11% of patients underwent additional workup and 2% underwent surgery.

Conclusions

Colon cancer is one of the leading causes of mortality and morbidity in our Saudi Arabia community. Early detection of colon cancer and its precursor (i.e. polyps) is essential for successful management. The American Cancer Society recommended screening of colon can-

cer starting at the age of 50 years by either; Flexible sigmoidoscopy every 5 years, Colonoscopy every 10 years, Double-contrast barium enema every 5 years, or CT colonography (virtual colonoscopy) every 5 years. CT colonography has emerged as a non-invasive modality for colon cancer screening with good sensitivity. The application of CT allows for detection of incidental extra-colonic pathology. The aim of our study is to determine the incident of these incidental findings and further categorizes them according to their clinical significance.

Acknowledgements

I would like to thanks all people who contribute and help in conducting this research, special thanks to manager and staff of King Faisal specialist hospital and research center in Riyadh for their cooperation during study period.

References

- Hassan Siddiki, JG Fletcher, Beth McFarland, Nora Dajani, Nicholas Orme, et al. (2008) Incidental findings in CT colonography literature review and survey of current research practice. *J Law Med Ethics* 36: 320-331.
- Thomas M Gluecker, C Daniel Johnson, Lynn A Wilson, Robert L Maccarty, Timothy J Welch, et al. (2003) Extracolonic findings at CT colonography: Evaluation of prevalence and cost in a screening population *Gastroenterology* 124: 911-916.
- Perry J Pickhardt, Andrew J Taylor (2006) Extracolonic findings identified in asymptomatic adults at screening CT colonography. *AJR Am J Roentgenol* 186: 718-728.
- Fenlon HM, Nunes DP, Schroy PC, Barish MA, Clarke PD, et al. (1999) A comparison of virtual and conventional colonoscopy for the detection of colorectal polyps. *N Engl J Med* 341: 1496-1503.
- Fletcher JG, Johnson CD, Welch TJ, MacCarty RL, Ahlquist DA, et al. (2000) Optimization of CT colonography technique: Prospective trial in 180 patients. *Radiology* 216: 704-711.
- Hara AK, Johnson CD, MacCarty RL, Welch TJ, McColough CH, et al. (2001) CT colonography: Single- versus multi-detector row imaging. *Radiology* 219: 461-465.
- Reed J, Johnson C (1997) Automatic segmentation, tissue characterization, and rapid diagnosis enhancements to the computed tomographic colonography analysis workstation. *J Digit Imaging* 10: 70-73.
- Yee J, Akerkar GA, Hung RK, Steinauer-Gebauer A, Wall SD, et al. (2001) Colorectal neoplasia: Performance characteristics of CT colonography for detection in 300 patients. *Radiology* 219: 685-692.
- Hara AK, Johnson CD, MacCarty RL, Welch TJ (2000) Incidental extracolonic findings at CT colonography. *Radiology* 215: 353-357.
- Edwards JT, Wood CJ, Mendelson RM, Forbes GM (2001) Extracolonic findings at virtual colonoscopy: Implications for screening programs. *Am J Gastroenterol* 96: 3009-3012.
- B Ginnerup Pedersen, M Rosenkilde, TEM Christiansen, S Laurberg (2003) Extracolonic findings at computed tomography colonography are a challenge. *Gut* 52: 1744-1747.