



## CASE REPORT

# Aids and Non-Hodgkin Lymphoma: Report of a Case


López de la Cruz Denisse<sup>1</sup>, Azucena Casanova Lara<sup>2</sup> and María Valeria Jiménez Báez<sup>3\*</sup>

<sup>1</sup>Resident of Internal Medicine of the Regional General Hospital No. 17, Cancun, Quintana Roo of the Mexican Institute of Social Security, Mexico

<sup>2</sup>Department of endoscopy and colonoscopy of the General Hospital No. 17, Cancun, Quintana Roo of the Mexican Institute of Social Security, Mexico

<sup>3</sup>Headquarters of medical benefits of the Mexican Institute of Social Security, Planning Coordination and Institutional Liaison, Mexican Social Security Institute, Mexico

**\*Corresponding author:** María Valeria Jiménez Báez, Headquarters of medical benefits of the Mexican Institute of Social Security. Planning Coordination and Institutional Liaison, Mexican Social Security Institute, Av. Politécnico Nacional s/n entre Tepic y Kinic, Cancún, Quintana Roo, Mexico



## Introduction

AIDS (Acquired Immunodeficiency Syndrome) is a condition caused by the Human Immunodeficiency Virus (HIV). HIV is a virus that attacks the immune system and weakens the body's ability to fight off infections and diseases. Approximately 37.6 million people (about twice the population of New York) worldwide are infected with the human immunodeficiency virus (HIV) according to data from the Joint United Nations Program on HIV-AIDS [1].

Malignant neoplasms are one of the leading causes of hospitalization and death in the HIV-infected population. The HIV mortality rate is 3.62 people per 100,000 inhabitants, 6.19 in the case of men and 1.17 for women [2]. The highest are registered in Quintana Roo with 10.25, Colima 9.40 and Campeche with 7.25 deaths per 100,000 inhabitants in each entity [2].

A study carried out by Rivera in Mexico in 2020 found that HIV-associated cancer was more frequent in men, at the colon and rectal level. The most common histological type was squamous cell adenocarcinoma (patients with good adherence to treatment), followed by non-Hodgkin lymphoma and Kaposi's sarcoma (patients with poor adherence or no treatment) [3].

The most frequent neoplasms are gastrointestinal, which are divided into two groups: AIDS-defining neoplasms: Kaposi's Sarcoma and Non-Hodgkin's

Lymphoma (which are considered opportunistic tumors) and in second place are non-defining neoplasms: bronchopulmonary, anal, and hepatocellular [4]. Non-Hodgkin Lymphoma (NHL) is a type of cancer that affects the lymphatic system, which is part of the immune system. People living with HIV are at a higher risk of developing NHL due to their weakened immune system. NHL can occur in different parts of the body and can cause symptoms such as swollen lymph nodes, fever, night sweats, and weight loss. Given the enormous number of people infected with HIV that currently exist, it is considered a high-impact and high-cost disease, for which the objective is to minimize the effects of HIV-AIDS infection [5].

The purpose of this study is to present a case of an AIDS patient with Non-Hodgkin Lymphoma with a fatal outcome.

## Case Description

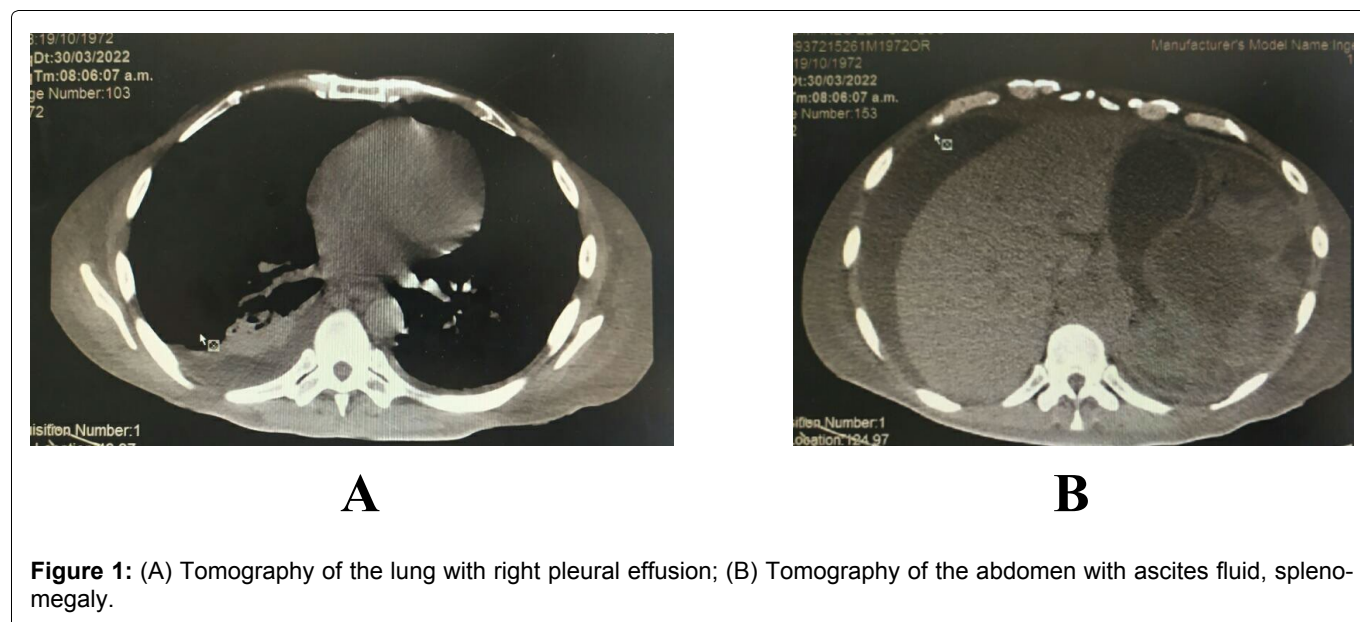
A 49-year-old male resident of Cancun has the following significant history: full immunization, SARS-CoV-2, 2 AstraZeneca doses, previous hospitalizations on two occasions in the last three years for pneumonia, transfusions in March 2022 for anemia, alcoholism for 29 years at a rate of 14 gr/day suspended 8 months ago. HIV positive for 20 years with intermittent adherence to treatment, currently with a third treatment scheme with ritonavir, darunavir, dolutegravir and tenofobir with emtricitabine.



**Citation:** Denisse LC, Lara AC, Báez MVJ (2023) Aids and Non-Hodgkin Lymphoma: Report of a Case. Int J Virol AIDS 10:087. doi.org/10.23937/2469-567X/1510087

**Accepted:** June 13, 2023; **Published:** June 15, 2023

**Copyright:** © 2023 Denisse LC, et al. This is an open-access article distributed under the terms of the Creative Commons Attribution License, which permits unrestricted use, distribution, and reproduction in any medium, provided the original author and source are credited.



**Figure 1:** (A) Tomography of the lung with right pleural effusion; (B) Tomography of the abdomen with ascites fluid, splenomegaly.

The current condition begins by presenting a productive cough with whitish expectoration, unquantified fever, asthenia, adynamia, weight loss of 10 kg in 3 months, intolerance to the oral route, hair, and fetid evacuations. On physical examination: No neurological compromise, cachectic, pale integuments, tachypnoea, 82% oxygen saturation, globose abdomen, no palpable megalias, matte, decreased peristalsis, extremities with ++ edema, 2-second capillary refill.

Complementary studies: Laboratories: leukocytes  $18.7 \times 10^3/\text{ul}$ , hemoglobin 10.8 g/dl, platelets  $357 \times 10^3/\text{ul}$ , lymphocytes 2.8%, lymphocytes  $0.52 \times 10^3/\text{ul}$ , CD4 T lymphocytes 8.63%, lymphocyte count 42.86 ul, HIV viral load 57.1 copies/ml.

Abdominal-pelvic tomography: minimal right effusion and ipsilateral basal consolidation area, retentionist stomach, splenomegaly with areas of hypodensity inside, probable cysts, abundant ascites fluid, probable cystic left testicular lesion, and abundant abdominal and inguinal lymph node conglomerates (Figure 1).

Endoscopy: Probable ulcerated activity, penetrated the duodenum with intestinal occlusion. Duodenal biopsy with atypical lymphocytic proliferation. The diagnosis of stage 3 AIDS was integrated, due to probable non-Hodgkin lymphoma, bacterial pneumonia. Treatment of pathology, pneumonia, with antibiotics with cephalosporins, is scheduled for gastrostomy and the biopsy result is awaited to request evaluation by medical oncology, however, he presents a torpid evolution and dies before receiving histopathology results.

## Discussion

The human immunodeficiency virus is not an oncogenic virus; however, segments in its genome seem to be involved in the growth of Kaposi's sarcoma cells. Its presence conditions a stimulus in B lymphocytes,

altering antitumor activity, indirectly facilitating oncogenic viruses [5]. There are several factors that increase the risk of developing NHL in people living with HIV. One of the main factors is the degree of immune suppression. The lower the CD4 cell count (a type of immune cell), the higher the risk of NHL. People living with HIV who have not started antiretroviral therapy (ART) or have a low CD4 cell count are at a higher risk of developing NHL. Other factors that increase the risk of NHL in people living with HIV include co-infection with other viruses such as hepatitis B and C, Epstein-Barr virus (EBV), and human herpesvirus 8 (HHV-8). Lifestyle factors such as smoking and alcohol use may also increase the risk of NHL in people living with HIV.

It has been found that there are factors associated with an unfavorable prognosis such as age over 35 years at the time of diagnosis, intravenous drug use, advanced stages, CD4 count less than 100 uL [6].

In Mexico, the mortality rate from malignant tumors for the year 2019 is 70 deaths per 100,000 inhabitants. In Quintana Roo, rates of 50.93 to 62.44 are registered. There are currently no records of the percentage of non-Hodgkin lymphoma in the Mexican population [6].

The association of HIV and cancer is more frequent. The predominant ones in one stage of AIDS include Kaposi's disease and non-Hodgkin's lymphoma [7]. In this case, although the immunohistochemical study is not reported, due to the symptoms presented by the patient, the first pathological report, and the statistics make us suspect the presence of non-Hodgkin lymphoma.

There are currently no standard diagnostic tests for the diagnosis of HIV-associated cancer. Monitoring of HIV patients is performed by measuring CD4 lymphocyte levels and viral load. A lower level of CD4 lymphocytes than 200 ul cells has been associated with the presence of AIDS-defining neoplasms [8,9].

The patient reported adequate adherence to current antiretroviral treatment but had periods of absence from treatment. His CD4 count at the time of the symptoms of the current condition was less than 100 ul, predisposing to decreased immunity, which in turn favors the appearance of so-called opportunistic neoplasms [4,10].

The treatment of neoplasms is based on the origin of the neoplasm itself, the appropriate use of antiretrovirals and the prophylaxis and treatment of opportunistic diseases. Treatment for NHL in people living with HIV involves a combination of chemotherapy and ART. The chemotherapy drugs used to treat NHL can cause side effects such as nausea, vomiting, and hair loss. However, with proper medical care and treatment, people living with HIV can live long and healthy lives with NHL.

It should be noted that the clinical presentation of non-Hodgkin lymphoma is atypical, it does not have specific symptoms, often due to the appearance of masses, depending on the location and the symptoms it produces. In this case, it generated data of intestinal obstruction, which was the reason for performing an endoscopy.

The patient was in the AIDS stage due to the presence of neoplasia and according to the CD4 count, the diagnostic protocol was started, with a torpid evolution without being able to offer further treatment for the neoplasia.

Until now, little is known about the prognosis and influencing factors before and after cancer diagnosis in patients with HIV, which makes diagnostic methods difficult [9]. AIDS and Non-Hodgkin Lymphoma are two conditions that are closely linked. People living with HIV are at a higher risk of developing NHL due to their weakened immune system. The risk of developing NHL increases with the degree of immune suppression and other factors such as co-infection with other viruses and lifestyle factors [1,11-29].

## Conclusions

The high mortality of patients with HIV, the atypical presentation of neoplasms in them and late diagnosis guide us to the importance of prioritizing preventive measures for the general population against HIV, secondary prevention in patients with HIV for adequate adherence to antiretroviral treatment and decreased exposure to oncogenic agents.

## Declaration of Conflict of Interest

The authors declare no conflict of interest in this review.

## Sources of Funding

The authors received no funding for this case presentation.

## References

- Bravo-García E, Magis-Rodríguez C, Palacios-Martínez M, Guarneros-Soto N, Uribe-Zúñiga P (2020) La mortalidad por VIH en las jurisdicciones sanitarias de México de 1990 a 2015. *61*: 563-571.
- Arias-Rodríguez C, Beuth-Ruiz S, Correa L, David Puerta J, Forero S (2022) Neoplasias cutáneas asociadas con el virus de la inmunodeficiencia humana (VIH). *Dermatol Rev Mex* 66: 350-363.
- Rivera Flores AG, González Angulo Rocha JA, Zamarripa-Dorsey F, Mejía Loza SMI (2020) Frecuencia y comportamiento epidemiológico e histológico en las neoplasias gastrointestinales asociadas a los pacientes portadores de VIH en el Hospital Juárez de México. *Acta Gastroenterol* 50.
- Domblides C, Canellas A, Wislez M, Fallet V, Antoine M, et al. (2018) Le cancer bronchopulmonaire chez les patients infectés par le VIH. *Bull Cancer* 105: 111-119.
- Reyes Ríos LÁ, Campo Torregroza E, Espinosa Aguilar A, Granados Pérez A, Gil Ruiz ID (2020) Adherencia al tratamiento antirretroviral en personas con VIH/sida de la región Caribe - colombiano. *Rev cuba hig epidemiol* 57.
- Organización Mundial de la Salud (2019) Cáncer.
- Betancourt Gambino Johan (2018) Cáncer en pacientes viviendo con VIH/sida. *Rev Cubana Med Gen Integr* 34: 1-9.
- Mamadou T, Assetou S, Bacari D, Hamsetou C, Garan D, et al. Cancers associes a l'infection a vih: caracteristiques epidemiologiques, cliniques, et devenir des patients dans le service de maladies infectieuses de bamako. *Mali Medical* 36: 50-53, 4p.
- Lucía Maryelena M-M, Jim Brian V-M, Gotuzzo Eduardo, Fernando Alonso M-C, Elsa Violeta G-L (2021) Cáncer en personas que viven con VIH-SIDA en un hospital público de referencia en Perú. *Rev Perú Med Exp Salud Publica* 38: 278-283.
- Abbar B, Veyri M, Solas C, Poizot-Martin I, Spano J-P (2020) VIH et cancer : mise au point en 2020 HIV and cancer: Update 2020. *Bull Cancer* 107: 21-29.
- Fernández-Ruiz A, Sanjoaquín-Conde I, Letona-Carbajo S, Lambea-Sorrosal JJ, Crusells-Canales MJ (2020) Diferencias en supervivencia según el tipo de cáncer y el grado de inmunodeficiencia en pacientes con infección VIH. *Med Clin* 154: 295-300.
- Urizar C, Jarolin M, Ayala N, Centurion C, Montiel D (2020) Factores asociados a la no adherencia del tratamiento antirretroviral en pacientes con VIH en un hospital de Paraguay. *Revista Científica Ciencia Médica* 23: 166-174.
- Del Moral-Trinidad LE, Silva-Bañuelos G, Campos-Uscanga Y (2020) Factores asociados al fracaso terapéutico en personas viviendo con VIH con tratamiento antirretroviral: una revisión panorámica de la literatura. *Rev Cubana Med Trop* 74: 699.
- Aydin OA, Gunduz A, Sargin F, Mete B, Karaosmanoglu HK, et al. (2020) Prevalence and mortality of cancer among people living with HIV and AIDS patients: a large cohort study in Turkey. *East Mediterr Health J* 26: 276-282.
- Herrera-Rueda GA, Mogollón-Vargas JM, Serrano-García AY, Gaviria-Jaramillo LM (2021) Linfomas en pacientes con VIH: Una asociación compleja y frecuente. *Revisión narrativa de la literatura. Med Lab* 25: 695-707.

16. Cañas-Ruano E, Martín-Castillo M, Raventós B, Burgos J, Curran A, et al. (2020) Incidencia de neoplasias en una cohorte española de pacientes con infección por el virus de la inmunodeficiencia humana. *Med Clin* 155: 288-294.
17. Asensi-Diez R, Fernández-Cuerva C, Alcaraz Sánchez JJ, Muñoz-Castillo I (2019) Hospital admission and mortality causes of HIV patients in a third level hospital. *Rev Esp Quimioter* 32: 317-326.
18. Maya A, Segovia S, Madrigal S, Abrego I, Salas-Alanis JC (2018) Sarcoma de Kaposi en región oral y maxilofacial, una neoplasia olvidada. *Rev Esp Cir Oral Maxilofac* 40: 22-26.
19. Mizger VM, Sánchez LMM (2022) Quimioterapia en linfoma y su estrecha relación con el virus de la inmunodeficiencia humana /síndrome de inmunodeficiencia adquirida. *Rev Repert Med* 32.
20. Moura Filho JAT de, Araújo CAT de III, Asano NMJ, Souza MBR de (2021) Epidemiología de neoplasias em pessoas vivendo com HIV/AIDS. *Res Soc Dev* 10: e48101119240-e48101119240.
21. Sanín AM, Londoño ÁM, Gil V, Mejía AM, Aguirre HD, Vásquez EM, et al. (2022) Manifestaciones mucocutáneas y su relación con el recuento de linfocitos T CD4 en pacientes infectados con el virus de inmunodeficiencia humana hospitalizados en Medellín, Colombia. *Biomedica* 42: 278-289.
22. Arias Beatón E, Arias Beatón MB, Tellería León YE (2017) Linfoma primario de ano en un paciente con virus de la inmunodeficiencia humana/sida. *Medisan* 21: 2035-2041.
23. Zanuzzi Matías G, Cattaneo Máximo J, López Silvina M, Pérez Maure María De Los Ángeles, Romero César A (2020) Hipertensión y síndrome metabólico en pacientes con Virus de la Inmunodeficiencia-Humana. *Medicina* 80: 453-461.
24. Posada DH, Acevedo LST, Arredondo MV, Vásquez GIS (2020) High-risk human papillomavirus infection and associated factors in the anal canal of HIV-positive patients in Medellín, 2017-2018. *Rev Saude Publica* 54: 93.
25. Sotomayor-Duque G, Colunga-Pedraza PR, Colunga-Pedraza JE, Lozano-Morales RE, Bugarin-Estrada E, et al. (2017) Linfoma no Hodgkin e infección por el virus de la inmunodeficiencia humana Experiencia de 10 años en un centro de referencia universitario. *Rev Hematol Mex* 18: 155-160.
26. Miranda Solis EM, Urbina IM (2021) VIH y linfoma no HODGKIN tipo B en una paciente con carga viral indetectable. *Medicinas* 5: 37.
27. Ojeda MFC (2018) Características Clínico - Epidemiológicas de pacientes con VIH y Neoplasias atendidos en la Unidad de Infectología de la Ciudad Hospitalaria "Dr. Enrique Tejera" · Valencia-Venezuela. 2001-2016. *Boletín Venezolano de Infectología* 29: 5-10.
28. Milanesio M, Sánchez AV, Guanchiale L, Kaplan RL (2021) Linfoma primario de las efusiones con afectación extracavitaria multisistémica en HIV negativo diagnosticado mediante autopsia. *Rev Fac Cien Med Univ Nac Cordoba* 78: 391-394.
29. Olgún CGC, López MAL, Salazar JDJ, Clemente SP (2022) Sarcoma de Kaposi en diagnóstico tardío de VIH/ sida. *Rev Cubana Estomatol* 59: 3200.