



## Endoscopic Retrograde Cholangiopancreatography in Pediatric Biliary Diseases

**Paola De Angelis\*, Renato Tambucci, Giulia Angelino, Filippo Torroni, Francesca Rea, Giovanni Federici di Abriola, Francesca Foschia, Tamara Caldaro, Simona Faraci, Anna Chiara Contini, Erminia Romeo and Luigi Dall'Oglio**

*Digestive Surgery and Endoscopy Unit, Children's Hospital Bambino Gesù, Rome, Italy*

**\*Corresponding author:** Paola De Angelis, Digestive Surgery and Endoscopy Unit, Bambino Gesù Children's Hospital, IRCCS, Piazza S. Onofrio 4, 00165 Rome, Italy, Tel: +39066892841, Fax: + 390668592949, E-mail: [paola.deangelis@opbg.net](mailto:paola.deangelis@opbg.net), [paoladeangelis.opbg@gmail.com](mailto:paoladeangelis.opbg@gmail.com)

### Abstract

Endoscopic retrograde colangio-pancreatography (ERCP) in children is currently widespread and utilized, particularly for therapeutic indication, as in adulthood. ERCP considered efficacy and safe in children, if performed by expert endoscopists.

In the last year, the incoming progress of magnetic resonance image (MRI), especially in collaborator pediatric patients, eliminated many diagnostic indications for ERCP, leaving therapeutic aims as in adults.

In special situation, ERCP maintains a diagnostic value: study of pancreatobiliary junction, to rule out congenital malformation; definition of malign tumors such as rhabdomyosarcoma in children, where intraductal biopsies allow definitive diagnosis; preoperative evaluation of biliary tree in patients non-collaborative for MRI with suspected choledochal cyst.

Miniprobe endoscopic ultrasonography (EUS) with ERCP and linear EUS for bilio-pancreatic diseases have expanded the diagnostic field also in children affected by suspected biliary lithiasis or biliary neoplasm.

In pediatric biliary diseases, ERCP has the same therapeutic role as in adult: sphincterotomy, stricture dilations with balloon or rigid dilators, stones removal, stent placement in stricture and in leak.

In this review, we would like to focus our attention on state of art and news about the role of this combined endoscopic and radiologic procedure, in pediatric biliary diseases.

### Keywords

Endoscopic retrograde cholangiopancreatography (ERCP), Children, Biliary disease, Choledochal cyst, Biliary atresia

### Introduction

In the adult population, endoscopic retrograde cholangiopancreatography (ERCP) is a standard diagnostic therapeutic and endoscopic-radiological procedure used for many pancreaticobiliary disorders [1].

Although the experience with ERCP in children has been limited compared to adults, it has also been used in the pediatric population over the last 15 years [2]. The overall incidence of biliary diseases in children is lower compared to adults. In pediatric age, most biliary diseases are congenital and there is a minimal incidence of malignant disease [3,4].

For the pediatric population, Wayne JD, who performed the procedure on a 3.5-month-old infant using the standard adult duodenoscope [5], reported the first successful ERCP in 1976. Even though there have been technological advances in pediatric endoscopes and a growing interest on ERCP in children, published experiences remain relatively limited.

To date, the North American Society published the only one position statement on ERCP in children in 2000 for Pediatric Gastroenterology, Hepatology and Nutrition (NASPGHAN) [6]. Despite the paucity and methodological limitations of pediatric studies, ERCP on children, particularly when performed by experienced endoscopists, can be considered a safe, effective, and relatively noninvasive tool in the management of several biliary disorders [2,3,7-10].

In children, the symptoms are often nonspecific, and a differential diagnosis between benign and severe disease can be difficult. Prompt and accurate diagnoses, as well as appropriate treatment, are required in serious conditions such as biliary atresia, Alagille syndrome, and choledochal cysts. Benign biliary diseases, such as cholelithiasis and biliary dyskinesia, also need accurate diagnosis and management in order to alleviate associated symptoms [11].

Frequency of biliary disorders varies worldwide and, as a consequence, indications of ERCP may change in different geographic areas: choledocholithiasis in Western countries, choledocholithiasis due to sickle-cell anemia in Middle Eastern countries, and choledochal cyst in Asian countries [3-12].

Since the introduction of a noninvasive, technologically advanced, imaging modality, the magnetic resonance cholangiopancreatography (MRCP), the ERCP has been largely replaced as a diagnostic tool

**Table 1:** Endoscopes and accessories for ERCP in biliary diseases in use in our Center.

Endoscopes	Characteristics
Pediatric diagnostic duodenoscope	Insertion tube 7.5 mm; distal end 7.5 mm; operative channel 2 mm Useful for neonates and infants weighing less than 10 Kg Narrow operative channel allows only special accessories less than 5 Fr in diameter and may results in ineffective suction when the cannula is in place A well-experienced and trained endoscopist needs to control the tip of the sphincterotome Metallic tip limits the use for diagnostic purpose
Diagnostic duodenoscope	Insertion tube 11 mm; distal end 12.6 mm; operative channel 3.2 mm Useful for children by the age of 8 months and adults
Therapeutic duodenoscope	Insertion tube 11.3-12.5 mm; distal end 13.2-13.5 mm; operative channel 4.2 mm Useful for children by the age of 7 years and adults
Accessories	Characteristics
Cannulae	Working length: 170-195 cm Distal tip: 2.5-3.5-4-4.5-5-5.5-6 fr Those with tapered tip allow easier cannulation of narrow papillae
Sphincterotomes, cannulotome	Lumen: double, triple Working length: 170-195 cm Distal tip: 4-4.5-5 fr Different cable bending
Guide wires	Tip shape: straight or angled Working length: 270-400 cm Outer diameter: 0.025-0.032-0.035 in
Nasobiliary drainages	Applicable to: right hepatic duct, left hepatic duct, common bile duct Different shapes Insertion portion diameter: 5-6-7 fr
Biliary stents	Shape: straight, proximal bend, center bend, pigtail, Length: 3-4-5-6-7-8-9-10-11-12-13-14-15 cm Size: 7-8-5-10 fr
Hydrostatic dilators	Balloon diameter: 12-13.5-15-16.5-18-19-20 mm
Stone extraction balloon	Injection part: above, below Balloon diameter: 8.5-11.5-15-18-20 mm
Stone retrieval baskets	Different shapes Opening width: 20-22 mm
Cytology brushes	Outer diameter: 1-1.2-2-2.4-3-5 mm
Biopsy forceps	Shapes: oval, alligator, with or without needle Different working lengths and opening sizes

[13,14]. Unlike MRCP, however, ERCP can provide access for therapeutic interventions such as sphincterotomy, stricture dilations with balloon or rigid dilators, stone extraction, stent insertion in stricture or biliary leak, or biopsy [1,6,15]. Moreover, ERCP remains the first diagnostic choice in the evaluation of specific conditions, such as the evaluation of pancreaticobiliary duct junction anomalies, the tissue sampling from biliary or pancreatic lesions (brush cytology or endo-biliary biopsies), and the pre-operative assessment (for biliary atresia or choledochal cysts) of non-compliant patients in which it is difficult to perform a MRCP [16,17].

In adults, it has been demonstrated that miniprobe endoscopic ultrasonography (EUS) during ERCP and linear EUS can offer important additional information on pancreaticobiliary disorders [18]. Despite further studies being required, EUS can have a significant impact on management of a child with biliopancreatic disease [19,20].

The aim of the following review is to provide an update on the role of ERCP in the management of biliary diseases in the pediatric population.

### Technical Aspects and Complications

The size of a normal common bile duct measured in children between the ages of 7 and 16 years varies from 2.1 to 4.9 mm just below the entry of the cystic duct. Cystic duct inlet on a common bile duct is angled (65%), parallel (25%) or spiral (10%). Most of the sphincter of Oddi is located in the duodenum wall.

Different endoscopes and accessories for ERCP in biliary diseases are available for pediatric patients. A list of endoscopes and accessories in use in our Center is shown in table 1. Slim lateral view video duodenoscope is very useful for neonates and infants weighing less than 10 Kg. Some problems may arise in the narrowing of the operative channel that hampers the passing of the cannula through the elevator and results in an ineffective suction when the cannula is in place [21]. This channel only allows the insertion of special accessories less than 5 Fr in diameter, which causes several difficulties. A well-experienced and trained endoscopist needs to control the tip of the sphincterotome, particularly during therapeutic ERCP. In a large series, Cheng described the use of PJF in infants less than 1.5 years old and standard adult diagnostic duodenoscope in patients ranging from 8 months to 17 years old [3]. According to our experience, as also indicated in studies of other international authors, we suggest the use of the standard adult therapeutic duodenoscope in children older than 7-8 years old [21]. The PJF has a metallic tip, which limits its use to the diagnosis, so electrical damage to the duodenal wall is avoided. In specific cases, PJF was used without any complications regarding contact between the wire and the instrument.

There are many types of accessories that differ in size and conformations (Table 1). In order to pick the correct accessory, one must check the accessories available and experiment with each to narrow down which accessory would be the best choice. It is very important to have all the different types of accessories, such as cannulae, sphincterotomes, cannulotomes or pre-cut

sphincterotomes, guide wires in different sizes, distal conformations and stiffness, nasobiliary and pancreatic drainages as well as biliary and pancreatic stents, hydrostatic dilators and stones extraction catheters, available for use.

The endoscopists' experience and anesthesiologist collaboration are very important. General anesthesia with intubation is mandatory in order to avoid tracheal compression. A single dose of the antibiotic of intraoperative prophylactic infusion is generally used in all therapeutic procedures. The role of nurses is essential when inspecting all the accessories as well as active collaboration during diagnostic and general therapeutic maneuvers [22].

Percutaneous transhepatic cholangiography (PTC) and ERCP, techniques combined with *rendez-vous*, are effective in resolving complex and difficult biliary strictures.

Other devices are available and could be helpful. Endoscopic ultrasonography (EUS), done with either dedicated echoendoscopes or miniprbes, has a diagnostic and therapeutic role in children [20].

Supine patient's position is preferred among most patients. The endoscope carefully passes through the esophagus, stomach, and after observation of the pylorus with a "downward" movement of the tip, it must go through the pylorus with an "upward" movement, looking at the antral wall gliding. An "upward" movement and a clockwise motion enable us to pass into the II duodenal portion where we can see the papilla. The "short" position is important for major papilla cannulation and therapeutic maneuvers (turn clockwise and retract the instrument possibly with X-Ray control). To avoid gastric dislocation, it is helpful to turn the instrument clockwise combined with a "downward" movement and short instrument advancement.

In small infants, it is very difficult sometimes to maintain the instrument in this position and the only way that works is using the "long" position, which hampers either the radiological view of the instrument overlapping the biliary tree or the therapeutic maneuver of less mobility and tip control. The long position could be more effective than the short one in minor papilla management.

Incidences regarding either diagnostic or therapeutic ERCP-related complications are the same in adults as they are in infants ranging from 1% to 9% [3,23]. The most frequent complication is pancreatitis caused by pancreatography with an elevated serum lipase and amylase, pain, and leukocytosis. Asymptomatic enzyme elevation should not be classified as pancreatitis.

This complication can be avoided with careful cannula introduction, avoiding parenchymography and, in case of pancreatic ES, with the use of nasopancreatic or short and thin (5 cm × 5 Fr) pancreatic drainages.

There is a consensus recommendation, ranked as grade A, for adult patients discussing the prophylactic use of endorectal indometacine to prevent post ERCP pancreatitis [24].

Bleeding after endoscopic sphincterotomy must be treated with 1:10.000 adrenaline injections.

Careful movements of the instrument will decrease the possibility of perforations and duodenal haematoma. Conservative treatment, with the use of antibiotics, fasting, and very close patient monitoring, could be effective, but should always be done in a surgical setting environment.

## Diagnostic and Therapeutic Indications

Pediatric indications for ERCP are similar to those for adults, but the relative frequency of each indication differs. Children have lower incidence of malignant diseases but more indications related to congenital abnormalities or trauma. Compared to adults, indications related to biliary lithiasis or to prior surgeries are less common in children.

In 2000, a position statement was published by the NASPGHAN regarding ERCP in children [6]. Diagnostic indications are neonatal

**Table 2:** Biliary indications for ERCP in children.

Diagnostic	Therapeutic
Biliary atresia	Sphincterotomy
Choledocal cyst	Sphincteroplasty
Choledocholithiasis	Stone extraction
Biliary obstruction to parasitic infestation	Stricture dilation
Benign and malign biliary strictures	Stent placement
Primary sclerosing cholangitis	Nasobiliary drainage
Pre/post-operative evaluation	
Neoplasia	
Post traumatic disease	
Surgical complication	

cholestasis (especially known or suspected biliary atresia or biliary cysts) and inconclusive abnormal findings on other examinations (i.e. MRCP or CT scan). Therapeutic indications are biliary obstruction (i.e. due to known or suspected choledocholithiasis, bile plug syndrome, parasitic infestation, biliary strictures, or primary sclerosing cholangitis), biliary obstruction or leaks after liver transplant, postoperative complications after laparoscopic cholecystectomy. The following techniques are generally used during therapeutic ERCP: sphincterotomy, sphincteroplasty (balloon dilation), stone extraction, stricture dilation, stent placement.

Biliary indications for ERCP in children are shown in [table 2](#).

## Neonatal cholestasis

Neonatal cholestasis is defined as prolonged conjugated hyperbilirubinemia caused by diminished bile flow and/or excretion, occurring in the newborn period. A large number of disorders can explain this condition while only a few diagnoses account for the majority of cases. Management of neonatal cholestatic disorders benefits from multidisciplinary evaluation. Early diagnosis and treatment are crucial in order to minimize the high risk of morbidity and mortality related to secondary liver injury. Structural causes of neonatal cholestasis include biliary atresia, choledochal cyst, choledocholithiasis and inspissated bile, intrahepatic bile duct hypoplasia or paucity (Alagille syndrome), neonatal sclerosing cholangitis, and congenital bile duct stricture.

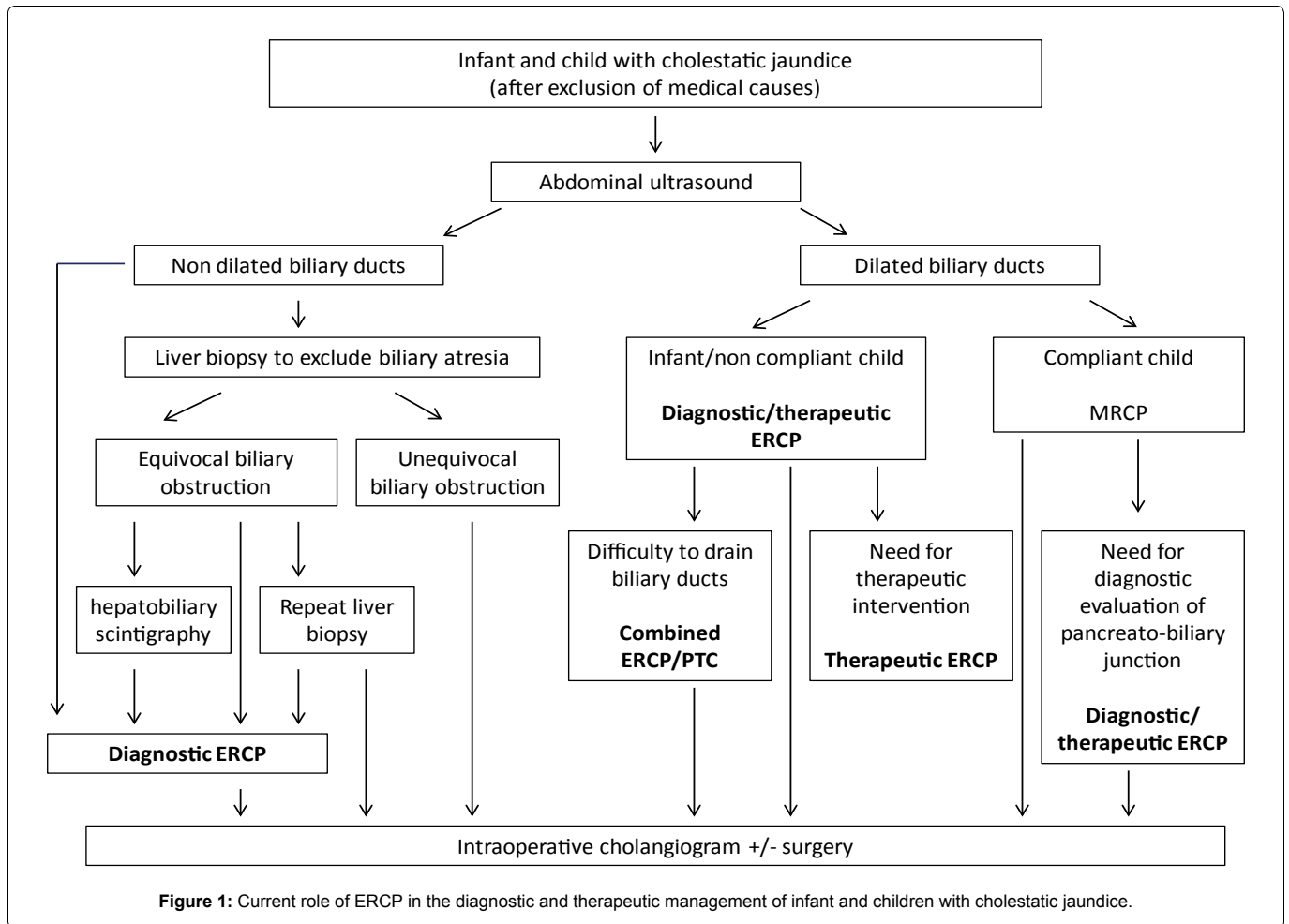
Extrahepatic biliary atresia must be promptly diagnosed or excluded in order to effect the best therapeutic choice. Infants should be evaluated as rapidly as possible because the success of the surgery decreases progressively as the patient gets older.

Although endoscopy is not required for most patients with neonatal cholestasis, ERCP can aid in the diagnosis of biliary atresia and choledocal cyst, when all the other diagnostic steps lead to indefinite diagnosis [16].

The Cholestasis Guideline Committee of the North American Society for Pediatric Gastroenterology, Hepatology and Nutrition has formulated a clinical practice guideline for the diagnostic evaluation of cholestatic jaundice in the infant. The Committee examined the value of diagnostic tests commonly used for the evaluation of cholestatic jaundice and how those interventions can be applied to clinical situations in the infant. According these suggestions, ERCP with a small pediatric side viewing duodenoscope, may be considered in the diagnostic algorithm, in selected cases with appropriate support staff and specialists with expertise in this procedure in young infants [25].

In 2009, Hartley JL et al. reported an interesting algorithm for infants with long term conjugated jaundice and a suspected surgical cause; ERCP finds a role after liver biopsy and before laparotomy, in equivocal large duct obstruction, when the diagnosis is unclear. As the technically difficulties in infants, the use of ERCP is confined to large centers [26].

According to our clinical experience, the availability of small



caliber duodenoscopes allows ERCP also in neonates of low weight, with useful and good results. The role of ERCP in the diagnostic and therapeutic management of infant and children with cholestatic jaundice is shown in figure 1.

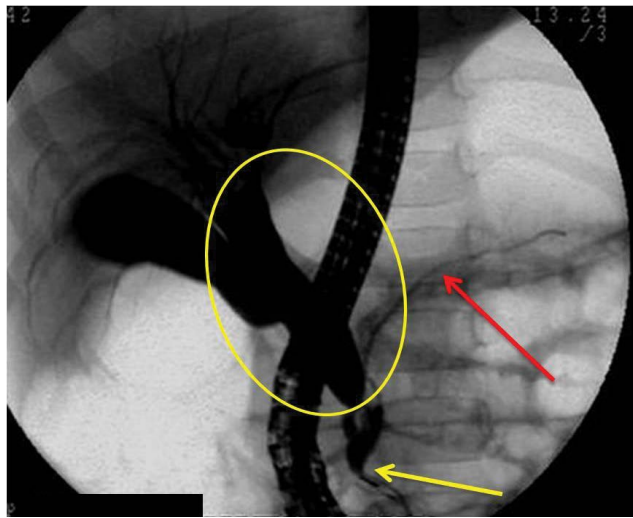
### Biliary atresia

Biliary atresia (BA) is a rare neonatal disorder characterized by a destructive inflammatory cholangiopathy that leads to complete obliteration of all or part of both the intrahepatic and extrahepatic biliary system. If untreated, progressive liver cirrhosis leads invariably to death. Kasai portoenterostomy re-establishes biliary flow and limits cholestatic hepatic injury. Diagnosis remains time sensitive because delayed surgical treatment is associated with poor outcome. Despite timely surgical intervention, progressive fibrosis and biliary cirrhosis develop in children who do not drain bile, and liver transplantation becomes the only option for long-term survival. All infants with prolonged conjugated hyperbilirubinemia, acholic stools and laboratory tests suggestive of cholestatic liver disease should be investigated for BA. Abdominal ultrasound allows the identification of specific finding in most cases, but it is operator-dependent and sensitivities varies from 49% to 73%. Radioisotope excretion studies typically show good hepatic uptake with absent or reduced excretion into the intestine on the 24-hour delayed images. Unfortunately, this finding is not specific for BA and has been reported in children with severe intrahepatic cholestasis. Liver histology with a percutaneous biopsy is the most reliable test. Although the high sensitivity and specificity (90%) for BA, especially in children younger than 6 weeks, histology might not have typical features, and serial samples may be required to reach a definitive diagnosis. No single test or combination of tests is consistently reliable in differentiating intrahepatic from extrahepatic forms of cholestasis. Intra-operative cholangiography performed before Kasai portoenterostomy is regarded as the gold standard and definitive investigation in diagnosis of BA [16,26]. Nonetheless, over the past decade, the diagnostic role of ERCP has

been explored as a minimally invasive alternative to the traditional diagnostic method of open surgical cholangiography at the time of a Kasai procedure [16]. Three the types of ERCP findings consistent with BA have been reported: type 1, no visualization of biliary tree; type 2, opacification of the distal common duct and gallbladder without visualization of the main hepatic duct; and type 3, opacification of the distal common duct, the gallbladder, and a segment of the main hepatic duct with biliary lakes at the porta hepatis [27]. Petersen C et al. found that BA was excluded through ERCP in 34 out of 140 children. They concluded that ERCP is not an alternative to non-invasive imaging but it should be performed prior to explorative laparotomy in all patients because it could avoid unnecessary surgical procedures in almost 25% of the cases [28]. Other studies have also showed a high reliability of ERCP in diagnosing BA in selected infants with ambiguous clinicopathologic information in which laparotomies could be prevented by demonstrating normal patency of the biliary tract [29-32]. Although it has demonstrated a high sensitivity and specificity (86% to 100% and 73% to 94%, respectively) and some authors would include the ERCP in the algorithm of neonatal cholestasis, in clinical practice the use of ERCP continues to be restricted to selected cases and only in the tertiary care centers. In our view, in the hands of a skilled endoscopist, ERCP can be considered in infants with suspected BA, with unclear diagnostic evaluation, before liver biopsy (Figure 1).

### Alagille syndrome

Alagille syndrome (AGS) is an autosomal dominant or sporadic disorder with variable expressivity and approximately 95% of patients with AGS have mutations in the gene JAG1. It may involve multiple organs including liver, heart, eyes, vertebrae, face, and kidneys. Before molecular testing, the diagnosis was made clinically in the presence of the following criteria: interlobular bile duct paucity associated to at least 3 of 5 other major clinical findings including cholestasis (96% of patients), cardiac anomalies (97%), butterfly vertebrae (51%),



**Figure 2:** Choledochal cyst, biliary stricture, common biliopancreatic duct.

posterior embryotoxon of the eye (78%), and dysmorphic facies (96%) [33]. Neonatal cholestasis secondary to the paucity of intrahepatic bile ducts is the most prominent clinical manifestation. When it is severe it may be clinically difficult to distinguish from BA [34]. It is essential to make a timely and proper diagnosis. A Kasai portoenterostomy is absolutely not indicated in AGS because it may worsen deterioration of liver function [35]. No ultrasound findings are specific for AGS. Hepatobiliary scintigraphy could be inconclusive since no detection of tracer excretion from the liver can be found. As with patients with BA, diagnostic tests may show indeterminate results [34]. ERCP could be helpful in diagnosing ASG while at the same time excluding BA. ERCP can show a patency (normal or with diffuse narrowing) of the extrahepatic biliary tree and narrowing of the intrahepatic ducts with reduced arborization [16,36]. However, the actual diagnostic role of ERCP in this condition is really limited, and the diagnosis is made by identifying the constellation of clinical features, associated with the characteristic histology (interlobular bile duct paucity) and confirmed by molecular DNA analysis.

### Choledochal cysts

Choledochal cysts (CC) are a rare structural anomalies consisting of cystic dilation of the biliary tract (Figure 2). CC are much more prevalent in Asia than in Western countries (incidence varies from 1 in 100,000 to 1 in 150,000 individuals in Western countries to 1 in 13,000 individuals in Japan) and are 4 times more common in females [37]. The exact etiology is still unclear and pathogenesis is probably multifactorial. However, in 30% to 70% patients with CC, an anomalous pancreaticobiliary duct junction can be demonstrated: the common bile duct and the pancreatic duct meet outside the ampulla of Vater, thus forming a long common channel. This abnormal union allows pancreatic secretions to reflux into the biliary tree and the exposure to pancreatic enzymes may lead to duct wall deterioration resulting in subsequent dilation [38].

Five types of CC have been classified in 1977 by Todani T et al. [39]. Type I CC (80% to 90% of all CC) have subsequently been differentiated into the following subtypes: type IA, marked cystic dilation of the entire extrahepatic biliary tree, with intrahepatic ducts normal in size and appearance; type IB, focal, segmental dilation of the extrahepatic bile duct (most commonly distal), with no evidence of anomalous pancreaticobiliary junction; type IC, cylindrical smooth fusiform dilation of the entire extrahepatic bile duct with pancreaticobiliary malunion. Type II CC are true diverticula of the extrahepatic duct. Type III CC are intraduodenal choledochoceles, consisting of dilation of the distal common bile duct that is confined to the wall of the duodenum. Type IV CC (15% to 20% of all CC) are multiple dilations that can involve both the intrahepatic and extrahepatic ducts. According to intrahepatic duct development, it has been made a subclassification into type IVA and type IVB: type IVA,

cystic, fusiform or irregular multiple intrahepatic and extrahepatic dilations; type IVB, multiple dilations of the extrahepatic biliary tree only classically described as a “string of beads”. Type V CC, or Caroli disease, consist of intrahepatic saccular or fusiform dilatations of the intrahepatic bile ducts with no underlying obstruction or extrahepatic biliary tree involvement. Caroli syndrome is cystic disease associated with congenital hepatic fibrosis. Type V CC is frequently accompanied with polycystic kidney disease [37-39].

CC are usually diagnosed in infants and young children (80%). Clinical presentation, consisting in the classic triad of abdominal pain, jaundice, and right upper quadrant mass, occurs in less than 20% of patients, mainly in the pediatric population. Infants frequently show obstructive jaundice, acholic stools, and palpable abdominal mass, whereas adult patients show nonspecific and intermittent symptoms. CC can also present symptoms related to complications of ascending cholangitis and pancreatitis [40,41].

These conditions are predisposed by gallstones formation and recurrent superinfection, which are secondary to bile stasis [42]. Biliary malignancy has been reported in 10% to 30% of CC, however it is rarely seen in pediatric age [43,44]. The definitive treatment is complete excision of the cyst with construction of a biliary-enteric anastomosis to restore continuity with the gastrointestinal tract.

ERCP may have an important role in diagnosing CC. Indeed, ultrasonography can show feature suggestive of CC (cystic mass in the right upper quadrant), but it may be difficult to make a differentiation from other intra-abdominal cysts such as pancreatic pseudocysts, echinococcal cysts or biliary cystadenomas [45]. MRCP is highly sensitive (70% to 100%) and specific (90% to 100%) in CC diagnosis and classification, however, it is limited in assessing pancreaticobiliary junction and in showing ducts or stones smaller than 5 mm and tortuous ducts [46,47]. Moreover, MRCP cannot be used for therapeutic purposes. ERCP is the most sensitive technique in identifying and classifying anomalous pancreaticobiliary duct junctions in all age groups and can have a therapeutic role by allowing biliary drainage. ERCP with sphincterotomy and stone removal, with or without stent placement, has been shown to be safe and effective in relieving symptoms. In patients with complicated CC, ERCP is helpful in improving pancreatitis and associated inflammation. It can serve as a bridge to first stabilize the patient before definitive surgery. Preoperative ERCP helps in the planning of appropriate surgical intervention. Indeed, it may provide anatomical details about the length of the distal narrow portion of the dilated bile duct and clear visualization of its confluence with the pancreatic duct [48-52]. ERCP has also been used for conservative treatment of type III CC. With the risk of malignancy considered very low, it has been reported as a conservative management with endoscopic sphincterotomy in order to achieve drainage [53].

Hiramatsu T et al. in 2015 reported that the rates of the visualization of the main pancreatic duct and pancreaticobiliary ductal union were significantly higher when using ERCP than when using MRCP [7]. According to our experience, the ERCP plays a leading role in both diagnosing and managing CC; especially in symptomatic children, who presented with biliary pancreatitis, the possibility to perform an accurate anatomical diagnosis of CC and contemporary to resolve the biliary obstruction give a great contribute before surgical planning. In postsurgical patients, therapeutic ERCP helps in every situation of remnant long common duct.

### Biliary dyskinesia

Biliary dyskinesia (BD) is characterized by a nonspecific vague abdominal pain and nausea associated with poor gallbladder contractility, in the absence of cholelithiasis on ultrasonography. Abnormal gallbladder contractility is defined as an ejection fraction below 35% with a cholecystokinine analogue infusion at a radioisotope liver scan [54]. Cholecystectomy has been recommended as the method of choice to treat adult patients with BD. In the recent years, there has been an overall increase of laparoscopic cholecystectomy performed for BD also for the pediatric population [55]. Some authors

have speculated that BD could be caused by a motor dysfunction of the sphincter of Oddi. Based on this assumption, ERCP has been used to perform sphincter of Oddi manometry in adults and children [56]. However, given the lack of experience and methodological quality of the studies, ERCP cannot be indicated in the assessment of BD [6].

### Gallstone disease

In adults, the management of common bile duct stones (CBDS) is the main indication for ERCP. Clearance of bile-duct stones can be obtained in 80-95% of cases. Excellent long-term results have been reported for endoscopic CBDS removal [15]. Endoscopic sphincterotomy and stone extraction for choledocholithiasis is the most commonly used biliary intervention also for children. This procedure has also been reported in infants younger than 2 months [57]. In a recent retrospective pediatric study, gallstone disease was the second most common indication after chronic or recurrent pancreatitis [4]. Although the incidence of gallstone disease in children is lower than in adults, an increasing rate has been reported. This is probably due to the widespread use of ultrasonography, which has led to an increased detection of gallstones in asymptomatic patients, but also to an increase of risk factors for gallstones [58]. High-risk patients are those with hemolytic disease, notably children with sickle cell anemia, one of the commonest hemoglobinopathies (cholelithiasis prevalence 17% to 55%) [59]. Non hemolytic causes include parenteral nutrition administration, cystic fibrosis and severe obesity, all of which are conditions raised in childhood [55].

Gallstone disease may appear in a variety of ways: asymptomatic (incidental detection); biliary colic/cholecystitis; cholangitis/choledocholithiasis/pancreatitis; nonspecific abdominal pain [60]. The aim of treatment is to provide long-term relief from the symptoms to minimize the occurrence of complications. Cholecystectomy remains the standard of care for patients with symptomatic gallstones. Although a significant proportion of asymptomatic patients may develop complications related to the presence of gallstones, no definitive consensus exists regarding the indications for cholecystectomy in asymptomatic children [61,62]. Gallstones with a high proportion of cholesterol may be dissolved with ursodeoxycholic acid. In children, this treatment seems to be effective in relieving the symptoms, but complete stone dissolution occurs rarely with possible recurrence [63]. When cholecystectomy is indicated, common bile duct exploration is routinely recommended because of the high incidence of CBDS in patients with cholelithiasis [64]. In the era of laparoscopic cholecystectomy as conventional procedure, preoperative ERCP has replaced the intraoperative cholangiography gaining a leading role in detecting CBDS. ERCP is valuable both for the diagnosis and management of CBDS. Sphincterotomy generally should be reserved for symptomatic patients or those with underlying lithogenic disorders [65,66]. Recently Troendle, et al. have shown that therapeutic ERCP for choledocholithiasis can be performed by an appropriately trained pediatric gastroenterologist with acceptable cannulation rates, stone extraction rates, and adverse event rates as defined by the American Society for Gastrointestinal Endoscopy Quality Task Force [10].

In our opinion, as for adults, also in children, therapeutic ERCP performed by experienced endoscopists is a mainstay in the management of choledocholithiasis and its complications, such as cholangitis and gallstone pancreatitis. Particularly before cholecystectomy, in patients previously affected by complication of lithiasis, a biliary sphincterotomy is preferred, to avoid postsurgical biliary obstruction.

### Benign biliary strictures

In adulthood, ERCP is indicated for the evaluation and treatment of benign biliary strictures (postoperative biliary strictures, main duct strictures in primary sclerosing cholangitis, common bile duct strictures due to chronic pancreatitis). The endoscopic treatment of benign strictures includes mechanical or pneumatic dilations and the placement of plastic stents [67]. ERCP has been reported to be effective in both diagnosis and treatment of benign biliary strictures also in children [68].

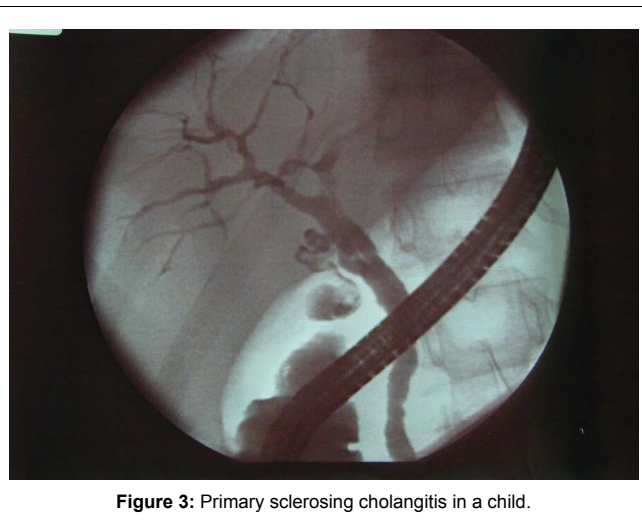


Figure 3: Primary sclerosing cholangitis in a child.

### Primary sclerosing cholangitis

Progressive fibrosing inflammation leading to multiple stenosis of intra- and/or extrahepatic bile ducts is characteristic of primary sclerosing cholangitis (PSC, figure 3) [69]. Incidence of PSC is lower in children than adults, however it is an important cause of morbidity and mortality in the pediatric age group and accounts for approximately 2-3% of pediatric liver transplants [70]. Inflammatory bowel disease (IBD) is strongly associated with the diagnosis of sclerosing cholangitis, being found in 60% to 90% of cases according to study design [71]. Although the MRCP is gradually replacing the ERCP as a diagnostic test for PSC, recently some authors have reported that ERCP continues to have a leading role in the diagnosis of PSC in pediatric population [72]. Biliary tract strictures in PSC are characteristically multiple, but may also present as a dominant stricture (DS) of the extrahepatic biliary tree [73]. ERCP is indicated in DS treatment as it allows rapid opening of the stenosis, improving cholestasis and prolonging survival free of liver transplantation [74]. Both balloon dilation and stenting may be used to treat bile duct stenosis [75]. An advantage of ERCP over MRCP is that it permits therapeutic intervention for those children with obstructive symptoms. In conclusion, although MRI is gaining a prominent role in PSC diagnosis, ERCP continues to have pivotal role in the diagnosis and management of this condition both pre and post liver transplantation.

### Infections

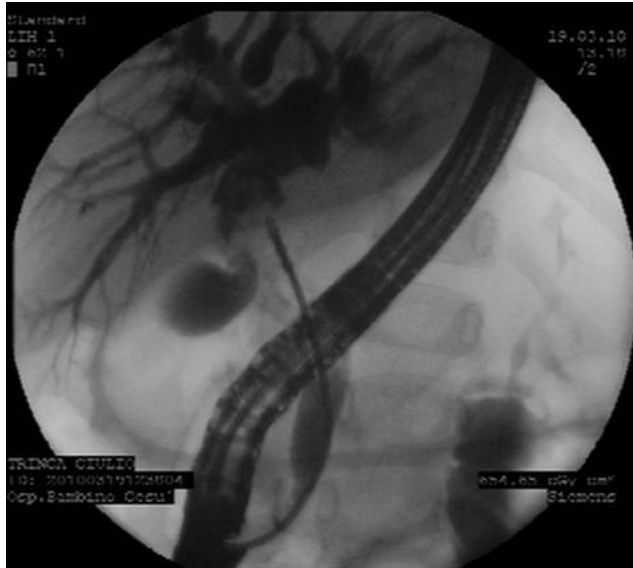
The presentation of Ascariasis is usually due to massive infestations and results in intestinal obstruction, volvulus, and intussusceptions. Although hepatobiliary and pancreatic involvement is less common, ascariasis infestation should be considered as a cause of acute biliary obstruction, especially in endemic areas. ERCP can play a diagnostic and therapeutic role in biliary ascariasis by allowing identification and removal of the worms in a tripod basket [76].

In *Fasciola hepatica* infection, when biliary ducts are involved, ERCP could represent an important procedure that contributes to the resolution of the disease together with a pharmacological approach [77].

ERCP is generally indicated for the relief of biliary obstruction by parasites and is useful in combination with anthelmintic therapy to eradicate the remaining worms.

### Postsurgical and Post-traumatic Biliary Disease

Bile duct leaks can be either iatrogenic or traumatic. In adults, the European Society of Gastrointestinal Endoscopy recommendations stated that endoscopic treatment is effective in more than 90% of patients with incomplete circumferential injury [78]. Endobiliary stent placement through ERCP provides a successful outcome in a majority of cases, irrespective of the severity of injury [79]. Biliary



**Figure 4:** Biliary tree dilation in a four-year-old boy with mild jaundice and MR positive for intracholedochal tissue. ERCP showed a vegetant mass in the choledochus. The biopsy forceps are in the choledochus and histology showed rhabdomyosarcoma.

endoprosthesis have been used also in children to treat acute or chronic bile leaks following abdominal trauma or surgical injury [80,81].

### ERCP and intraductal biopsy

Intraductal biopsy performed by ERCP improves the diagnosis of malignant tumors of the biliary tree. Histological diagnosis on tissue obtained by transluminal biopsy during ERCP in children has shown a great advantage with lower risk of loco-regional dissemination. In 2013, our group reported two cases of biliary tract rhabdomyosarcoma (Figure 4) that were histologically diagnosed by intracholedochal biopsy performed during ERCP, after being suspected with conventional imaging [17].

### ERCP and EUS

In 2015, Scheers I et al. published 52 EUS procedures, performed on 48 children, with pancreaticobiliary disorders: EUS was found to have a positive impact in 51/52 procedures, enabling to avoid endoscopic retrograde cholangiopancreatography (ERCP) (13 biliary; 6 pancreatic), focusing instead on endotherapy (7 biliary; 14 pancreatic) or reorienting therapy towards surgery in 7 patients. The authors suggested EUS as a diagnostic and therapeutic tool in the management of pediatric pancreaticobiliary diseases [20,82].

### Conclusions

ERCP plays an important role in biliary diseases in children, previously managed only by complex surgery. Indication for diagnostic ERCP are rare but still present, especially in infants. Therapeutic ERCP in children has had interesting results.

Unluckily, the total number of cases of pediatric ERCP reported in the literature remains small and many questions remain open regarding safety and outcomes of this procedure in children. The endoscopist's experience affects the results of pediatric ERCP and the best author of this procedure remains controversial: adult endoscopist with pediatric experience, pediatric gastroenterologist in surgical context, pediatric surgeons with gastroenterological approach, etc. However, the collaboration with adult endoscopists is mandatory for safe and effective procedures. It is important to underline that the technical skill (know-how) must match the knowledge of pediatric diseases. A multidisciplinary team of pediatric anesthesiologists, endoscopists, nurses, gastroenterologists and surgeons certainly has to be involved during the pediatric ERCP.

In 2015, a large retrospective review on 425 pediatric ERCP has been published by Giefer MJ and Kozarek RA [2]. They confirm that ERCP can be safely applied in younger patients by skilled endoscopists, with a complication rate similar to that in adults. Prospective studies are still required to define the safe and appropriate use of ERCP in children. For the future, we hope to see technical innovations regarding dedicated instruments (pediatric operative endoscopes and accessories-devices) rendering them more functional and adequate to therapeutic options.

### Acknowledgements

We thank our Radiologist, Lidia Monti, for her daily support.

### References

- ASGE Standards of Practice Committee, Early DS, Ben-Menachem T, Decker GA, Evans JA, et al. (2012) Appropriate use of GI endoscopy. *Gastrointest Endosc* 75: 1127-1131.
- Giefer MJ, Kozarek RA (2015) Technical outcomes and complications of pediatric ERCP. *Surg Endosc* 29: 3543-3550.
- Cheng CL, Fogel EL, Sherman S, McHenry L, Watkins JL, et al. (2005) Diagnostic and therapeutic endoscopic retrograde cholangiopancreatography in children: a large series report. *J Pediatr Gastroenterol Nutr* 41: 445-453.
- Otto AK, Neal MD, Slivka AN, Kane TD (2011) An appraisal of endoscopic retrograde cholangiopancreatography (ERCP) for pancreaticobiliary disease in children: our institutional experience in 231 cases. *Surg Endosc* 25: 2536-2540.
- Waye JD (1976) Endoscopic retrograde cholangiopancreatography in the infant. *Am J Gastroenterol* 65: 461-463.
- Fox VL, Werlin SL, Heyman MB (2000) Endoscopic retrograde cholangiopancreatography in children. Subcommittee on Endoscopy and Procedures of the Patient Care Committee of the North American Society for Pediatric Gastroenterology and Nutrition. *J Pediatr Gastroenterol Nutr* 30: 335-342.
- Hiramatsu T, Itoh A, Kawashima H, Ohno E, Itoh Y, et al. (2015) Usefulness and safety of endoscopic retrograde cholangiopancreatography in children with pancreaticobiliary maljunction. *J Pediatr Surg* 50: 377-381.
- Enestvedt BK, Tofani C, Lee DY, Abraham M, Shah P, et al. (2013) Endoscopic retrograde cholangiopancreatography in the pediatric population is safe and efficacious. *J Pediatr Gastroenterol Nutr* 57: 649-654.
- Vegting IL, Tabbers MM, Taminiau JA, Aronson DC, Benninga MA, et al. (2009) Is endoscopic retrograde cholangiopancreatography valuable and safe in children of all ages? *J Pediatr Gastroenterol Nutr* 48: 66-71.
- Troendle DM, Barth BA (2013) ERCP can be safely and effectively performed by a pediatric gastroenterologist for choledocholithiasis in a pediatric facility. *J Pediatr Gastroenterol Nutr* 57: 655-658.
- Goldman M, Prankoff T (2011) Biliary disease in children. *Curr Gastroenterol Rep* 13: 193-201.
- Issa H, Al-Haddad A, Al-Salem AH (2007) Diagnostic and therapeutic ERCP in the pediatric age group. *Pediatr Surg Int* 23: 111-116.
- Barish MA, Yucel EK, Ferrucci JT (1999) Magnetic resonance cholangiopancreatography. *N Engl J Med* 341: 258-264.
- Dumonceau JM, Garcia-Fernandez FJ, Verdun FR, Carinou E, Donadille L, et al. (2012) Radiation protection in digestive endoscopy: European Society of Digestive Endoscopy (ESGE) guideline. *Endoscopy* 44: 408-421.
- Costamagna G, Familiari P, Marchese M, Tringali A (2008) Endoscopic biliopancreatic investigations and therapy. *Best Pract Res Clin Gastroenterol* 22: 865-881.
- Liu QY, Nguyen V (2013) Endoscopic approach to the patient with congenital anomalies of the biliary tract. *Gastrointest Endosc Clin N Am* 23: 505-518.
- Scottoni F, De Angelis P, Dall'Oglio L, Francalanci P, Monti L, et al. (2013) ERCP with intracholedochal biopsy for the diagnosis of biliary tract rhabdomyosarcoma in children. *Pediatr Surg Int* 29: 659-662.
- Fritscher-Ravens A, Broering DC, Knoefel WT, Rogiers X, Swain P, et al. (2004) EUS-guided fine-needle aspiration of suspected hilar cholangiocarcinoma in potentially operable patients with negative brush cytology. *Am J Gastroenterol* 99: 45-51.
- Varadarajulu S, Wilcox CM, Eloubeidi MA (2005) Impact of EUS in the evaluation of pancreaticobiliary disorders in children. *Gastrointest Endosc* 62: 239-244.
- Scheers I, Ergun M, Aouattah T, Piessevaux H, Borbath I, et al. (2015) Diagnostic and Therapeutic Roles of Endoscopic Ultrasound in Pediatric Pancreaticobiliary Disorders. *J Pediatr Gastroenterol Nutr* 61: 238-247.

21. Dall'Oglio L, De Angelis P, Foschia F (2012) Endoscopic Retrograde Cholangiopancreatography in Children. In: Gershman G, Thomson M (eds). *Practical Pediatric Gastrointestinal Endoscopy*, 2<sup>o</sup> Edition, Wiley-Blackwell, USA.
22. Freeman KB (2006) Pediatric gastrointestinal endoscopy: textbook and atlas. *Gastroenterol* 131: 1358.
23. Keil R, Snajdauf J, Stuj J, Kalousová J, Nevolová P, et al. (2000) Endoscopic retrograde cholangiopancreatography in infants and children. *Indian J Gastroenterol* 19: 175-177.
24. Montañó Loza A, García Correa J, González Ojeda A, Fuentes Orozco C, Dávalos Cobián C, et al. (2006) Prevention of hyperamylasemia and pancreatitis after endoscopic retrograde cholangiopancreatography with rectal administration of indomethacin. *Rev Gastroenterol Mex* 71: 262-268.
25. Moyer V, Freese Dk, Whittington Pf, Olson Ad, Brewer F, et al. (2004) North American Society for Pediatric Gastroenterology, Hepatology and Nutrition. Guideline for the evaluation of cholestatic jaundice in infants: recommendations of the North American Society for Pediatric Gastroenterology, Hepatology and Nutrition. *J Pediatr Gastroenterol Nutr* 39:115-128.
26. Hartley JL, Davenport M, Kelly DA (2009) Biliary atresia. *Lancet* 374: 1704-1713.
27. Guelrud M, Jaen D, Mendoza S, Plaz J, Torres P (1991) ERCP in the diagnosis of extrahepatic biliary atresia. *Gastrointest Endosc* 37: 522-526.
28. Petersen C, Meier PN, Schneider A, Turowski C, Pfister ED, et al. (2009) Endoscopic retrograde cholangiopancreatography prior to explorative laparotomy avoids unnecessary surgery in patients suspected for biliary atresia. *J Hepatol* 51: 1055-1060.
29. Shteyer E, Wengrower D, Benuri-Silbiger I, Gozal D, Wilschanski M, et al. (2012) Endoscopic retrograde cholangiopancreatography in neonatal cholestasis. *J Pediatr Gastroenterol Nutr* 55: 142-145.
30. Shanmugam NP, Harrison PM, Devlin J, Peddu P, Knisely AS, et al. (2009) Selective use of endoscopic retrograde cholangiopancreatography in the diagnosis of biliary atresia in infants younger than 100 days. *J Pediatr Gastroenterol Nutr* 49: 435-441.
31. Keil R, Snajdauf J, Rygl M, Pycha K, Kotalová R, et al. (2010) Diagnostic efficacy of ERCP in cholestatic infants and neonates—a retrospective study on a large series. *Endoscopy* 42: 121-126.
32. Aabakken L, Aagaens I, Sanengen T, Aasen S, Emblem R, et al. (2009) Utility of ERCP in neonatal and infant cholestasis. *J Laparoendosc Adv Surg Tech A* 19: 431-436.
33. Alagille D, Estrada A, Hadchouel M, Gautier M, Odièvre M, et al. (1987) Syndromic paucity of interlobular bile ducts (Alagille syndrome or arteriohepatic dysplasia): review of 80 cases. *J Pediatr* 110: 195-200.
34. Emerick KM, Rand EB, Goldmuntz E, Krantz ID, Spinner NB, et al. (1999) Features of Alagille syndrome in 92 patients: frequency and relation to prognosis. *Hepatology* 29: 822-829.
35. Kaye AJ, Rand EB, Munoz PS, Spinner NB, Flake AW, et al. (2010) Effect of Kasai procedure on hepatic outcome in Alagille syndrome. *J Pediatr Gastroenterol Nutr* 51: 319-321.
36. Morelli A, Pelli MA, Vedovelli A, Narducci F, Solinas A, et al. (1983) Endoscopic retrograde cholangiopancreatography study in Alagille's syndrome: first report. *Am J Gastroenterol* 78: 241-244.
37. Soares K, Arnaoutakis DJ, Kamel I, Rastegar N, Anders R, et al. (2014) Choledochal cysts: presentation, clinical differentiation, and management. *J Am Coll Surg* 219: 1167-1180.
38. Singham J, Yoshida EM, Scudamore CH (2009) Choledochal cysts: part 1 of 3: classification and pathogenesis. *Can J Surg* 52: 434-440.
39. Todani T, Watanabe Y, Narusue M, Tabuchi K, Okajima K (1977) Congenital bile duct cysts: Classification, operative procedures, and review of thirty-seven cases including cancer arising from choledochal cyst. *Am J Surg* 134: 263-269.
40. Stringer MD, Dhawan A, Davenport M, Mieli-Vergani G, Mowat AP, et al. (1995) Choledochal cysts: lessons from a 20 year experience. *Arch Dis Child* 73: 528-531.
41. Wiseman K, Buczkowski AK, Chung SW, Francoeur J, Schaeffer D, et al. (2005) Epidemiology, presentation, diagnosis, and outcomes of choledochal cysts in adults in an urban environment. *Am J Surg* 189: 527-531.
42. Shah OJ, Shera AH, Zargar SA, Shah P, Robbani I, et al. (2009) Choledochal cysts in children and adults with contrasting profiles: 11-year experience at a tertiary care center in Kashmir. *World J Surg* 33: 2403-2411.
43. Jan YY1 Chen HM, Chen MF (2000) Malignancy in choledochal cysts. *Hepatogastroenterology* 47: 337-340.
44. Huang CS, Huang CC, Chen DF (2010) Choledochal cysts: differences between pediatric and adult patients. *J Gastrointest Surg* 14: 1105-1110.
45. Akhan O, Demirkazik FB, Ozmen MN, Ariyürek M (1994) Choledochal cysts: ultrasonographic findings and correlation with other imaging modalities. *Abdom Imaging* 19: 243-247.
46. Park DH, Kim MH, Lee SK, Lee SS, Choi JS, et al. (2005) Can MRCP replace the diagnostic role of ERCP for patients with choledochal cysts? *Gastrointest Endosc* 62: 360-366.
47. Singham J, Yoshida EM, Scudamore CH (2009) Choledochal cysts: part 2 of 3: Diagnosis. *Can J Surg* 52: 506-511.
48. Tsuchiya H, Kaneko K, Itoh A, Kawashima H, Ono Y, et al. (2013) Endoscopic biliary drainage for children with persistent or exacerbated symptoms of choledochal cysts. *J Hepatobiliary Pancreat Sci* 20: 303-306.
49. Sharma AK, Waklu A, Sharma SS (1995) The role of endoscopic retrograde cholangiopancreatography in the management of choledochal cysts in children. *J Pediatr Surg* 30: 65-67.
50. Miyano T, Ando K, Yamataka A, Lane G, Segawa O, et al. (1996) Pancreaticobiliary maljunction associated with nondilatation or minimal dilatation of the common bile duct in children: diagnosis and treatment. *Eur J Pediatr Surg* 6: 334-337.
51. De Angelis P, Foschia F, Romeo E, Caldaro T, Rea F, et al. (2012) Role of endoscopic retrograde cholangiopancreatography in diagnosis and management of congenital choledochal cysts: 28 pediatric cases. *J Pediatr Surg* 47: 885-888.
52. Teng R, Yokohata K, Utsunomiya N, Takahata S, Nabae T, et al. (2000) Endoscopic retrograde cholangiopancreatography in infants and children. *J Gastroenterol* 35: 39-42.
53. Lopez RR, Pinson CW, Campbell JR, Harrison M, Katon RM (1991) Variation in management based on type of choledochal cyst. *Am J Surg* 161: 612-615.
54. Hansel SL, DiBaise JK (2010) Functional gallbladder disorder: gallbladder dyskinesia. *Gastroenterol Clin North Am* 39: 369-379, x.
55. Mehta S, Lopez ME, Chumpitazi BP, Mazziotti MV, Brandt ML, et al. (2012) Clinical characteristics and risk factors for symptomatic pediatric gallbladder disease. *Pediatrics* 129: e82-88.
56. Guelrud M, Morera C, Rodriguez M, Jaen D, Pierre R (1999) Sphincter of Oddi dysfunction in children with recurrent pancreatitis and anomalous pancreaticobiliary union: an etiologic concept. *Gastrointest Endosc* 50: 194-199.
57. Guelrud M, Mendoza S, Jaen D, Plaz J, Machuca J, et al. (1992) ERCP and endoscopic sphincterotomy in infants and children with jaundice due to common bile duct stones. *Gastrointest Endosc* 38: 450-453.
58. Bogue CO, Murphy AJ, Gerstle JT, Moineddin R, Daneman A (2010) Risk factors, complications, and outcomes of gallstones in children: a single-center review. *J Pediatr Gastroenterol Nutr* 50: 303-308.
59. Sarnaik S, Slovis TL, Corbett DP, Emami A, Whitten CF (1980) Incidence of cholelithiasis in sickle cell anemia using the ultrasonic gray-scale technique. *J Pediatr* 96: 1005-1008.
60. Svensson J, Makin E (2012) Gallstone disease in children. *Semin Pediatr Surg* 21: 255-265.
61. Tannuri AC, Leal AJ, Velhote MC, Gonçalves ME, Tannuri U (2012) Management of gallstone disease in children: a new protocol based on the experience of a single center. *J Pediatr Surg* 47: 2033-2038.
62. Herzog D, Bouchard G (2008) High rate of complicated idiopathic gallstone disease in pediatric patients of a North American tertiary care center. *World J Gastroenterol* 14: 1544-1548.
63. Della Corte C, Falchetti D, Nebbia G, Calacoci M, Pastore M, et al. (2008) Management of cholelithiasis in Italian children: a national multicenter study. *World J Gastroenterol* 14: 1383-1388.
64. Sarli L, Pietra N, Franzé A, Colla G, Costi R, et al (1999) Routine intravenous cholangiography, selective endoscopic retrograde cholangiography and endoscopic treatment of common bile duct stones before laparoscopic cholecystectomy. *Gastrointest Endosc* 50: 200-208.
65. Enochsson L, Lindberg B, Swahn F, Arnelo U (2004) Intraoperative endoscopic retrograde cholangiopancreatography (ERCP) to remove common bile duct stones during routine laparoscopic cholecystectomy does not prolong hospitalization: a 2-year experience. *Surg Endosc* 18: 367-371.
66. Issa H, Al-Salem AH (2011) Role of ERCP in the era of laparoscopic cholecystectomy for the evaluation of choledocholithiasis in sickle cell anemia. *World J Gastroenterol* 17: 1844-1847.
67. Costamagna G, Familiari P, Tringali A, Mutignani M (2007) Multidisciplinary approach to benign biliary strictures. *Curr Treat Options Gastroenterol* 10: 90-101.
68. De Angelis P, Tambucci R, Romeo E, Rea F, Caloisi C, et al. (2013) Does an isolated benign choledochal stricture hide a PSC? *J Pediatr Surg* 48: 1006-1011.
69. Chapman RW, Arborgh BA, Rhodes JM, Summerfield JA, Dick R, et al. (1980) Primary sclerosing cholangitis: a review of its clinical features, cholangiography, and hepatic histology. *Gut* 21: 870-877.
70. Miloh T, Anand R, Yin W, Vos M, Kerkar N, et al. (2011) Pediatric liver transplantation for primary sclerosing cholangitis. *Liver Transpl* 17: 925-933.



71. Mieli-Vergani G, Vergani D (2016) Sclerosing Cholangitis in Children and Adolescents. *Clin Liver Dis* 20: 99-111.
72. Kieling CO, Hallal C, Spessato CO, Ribeiro LM, Breyer H, et al. (2015) Changing pattern of indications of endoscopic retrograde cholangiopancreatography in children and adolescents: a twelve-year experience. *World J Pediatr* 11: 154-159.
73. Rudolph G, Gotthardt D, Klöters-Plachky P, Kulaksiz H, Rost D, et al. (2009) Influence of dominant bile duct stenoses and biliary infections on outcome in primary sclerosing cholangitis. *J Hepatol* 51: 149-155.
74. Gotthardt DN, Rudolph G, Klöters-Plachky P, Kulaksiz H, Stiehl A (2010) Endoscopic dilation of dominant stenoses in primary sclerosing cholangitis: outcome after long-term treatment. *Gastrointest Endosc* 71: 527-534.
75. Gotthardt D, Stiehl A (2010) Endoscopic retrograde cholangiopancreatography in diagnosis and treatment of primary sclerosing cholangitis. *Clin Liver Dis* 14: 349-358.
76. Baba AA, Shera AH, Bhat MA, Hakim S, Sheikh KA, et al. (2010) Management of biliary ascariasis in children living in an endemic area. *Eur J Pediatr Surg* 20: 187-190.
77. Gabrielli S, Calderini P, Dall'Oglio L, Paola de A, Maurizio de A, et al. (2014) Parasitological and molecular observations on a little family outbreak of human fasciolosis diagnosed in Italy. *Scientific World Journal* 417159.
78. Dumonceau JM, Tringali A, Blero D, Devière J, Laugier R, et al. (2012) Biliary stenting: indications, choice of stents and results: European Society of Gastrointestinal Endoscopy (ESGE) clinical guideline. *Endoscopy* 44: 277-298.
79. Bridges A, Wilcox CM, Varadarajulu S (2007) Endoscopic management of traumatic bile leaks. *Gastrointest Endosc* 65: 1081-1085.
80. Castagnetti M, Houben C, Patel S, Devlin J, Harrison P, et al. (2006) Minimally invasive management of bile leaks after blunt liver trauma in children. *J Pediatr Surg* 41: 1539-1544.
81. Steen MW, Bakx R, Tabbers MM, Wilde JC, van Lienden KP, et al. (2013) Endoscopic management of biliary complications after partial liver resection in children. *J Pediatr Surg* 48: 418-424.
82. El-Karaksy HM, El-Koofy NM, Okasha H, Kamal NM, Naga M (2008) A comparative study of endoscopic ultrasonography versus endoscopic retrograde cholangiopancreatography in children with chronic liver disease. *Indian J Med Sci* 62: 345-351.