



Rare Delayed Metastasis of Uveal Melanoma Presenting as Fulminant Liver Failure

Natalia G Vallianou^{1*}, Charikleia Kouvidou², Eleni Geladari¹, Kyriakos Trigkidis¹, Eleni Antypa³ and Evangelos Kokkinakis¹

¹Department of Internal Medicine, Evangelismos General Hospital, Greece

²Department of Pathology, Evangelismos General Hospital, Greece

³Department of Radiology, Evangelismos General Hospital, Greece

***Corresponding author:** Dr. Natalia Vallianou, MD, MSc, PhD, Department of Internal Medicine, Evangelismos General Hospital, 5 Pyramidon str., Municipality of Marathonas, 190 05, Athens, Greec, Tel: +306955692119, E-mail: natalia.vallianou@hotmail.com

Abstract

Uveal melanoma is the most common primary intraocular malignant tumor in adult. Here, we present a patient who died due to hepatic encephalopathy, which was attributed to liver metastasis, which occurred nine years after the revelation of the uveal melanoma.

Keywords

Uveal melanoma, Liver metastasis, Hepatic encephalopathy

Introduction

Uveal melanoma is the most common primary intraocular malignant tumor in adults [1]. After cutaneous melanoma, it is the second most common type of primary melanoma, representing about 3%-5% of all melanoma diagnoses [2]. Here, we present a patient who died due to hepatic encephalopathy, which was attributed to liver metastasis, which occurred nine years after the revelation of the uveal melanoma.

Clinical Summary

A 65-years-old male patient presented to the hospital due to abdominal pain in the right upper quadrant of fifteen days' duration. From his past medical history, the patient had been diagnosed with uveal melanoma of the right eye nine years before for which he had received local radiotherapy.

On clinical examination, the patient appeared icteric, while his liver was palpable and rough. Abnormal laboratory values were as follows: bilirubin: 8.38 mg/dl, gamma-glutamyl-transferase: 931 IU/L, alkaline phosphatase: 553 IU/L and ammonia levels: 112.1 μ mol/L. The patient's computed tomography confirmed the presence of hepatomegaly (diameter = 24 cm) and revealed multiple lesions in the liver, the diameter of the largest one being d = 18 cm (Figure 1). Unfortunately, the patient died due to hepatic encephalopathy and multiple organ dysfunction syndrome.

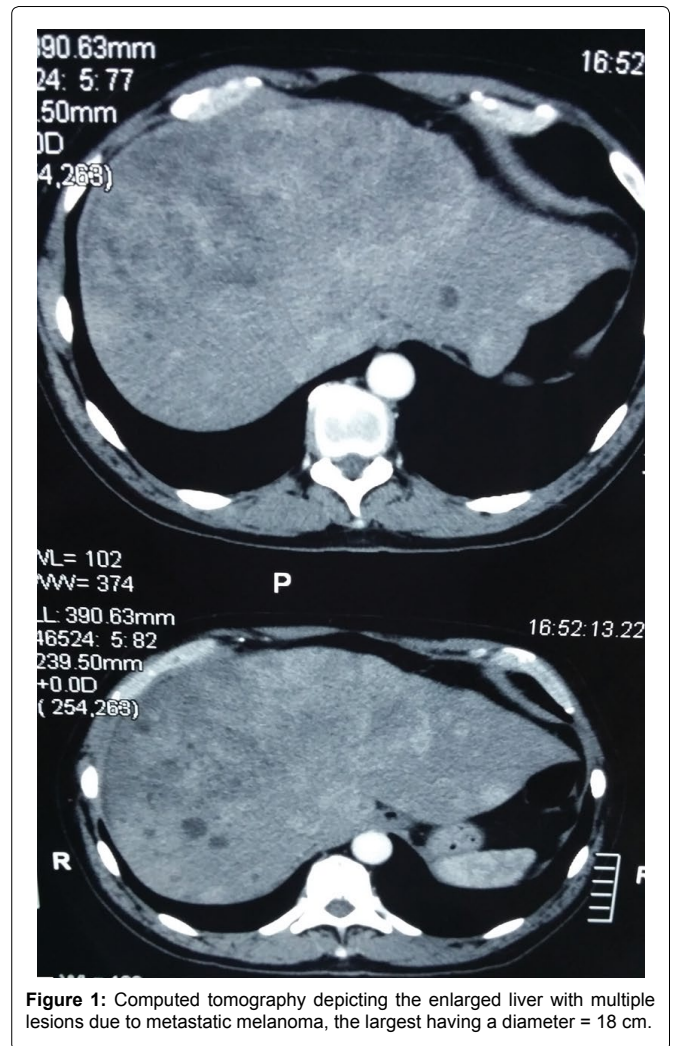


Figure 1: Computed tomography depicting the enlarged liver with multiple lesions due to metastatic melanoma, the largest having a diameter = 18 cm.

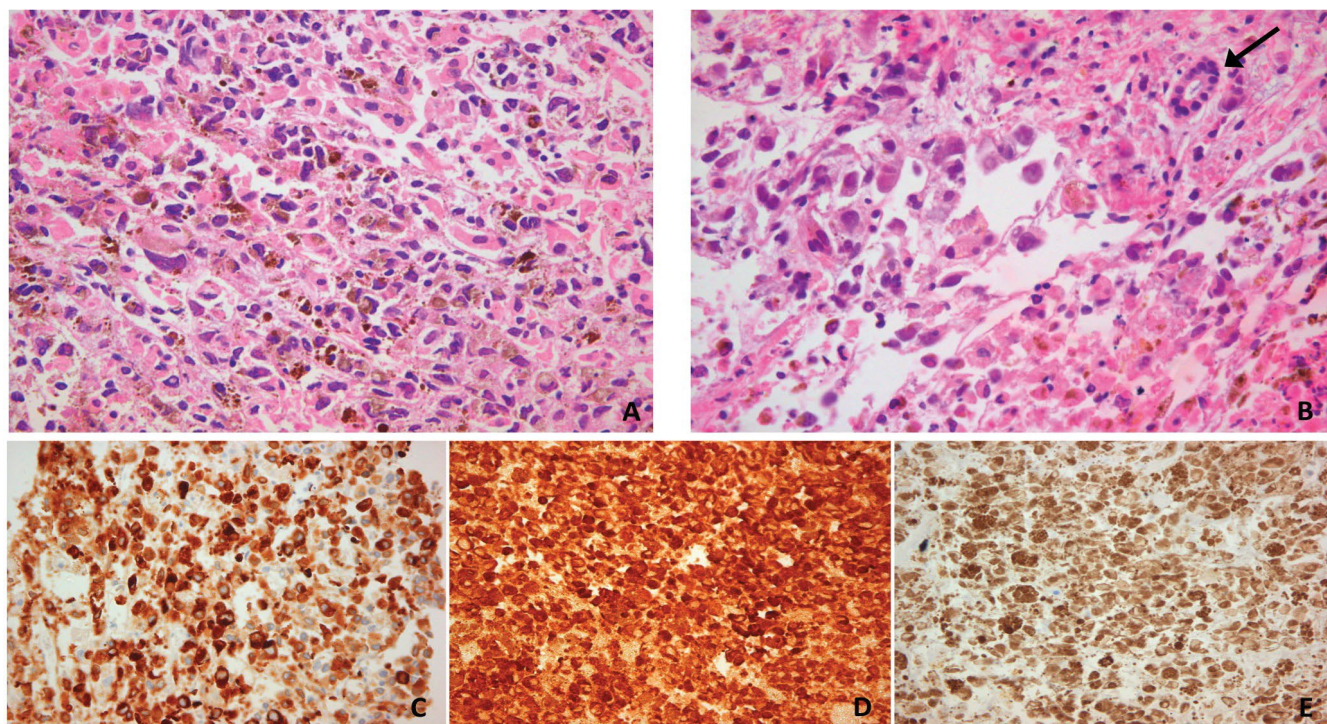


Figure 2: A) Melanoma cells, melanin, melanophages, necrosis (H-EX400); B) An isolated bile duct was observed (H-EX400), Melanoma cells positive for C) Melan-A; D) S-100 protein; E) HMB45.

Pathological Findings

The patient underwent liver biopsy from this mass and histological examination revealed extensive infiltration of liver tissue by a malignant tumour with solid growth pattern, spindle cells, prominent nucleoli, necrosis, pigment and multiple melanophages. Immunohistochemistry was positive for Melan-A, HMB45, S-100 protein and MITF-1, compatible with metastasis from uveal melanoma (Figure 2).

Discussion

The mean incidence of uveal melanoma in the United States is 5 new cases per million people, approximately [2]. The peak incidence of uveal melanoma occurs from 65 to 70 years [3]. About 98.8% of the cases occur in Caucasians. Primary uveal melanoma arises from melanocytes located in the uveal tract, which comprises the iris, the ciliary body, and the choroid of the eye [3]. Melanomas of the posterior uveal tract, which are diagnosed late due to their location, tend to be more aggressive, metastasize often, and have the worst prognosis [3,4]. Mutations in genes GNAQ, GNA11 and PTEN, the helix-loop-helix inhibitor ID2, miRNA-21, c-Kit and BRAF, as well as chromosome 3, 6 and 8 alterations have been implicated in the development of uveal melanoma [5].

Over 95% of patients have disease limited to the eye at diagnosis. Patients with uveal melanoma often receive eye-preserving plaque radiation therapy and have the same survival as those who undergo enucleation of the eye. Approximately 40% to 50% of patients with primary uveal melanoma develop systemic metastases [6].

The 5-year and 15-year survival rates from diagnosis of uveal melanoma are 45% and 30%, respectively [6]. The survival of patients with metastatic uveal melanoma is directly related to the site of metastasis. The liver is involved in as many as 95% of individuals who develop metastatic disease and is the exclusive site of systemic metastasis in about 40% of patients [7,8]. Other common metastatic sites involved include lung (46%), bone (29%) and skin (17%) [8,9]. Clinical course of uveal melanoma is determined by progression of the disease in the liver. Metastases are frequently detected within 5 years of treatment of uveal melanoma. Upon the occurrence of liver metastases, the lesions are usually multiple and difficult to resect [5]. A number of cytotoxic agents have been used, such as

dacarbazine, treosulfan, temozolomide, fotemustine, cisplatin as well as combination therapies, such as bleomycin, vincristine, lomustine, and dacarbazine. The response rate to systemic chemotherapy is very poor ranging from 0% to 15%, with no evidence that it extends survival in patients with metastatic uveal melanoma. Median survival of patients who develop liver metastasis is reported to be 6 to 7 months, and the one-year survival rate is estimated to be 10% to 15% [9,10]. Furthermore, a few cases of spontaneous rupture of metastatic hepatic melanoma have been reported [11].

The median time to systemic tumor recurrence in recently published review of uveal melanoma cases was three years and four months. The incidence of recurrence 10 or more years after initial diagnosis was only 2.4% [12,13].

Our patient died due to hepatic encephalopathy that was attributed to liver metastases, among which one with 18 cm diameter. These liver metastases were detected nine years after the first occurrence of uveal melanoma, which was treated with local radiotherapy, but not encapsulation of the eye.

To our knowledge, this is one of the few case reports in the literature, with such a late recurrence of a systemic metastasis of uveal melanoma. These metastases, which could not be resected, led our patient to death due to hepatic encephalopathy without having any systemic chemotherapy, because of the high bilirubin levels (8.38 mg/dl). This case may support the notion that uveal melanoma strikes back even after many years of the revelation of the uveal melanoma and therefore close monitoring of the patients for many years is mandatory.

Conflict of Interest Statement

None declared.

References

1. Abramson DH, Scheffler AC, Dunkel IJ (2006) Neoplasms of the eye. In: Bast R Jr., Kufe D, Pollick R, Cancer Medicine. (7th edn), BC Decker: 1071-1083.
2. Singh AD, Turell ME, Topham AK (2011) Uveal melanoma: trends in incidence, treatment, and survival. *Ophthalmology* 118: 1881-1885.
3. Singh AD, Bergman L, Seregard S (2005) Uveal melanoma: epidemiologic aspects. *Ophthalmol Clin North Am* 18: 75-84.

4. Yap-Veloso MI, Simmons RB, Simmons RJ (1997) Iris melanomas: diagnosis and management. *Int Ophthalmol Clin* 37: 87-100.
5. Lin S, Wan D, Chen H, Chen K, Zheng S (2015) Complete resection of isolated hepatic metastatic uveal melanoma with a notably long disease-free period: A case report and review of the literature. *Oncol Lett* 10: 196-200.
6. Kolandjian NA, Wei C, Patel SP, Richard JL, Dett T, et al. (2013) Delayed systemic recurrence of uveal melanoma. *Am J Clin Oncol* 36: 443-449.
7. Kujala E, Mäkitie T, Kivelä T (2003) Very long-term prognosis of patients with malignant uveal melanoma. *Invest Ophthalmol Vis Sci* 44: 4651-4659.
8. Bedikian AY, Legha SS, Mavligit G, Carrasco CH, Khorana S, et al. (1995) Treatment of uveal melanoma metastatic to the liver: a review of the MD Anderson Cancer Center experience and prognostic factors. *Cancer* 76: 1665-1670.
9. Kath R, Hayungs J, Bornfeld N, Sauerwein W, Höffken K, et al. (1993) Prognosis and treatment of disseminated uveal melanoma. *Cancer* 72: 2219-2223.
10. Gragoudas ES, Egan KM, Seddon JM, Glynn RJ, Walsh SM, et al. (1991) Survival of patients with metastases from uveal melanoma. *Ophthalmology* 98: 383-389.
11. Chun HJ, Osuga K, Fahrni M, Nakamura H (2010) Massive bleeding of ruptured metastatic hepatic melanoma treated by transarterial embolization. *Jpn J Radiol* 28: 395-397.
12. Bedikian AY (2006) Metastatic uveal melanoma therapy: current options. *Int Ophthalmol Clin* 46: 151-166.
13. Torossian NM, Wallace RT, Hwu WJ, Bedikian AY (2015) Metastasis of ciliary body melanoma to the contralateral eye: a case report and review of uveal melanoma literature. *Case Rep Oncol Med* 2015: 427163.