



CASE REPORT

Inferior Dislocation of the Shoulder Complicated with Brachial Plexus Palsy: A Case Report

Hamdi Kaziz*, Mohamed Amine Triki, Sofien Benzarti, Thabet Mouelhi, Nader Naouar and Mohamed Laziz Ben Ayeche

Orthopedics Department, Sahloul University Hospital, Sousse, Tunisia

*Corresponding author: Hamdi Kaziz, Orthopedics Department, Sahloul University Hospital, Sousse, Tunisia, Tel: +21698366196



Abstract

Introduction: Inferior dislocation of the shoulder is a rare injury. Some specific complications may occur immediately or during follow-up. We present a rare case of erecta dislocation with a neurological injury.

Case presentation: We report a 23-year-old female admitted for erecta dislocation on her right shoulder after sport accident complicated with a fracture of the greater tuberosity and axillary nerve palsy. A closed reduction had been indicated with a reduction of both fracture and dislocation. Functional treatment had been adopted. The neurapraxia had resolved spontaneously. At last outcome, the patient is satisfactory with a full range of motion on her right shoulder.

Discussion: Inferior shoulder dislocation leads, usually to tears on soft tissue of the shoulder especially capsular, labral and inferior glenohumeral ligament. Immediate complications are serious such as neurological palsy and vascular problems. Indications depend on reducibility and associated injuries.

Conclusion: Neurological complication especially neurapraxia is a serious injury but did not require open reduction and surgical exploration explained by the traction at the point where the axillary nerve passes through the quadrangular space.

Keywords

Inferior shoulder dislocation, Luxatio erecta, Brachial plexus palsy, Fracture

Introduction

Luxatio erecta humeri are an extremely uncommon injury of the shoulder. The reported mechanism is usually a hyper-abduction of the arm, so that the humeral

neck is levered against the acromion causing inferior displacement of the humeral head through the capsule tears. Similar to all shoulder injuries, several complications may occur in shoulder erecta dislocation. There are few reports regarding associated injuries to this entity.

We report a 23-year-old female, who sustained inferior dislocation of her right shoulder with an avulsion fracture of the greater tuberosity and transient neurapraxia of the axillary nerve.

Case Report

A 23-year-old female was admitted to our department after a sport event. She was suffering from major right shoulder pain and fixed arm on hyper-abduction position. She was pitcher player women, falling with an abducted shoulder and flexed right elbow. Physical examination revealed a right shoulder in hyper-abduction position, flexion at the elbow and with the forearm resting on the patient's head (Figure 1). Severe pain forbids any joint mobility. The humeral head was palpable against the lateral thoracic wall near the scapula. The radial pulse is detected at the right wrist. Hypoesthesia with muscle weakness was noted over the right forearm and hand. The function of the axillary nerve did not be tested minutely because of the severe pain. Neurological examination revealed sensory impairment in the middle finger of the right hand and hypoesthesia of the postero-lateral aspect of the right shoulder.

The X-ray findings showed the humeral shaft pointed

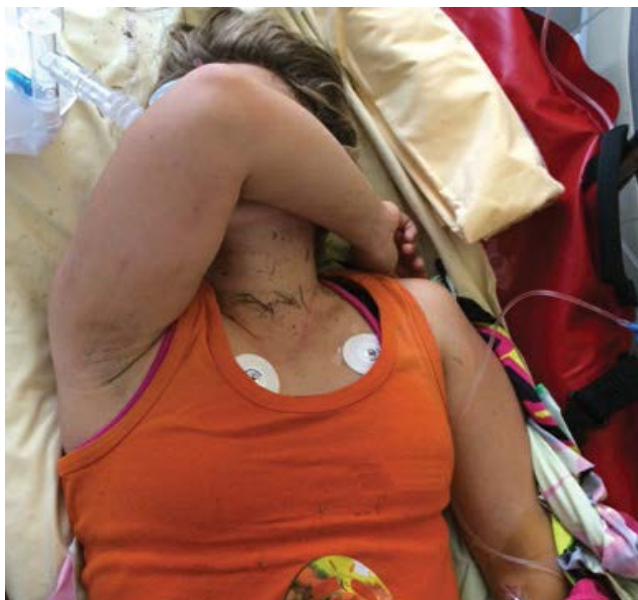

Figure 1: Clinical presentation of the patient in the emergency room with an abducted arm and impossibility of mobilization of the right shoulder.

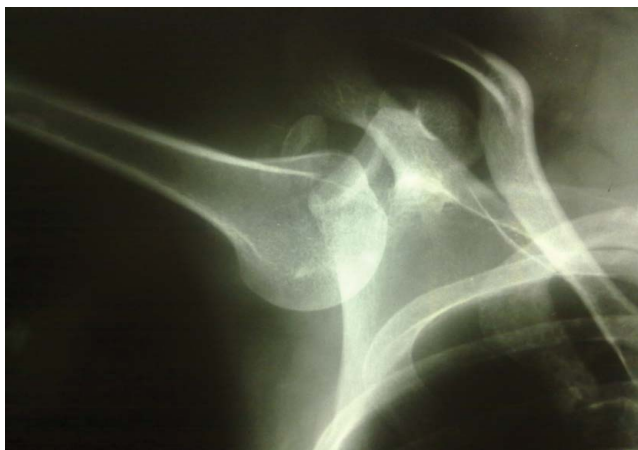

Figure 2: Antero-posterior X-ray view of the right shoulder: Inferior dislocation associated with a fracture of the greater tuberosity.

up, in a rotated position, with the dislocated humeral head below the glenoid fossa associated with greater tuberosity fracture (Figure 2). Manipulative reduction by traction-counter-traction was performed immediately under general anesthesia. Counter-traction was applied with a rolled bed sheet placed superior to the shoulder. The radiographic views, checked immediately after close reduction, revealed anatomic reduction of the humeral head into the glenoid fossa and reduction of the greater tuberosity fracture (Figure 3).

Immobilization with a sling was applied postoperatively to allow healing of inferior capsular soft tissue. The sling was removed 3 weeks later, shoulder's rehabilitation was undergone.

At 10 months postoperatively, the patient didn't report neither pain nor neurological palsy. She regained a nearly full active range of motion in the shoulder and had no apprehension or instability toward elevation

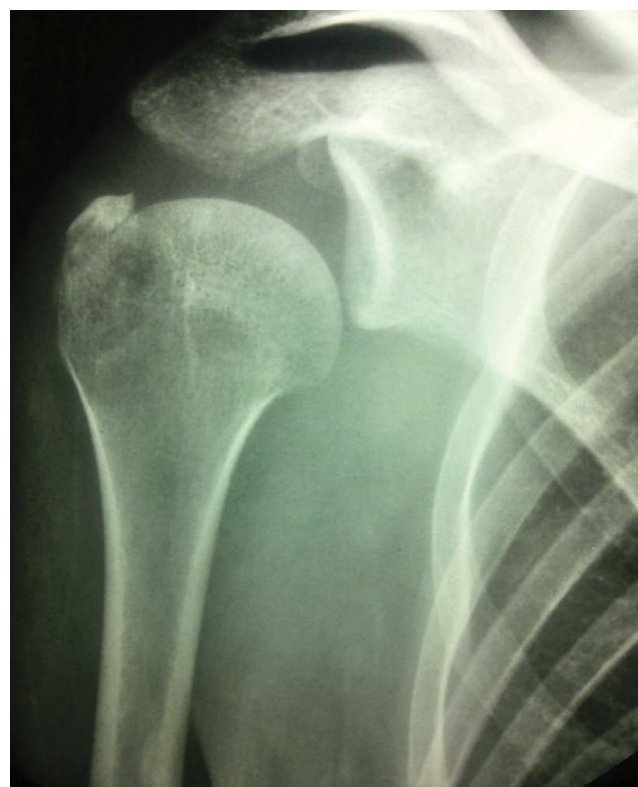

Figure 3: Antero-posterior X-ray view of the right shoulder after closed reduction of the dislocation with a reduction of the greater tuberosity.

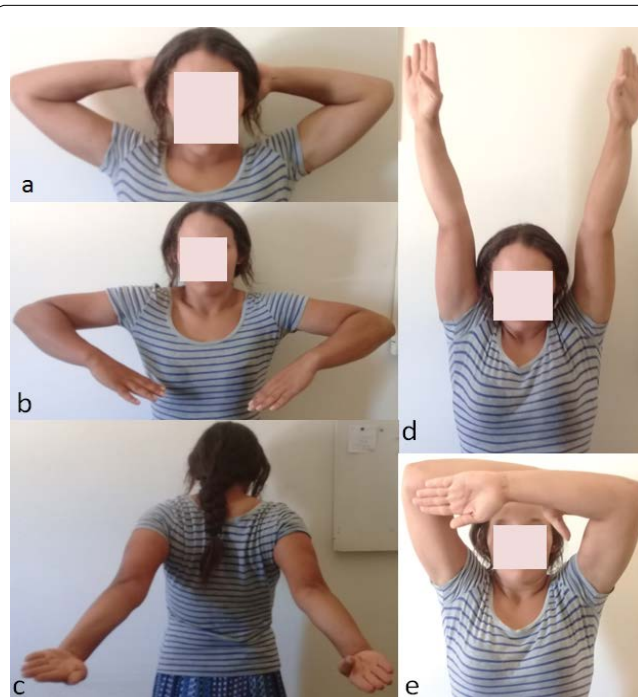


Figure 4: Functional outcome at last follow-up with a satisfactory range of motion of the right shoulder: a) Full external rotation with an abducted arm; b) Full internal rotation with an abducted arm; c) Full extension of the right shoulder compared to the left one; d) Full flexion of the shoulder; e) Full external rotation in maximal abducted arm.

or rotation (Figure 4). X-ray findings showed union of the greater tuberosity (Figure 5). The Constant-Murley score was 85 points at last follow-up. Before the injury, the Constant-Murley score was 100 points.

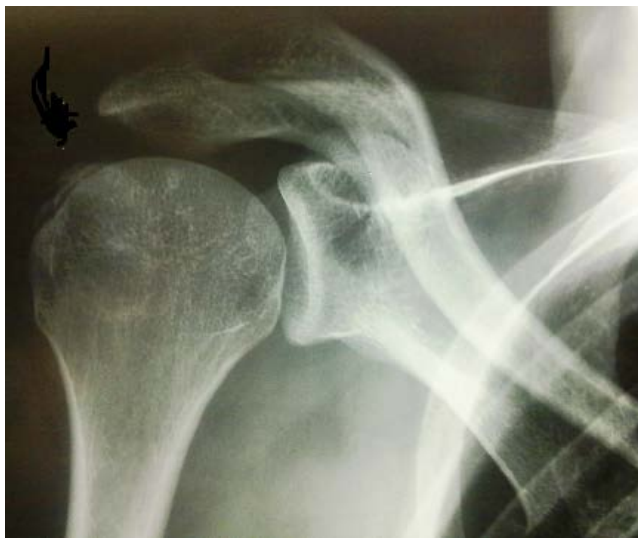

Figure 5: Antero-posterior X-ray view of the right shoulder at final outcome.

Discussion

Luxatio erecta, or inferior shoulder dislocation, is an extremely rare variety of shoulder dislocations and worth reporting [1]. The first description was in 1859 by Middeldorpf and Scharm [2]. It accounts for less than 1% of all shoulder dislocations [2,3]. The classical presentation is described by Simpson with the arm fully abducted, elbow flexed, and the forearm resting on or behind the patient's head [4]. This injury can occur at any age [5,6]. The clinical presentation is dramatic [6]. Creases may be present over the superior aspect of the shoulder and the glenoid fossa will be empty with the humeral head palpable on the lateral chest wall [4,7,8]. The patient generally resists any attempt at movement of the affected arm [4,8]. Several immediate neurovascular complications may occur including brachial plexus, the axillary nerve and the axillary vessels [9,10]. Diagnosis and documentation of these complications before the reduction is compulsory from the medico-legal point of view and also for proper primary management of these injuries [11]. The pathomechanics of the luxatio erecta is well described in the literature: It involves hyper-abduction of the humerus [12]. As the humerus is abducted, it impinges upon the acromion, causing a tear in the inferior gleno-humeral capsule and disruption of the rotator cuff [13]. Careful attention must be directed toward making the distinction between anterior and inferior shoulder dislocations [13,14]. A recent report describing luxatio erecta suggests it was initially misdiagnosed as an anterior dislocation and standard approaches to reduction of anterior dislocation were unsuccessful [14]. Some complications may occur: First, recurrence of inferior dislocation is very unusual especially before 45 year explained by the inferior capsular tears and humeral avulsion of glenohumeral ligament (HAGL) [15]. The damage in inferior glenohumeral ligament and labrum are usually found on MRI [16]. Second, soft tissues damages of various shoulder tendons

and muscles (supraspinatus, infraspinatus, subscapularis, and pectoralis major) [14-16]. Third, some specific concomitant fractures may occur such as fractures of the clavicle, coracoid, acromion, inferior glenoid, and greater tuberosity of the humerus [14,15]. Fracture of the greater tuberosity of the humerus reportedly spares injury to the rotator cuff. The greater tuberosity was avulsed by the rotator cuff when the humeral head dislocated inferiorly [17]. Fourth, concerning the neurological injuries, there are present at approximately in 60% of cases, most commonly to the axillary nerve probably due to traction at the point it passes through the quadrangular space [11,18]. All the three cords of the brachial plexus pass through the axilla and would be tethered in the dislocated position, and accordingly, our case presented the symptoms of hypoesthesia and muscle weakness over the right forearm and hand before closed reduction. The neurological defect usually resolved between 1 day and 6 months [11]. Finally, 3.3% of cases are complicated by vascular injury, which is usually associated with a decreased radial pulse [19].

Most cases of luxatio erecta can be managed by closed reduction in the emergency department, unless a buttonhole incarceration of the inferior capsule exists; then open reduction may be necessary [14].

Reduction of luxatio erecta is most easily accomplished by superolateral longitudinal traction on the arm with some gentle rotator movements [14,20]. Adequate muscle relaxation and anesthesia are essential for reduction [14]. One method of reduction involves in-line traction of the fully abducted arm superiorly as upward pressure is applied to the humeral head. Simultaneous counter-traction is applied inferiorly with a folded sheet placed over the top of the shoulder [20]. The shoulder immobilization is an important step of treatment [20]. An anterior dislocation may occur during reduction [21]. Post reduction antero-posterior and lateral radiographs are examined for adequate reduction and associated fractures [20,21].

Accurate diagnosis of inferior shoulder dislocation, with attention to neurovascular compromise, will prevent iatrogenic injuries and complications during closed reduction.

If the technique of closed reduction is correctly applied and the associated fractures are adequately treated, the functional recovery of the shoulder joint is nearly complete, and the clinical results will be excellent [22].

Conclusion

A rare case of inferior shoulder dislocation complicated with neurological axillary nerve palsy is reported in this article. The aim of these papers is to review the specific pathomechanics of this dislocation and evaluate the final outcome especially of the neurological complications which resolve often spontaneously. Closed reduction under general anesthesia is required according

to a specific technique. Open reduction should be indicated in front of irreducible dislocation and concomitant displaced fractures.

References

1. Elouakili I, Ouakrim R, Ouchrif Y, Kharmaz M, Ismael F, et al. (2014) Dislocation erecta. *Pan Afr Med J* 18: 70.
2. Middeldorpf M, Scharm B (1859) De nova: Humeri luxationis specie. *Clinique Europeenne* 2: 12-16.
3. Daniel A Fung, Marc Menkowitz, Kenneth Chern (2008) Asymmetric bilateral shoulder dislocation involving a luxatio erecta dislocation. *Am J Orthop (Belle Mead NJ)* 37: E97-E98.
4. P Ellanti, N Davarinos, MJ Connolly, HA Khan (2013) Bilateral luxatio erecta humeri with a unilateral brachial plexus injury. *J Emerg Trauma Shock* 6: 308-310.
5. PJ Rae, BS Sylvester (1988) Luxatio erecta-two cases without direct injury. *Injury* 19: 361-362.
6. Ronald G Pirralo, Tresso P Bridges (1990) Luxatio erecta: A missed diagnosis. *Am J Emerg Med* 4: 315-317.
7. Sonanis SV, Das S, Deshmukh N, Wray C (2002) A true traumatic inferior dislocation of shoulder. *Injury* 33: 842-844.
8. Frank MA, Laratta JL, Tan V (2012) Irreducible luxatio erecta humeri caused by an aberrant position of the axillary nerve. *J Shoulder Elbow Surg* 21: e6-e9.
9. Relwani JG, Nikolopoulous I, Turnbull TJ, Turner R, Brooks M (2007) Luxatio erecta in an adolescent with axillary artery and brachial plexus injury. *Injury Extra* 38: 456-458.
10. Gardham JR, Scott JE (1979) Axillary artery occlusion with erect dislocation of the shoulder. *Injury* 11: 155-158.
11. Nambiar M, Owen D, Moore P, Carr A, Thomas M (2018) Traumatic inferior shoulder dislocation: A review of management and outcome. *Eur J Trauma Emerg Surg* 44: 45-51.
12. Mallon WJ, Bassett FH 3rd, Goldner RD (1990) Luxatio erecta: The inferior glenohumeral dislocation. *J Orthop Trauma* 4: 19-24.
13. Tracy SC, Myer JJ (2009) Arthroscopic evaluation and management after repeated luxatio erecta of the glenohumeral joint. *Orthopedics* 32: 367.
14. Toolanen G, Hildingsson C, Hedlund T, Knibestöl M, Oberg L (1993) Early complications after anterior dislocation of the shoulder in patients over 40 years. An ultrasonographic and electromyographic study. *Acta Orthop Scand* 64: 549-552.
15. Perron AD, Ingerski MS, Brady WJ, Erling BF, Ullman EA (2003) Acute complications associated with shoulder dislocation at an academic emergency department. *J Emerg Med* 24: 141-145.
16. Krug DK, Vinson EN, Helms CA (2010) MRI findings associated with luxatio erecta humeri. *Skeletal Radiol* 39: 27-33.
17. Saxena V, Pradhan P (2013) Bilateral luxatio erecta with greater tuberosity fracture: A case report. *J Clin Orthop Trauma* 4: 185-189.
18. Emadian SM, Lee WW (1996) Axillary artery pseudoaneurysm and axillary nerve palsy: Delayed sequelae of anterior shoulder dislocation. *Am J Emerg Med* 14: 108-109.
19. Plaga BR, Looby P, Feldhaus SJ, Kreutzmann K, Babb A (2010) Axillary artery injury secondary to inferior shoulder dislocation. *J Emerg Med* 39: 599-601.
20. Nho SJ, Dodson CC, Bardzik KF, Brophy RH, Domb BG, et al. (2006) The two-step maneuver for closed reduction of inferior glenohumeral dislocation (luxatio erecta to anterior dislocation to reduction). *J Orthop Trauma* 20: 354-357.
21. Poole LJ (2013) Luxatio erecta: Utilisation of the two-step reduction technique without intravenous sedation by an emergency nurse practitioner. *Emerg Med Australas* 25: 476-477.
22. Gordon I Groh, Michael A Wirth, Charles A Rockwood Jr (2010) Results of treatment of luxatio erecta (inferior shoulder dislocation). *J Shoulder Elbow Surg* 19: 423-426.