



CASE REPORT

Laryngeal Abscess in a Patient with End Stage Liver Disease - An Enigma

Dinesh Jothimani¹, Ramya S^{2*}, Purushothaman PK³, Vidya Devarajan⁴, Vaibhav Patel⁵, Akila Rajakumar⁶ and Mohamed Rela⁷



¹Department of Liver Disease & Transplantation Director, Dr. Rela Institute and Medical Centre, India

²Department of Infectious disease, Dr. Rela Institute and Medical Centre, India

³Senior Consultant, Department of ENT, Neurotology & Skull Base Surgery, Dr. Rela Institute and Medical Centre, India

⁴Senior Consultant, Infectious Diseases, Dr. Rela Institute and Medical Centre, India

⁵Consultant, Department of Liver Disease & Transplantation, Dr. Rela Institute and Medical Centre, India

⁶Senior Consultant and Clinical Lead, Department of Anesthesia and Intensive Care, Dr. Rela Institute and Medical Centre, India

⁷Chairman and Director, Department of HPB Surgery & Liver Transplantation, Dr. Rela Institute and Medical Centre, India

*Corresponding author: Dr. Ramya S, Fellow, Department of Infectious Disease, Dr. Rela Institute and Medical Centre, India, Tel: +917708197845

Abstract

Background: Patients with liver cirrhosis are more prone to life-threatening bacterial infections. Presence of immune dysfunction and altered gut microbiome has been largely attributed to the cause of sepsis, particularly secondary to gram negative organisms in these patients.

Case report: We hereby report a case of Chronic liver disease who presented with acute stridor, hoarseness of voice and dyspnea for 4 days. Local examination of the airway showed left lateral laryngeal wall edema with marked airway narrowing. A video laryngoscopy was performed in view of stridor which revealed edematous tissue on the lingual surface of the epiglottis, edema in bilateral arytenoids and the ventricles, with no visibility of the vocal cords on either side suggestive of laryngeal abscess. His blood cultures grew *Klebsiella pneumoniae* (pan-sensitive). He was started on appropriate antibiotic therapy. The patient responded well, and a repeat video laryngoscopy showed a drastic improvement. He gradually improved, and antibiotics were continued. He was discharged after 2 weeks, and he made a remarkable recovery. He was closely followed up as an outpatient in view of his advanced liver disease and airway involvement. Approximately after 4 weeks of antibiotic therapy, he underwent deceased donor liver transplantation. In accordance with the treatment plan, the patient was discharged and there was no evidence of the recurrence of an abscess. He was followed up periodically

in the transplant clinic, and he has done well. Here we highlight rare case of laryngeal abscess in a patient who grew *Klebsiella* in blood thus a possibility of laryngeal abscess secondary to *Klebsiella* was postulated. He was treated conservatively with IV antibiotics, and he improved without the drainage of the abscess.

Conclusion: In addition to the known risk factors for hyper-virulent *Klebsiella* it is important to note that cryptogenic decompensated end-stage liver disease also serves as a risk factor for infection. Hence, early detection and treatment of this infection is important since *Klebsiella pneumoniae* is a highly virulent organism that can have serious metastatic consequences.

Keywords

Klebsiella pneumoniae, Laryngeal abscess, End stage liver disease

Introduction

Sepsis is a major cause of morbidity and mortality in patients with liver cirrhosis. It may cause rapid progression of underlying liver disease leading to various complications including hepatic encephalopathy, variceal bleed and hemodynamic instability. The presence of immune dysfunction and altered gut

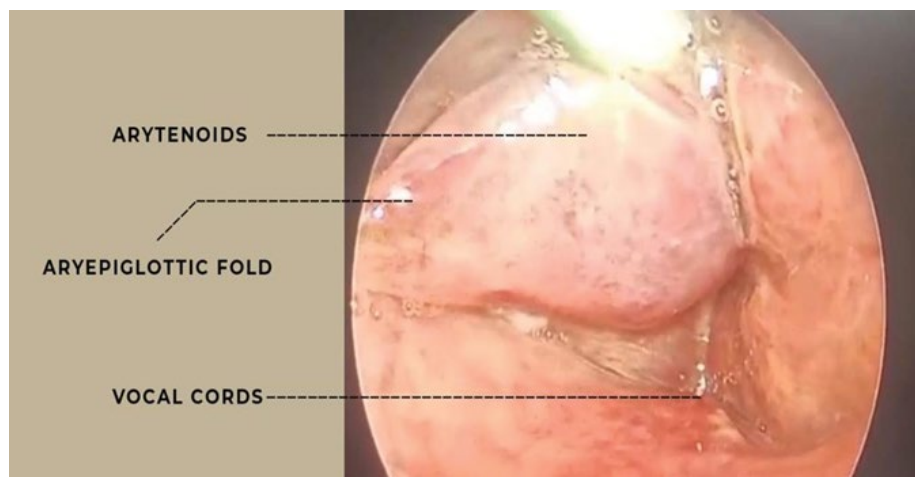


Figure 1: Video laryngoscopy (Pre-Treatment): Shows oedematous tissue on the lingual surface of the epiglottis, oedema in the bilateral arytenoids and the ventricular bands, with no visibility of the vocal cords on either side suggestive of laryngeal abscess.

microbiome has been largely attributed to the cause of sepsis, particularly secondary to gram negative organisms in patients with cirrhosis. Sepsis destabilizes stable cirrhotic patients precipitating decompensation or Acute on chronic liver failure. Pneumonia, spontaneous bacterial peritonitis, urinary tract infection and cellulitis are the common sites of infection in these patients. Here we report a patient with End stage liver disease (ESLD) awaiting deceased donor liver transplantation (DDLT), presented with laryngeal abscess. This study was approved by the Institutional Review Board and informed consent from the patient was taken.

Case Report

A 58-year-old gentle-man with ESLD due to non-alcohol related steatohepatitis (NASH) waitlisted for DDLT presented to the emergency shortness of breath, fever and hoarseness of voice for 4 days followed by a sudden onset and a rapidly progressive stridor. There was no history of allergies or foreign body ingestion. Upon presentation, his heart rate 111, BP 140/80 mmhg, SpO₂ 98, ABG showed metabolic acidosis. He immediately received steroids and adrenaline injection as per protocol. Unfortunately, there was no resolution of his symptoms. A video laryngoscopy was performed in view of stridor which revealed oedematous tissue on the lingual surface of the epiglottis, oedema in bilateral arytenoids and the ventricular bands, with no visibility of the vocal cords on either side (Figure 1). He was provided with a tracheostomy on an emergency basis for securing airway in ICU. His complete blood count showed Hemoglobin 12 gm/dl, Platelet count 42,000/cubic mm, Total leukocyte count 8930/cubic mm, Total bilirubin 3.53 mg/dL, ALP 103, ALT 57, AST 60, GGT 14, INR 1.99 and Creatinine 1.44 mg/dL. He was commenced on broad spectrum antibiotics IV Piperacillin-Tazobactam 4.5 gm every 6th hourly after sampling blood culture, which later showed Gram-negative bacilli, subsequently, identified as *Klebsiella*

pneumonia. Antibiotics were rationalized based on antibiotic susceptibility pattern was de-escalated to ceftriaxone 2 gm. There was clinical improvement. On Day 11 of admission, the patient developed altered sensorium suggestive of hepatic encephalopathy. His blood tests showed Haemoglobin 11.4 gm/dl, Platelet count 49,000/cubic mm, Total leukocyte count 10650/cubic 16 17 mm, Total bilirubin 1.42 mg/dL, ALP 113, ALT 39, AST 39, GGT 28, INR 1.5 and Creatinine 1.50 mg/dL. A neuroimaging did not show any organic cause. With anti-encephalopathy measures along with change of antibiotics to intravenous meropenem showed clinical improvement. Following clinical resolution, a repeat video laryngoscopy showed improvement and reduction in the oedema. The right vocal cord was movable while left vocal cord fixation was seen. He received intravenous antibiotics for 4 weeks and was discharged with tracheostomy valve *in situ* following clinical resolution. During his outpatient review, follow-up video laryngoscopy revealed normal epiglottis, arytenoids, and ventricles and oedema from the previous video laryngoscopy completely resolved, the right vocal cord was mobile and left vocal cord fixation persisted (Figure 2). He underwent DDLT 6 weeks later and his post-operative course was uneventful [1-5].

Discussion

Laryngeal abscess is a rare but life-threatening infection that can be caused by a variety of microorganisms, including *Streptococcus pyogenes*, *Staphylococcus aureus*, and anaerobic bacteria. *Klebsiella pneumoniae* is a gut derived gram-negative bacterium that is commonly associated with hospital-acquired infections, particularly in immunocompromised patients including cirrhotic. *Klebsiella pneumoniae* is usually encountered in ascitic fluid, blood stream, urinary tract and in cellulitis of patients with liver cirrhosis, but not reported in laryngeal abscess. The antibiotic treatment of choice for laryngeal abscesses should be broad

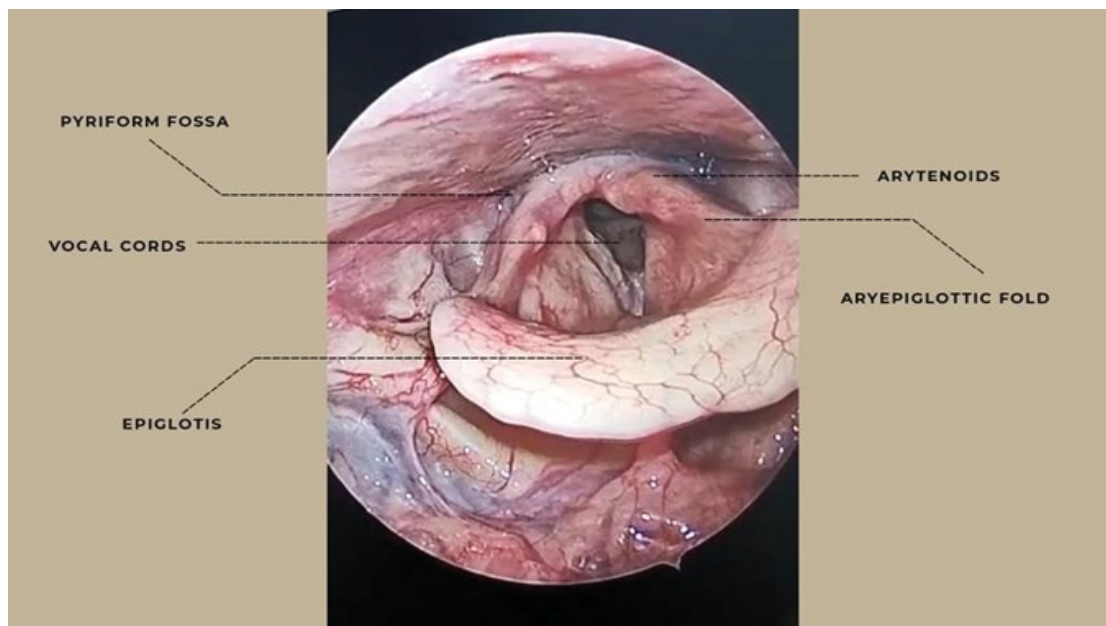


Figure 2: Video laryngoscopy (Post-Treatment): Showed normal epiglottis, arytenoids, and ventricles and oedema from the previous video laryngoscopy completely resolved, the right vocal cords mobile and left vocal cord fixation persisted.

spectrum followed by sensitivity-based approach, for a prolonged period. Early recognition and prompt treatment is important to prevent potentially life-threatening complications, such as airway obstruction, mediastinitis, meningitis, endophthalmitis, and septic shock and to prevent invasive *Klebsiella* syndrome. In our case, laryngeal abscess was not drained. Blood culture showed the growth of pan-sensitive *Klebsiella pneumoniae*. He was started on and he responded well and a repeat Video Laryngoscopy showed drastic improvement. From these findings we assume that this laryngeal abscess was likely due to metastatic seeding of *Klebsiella pneumoniae* bacteremia and when treated with prolonged antibiotic therapy for complete clinical improvement.

Conclusion

We highlight this rare case of laryngeal abscess possibly due to *Klebsiella pneumoniae* with bacteremia, which was successfully managed with prolonged parenteral antibiotic and without drainage. It is important to note that Cryptogenic decompensated end-stage liver disease, serves as a risk factor for such a fatal infection in addition to the known risk factors for hyper virulent *Klebsiella*. Hence early detection and treatment of this infection is important since *Klebsiella pneumoniae* is a highly virulent organism that can have serious metastatic consequences.

Acknowledgements

Dr. Subha, Consultant Microbiologist, Dr. Rela Institute and Medical Centre; Dr. Sweatha, ID fellow, Department of Infectious Diseases. Dr. Rela Institute and Medical Centre.

Source of Support

Not applicable.

Authors Contribution

All authors equally contributed to the study.

References

- Howard RE (1931) Laryngeal abscess. *The Laryngoscope* 41: 344-347.
- Kernan JD, Schugt HP (1933) Primary submucous laryngeal abscesses. *Arch Otolaryngol* 17: 22-29.
- Souliere CR, Kirchner JA (1985) Laryngeal perichondritis and abscess. *Arch Otolaryngol* 111: 481-484.
- Zapanta PE, Bielamowicz SA (2004) Laryngeal abscess after injection laryngoplasty with micronized AlloDerm. *Laryngoscope* 114: 1522-1524.
- Canalis RF, Jenkins HA, Osguthorpe JD (1979) Acute laryngeal abscesses. *Ann Otol Rhinol Laryngol* 88: 275-279.