



CASE REPORT

Early and Isolated Cerebral Fat Embolism in a Trauma Patient with Multiple Fracture - A Case Report

Adriano Braile^{1,2*}, Carlo Maurea³, Giuseppe Toro¹, Antonio Bove², Nicola Orabona² and Giovanni Matino²

¹Department of Medical and Surgical Specialties and Dentistry, University of Campania "Luigi Vanvitelli", Naples, Italy

²Department of Orthopaedic and Trauma Surgery, Ospedale del Mare, Naples, Italy

³Department of Neurology, Ospedale del Mare, Naples, Italy

***Corresponding author:** Adriano Braile, Department of Medical and Surgical Specialties and Dentistry, University of Campania "Luigi Vanvitelli", 80138 Naples, Italy; Department of Orthopaedic and Trauma Surgery, Ospedale del Mare, 80147 Naples, Italy



Background

Fat embolism syndrome (FES) is defined as the presence of fat particles (i.e., > 100 particles per mm²) in the blood circulation that result in symptoms and/or organ failure. FES could result from mechanical causes, trauma or sepsis and, even if very rare, is a fatal disease that develops within 12-72 hours. FES manifestations can vary from mild cognitive changes to coma and even cerebral edema and brain death. The exact incidence of FES stemming from traumatic long bone injuries varies in literature, from 0.9% when clinical criteria are used for diagnosis to 29% in post-mortem autopsies [1]. Cerebral fat embolism (CFE) has been described in about 10% of FES cases based on clinical criteria, but the true incidence is also unclear due to the absence of definitive diagnostic testing [2]. We present a case of isolated CFR with no intracardiac shunt or pulmonary dysfunction in a polytrauma patient of 20-years-old.

Case Presentation

A 20-years-old male was admitted to our emergency department for a road car accident with a diagnosis of bilateral lower extremities fractures (tibial shaft fracture and femoral neck fracture). After six hours he underwent a surgical intervention of endomedullary nailing for both fractures (Figure 1). Before surgery, this

patient was conscious at all times but 24 hours after surgery, he manifested state of confusion, with episodes characterized by delusional ideation, confabulation and psychomotor agitation. On neurological physical examination, the patient was alert, disoriented in time, cranial nerves appeared uninjured, and there were no focal limb signs. Brain CT scan and electroencephalogram showed no abnormalities. Due to the persistence of the symptomatology, MRI of the brain was performed, which showed multiple, millimeter-long areolae of pathological signal restriction in DWI study sequences at the bilateral nucleocapsular region, corona radiata, deep white matter and juxtacortical on both sides as well as at the posterior frontal cortical site. Additional similar areas were found at the posterior median and paramedian right commissural region and at bilateral retro trigonal site. These findings were compatible with multiple embolic-based ischemic foci in an evolving phase (Figure 2). There is no specific treatment for fat embolism or fat embolism syndrome. Therapy included prophylaxis stroke with aspirin at a daily dose of 100 mg, Low Molecular Weight Heparin (LMWH) 4000 IU once day and Dexamethasone 4 mg intravenous twice daily. After one day, the patient appeared markedly improved, alert, conscious and cooperative, oriented in time, with fluent speech, normal pupillary reflex, preserved strength, sensitivity and coordination,

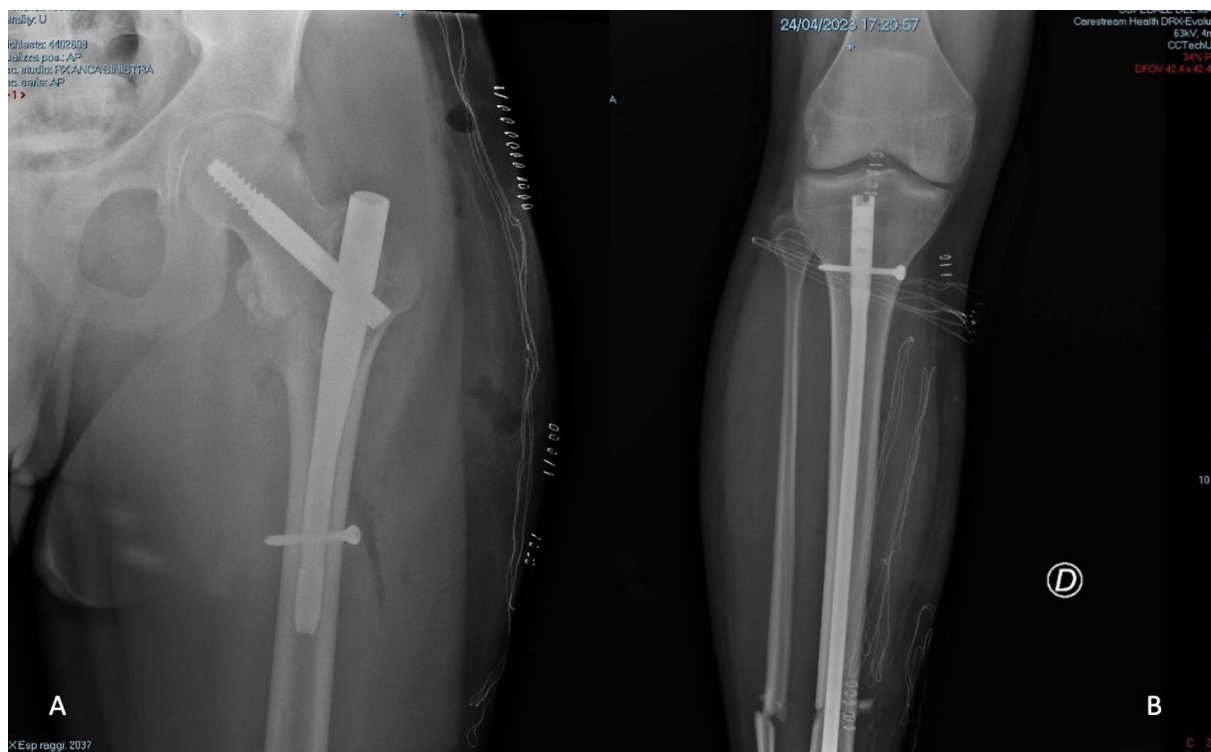


Figure 1: Post-operative X-Ray.

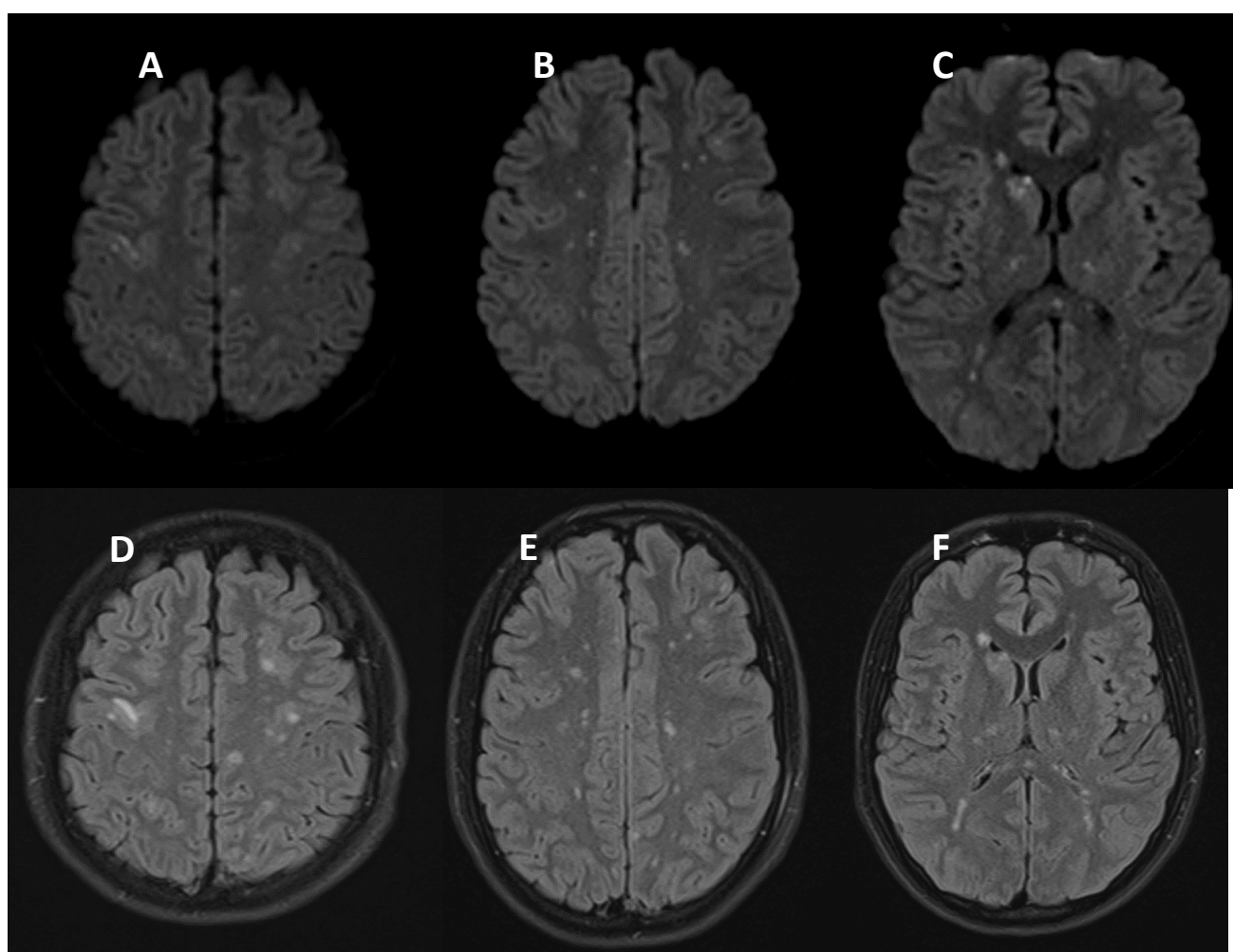


Figure 2: These foci are associated with parenchymal T2/FLAIR hyperintensities (D-E-F) and diffusion restriction (A-B-C), in particular along the hemisphere subcortical, periventricular white matter and bilateral nucleocapsular region. This imaging shows a "starfield pattern", the result of very numerous microemboli.

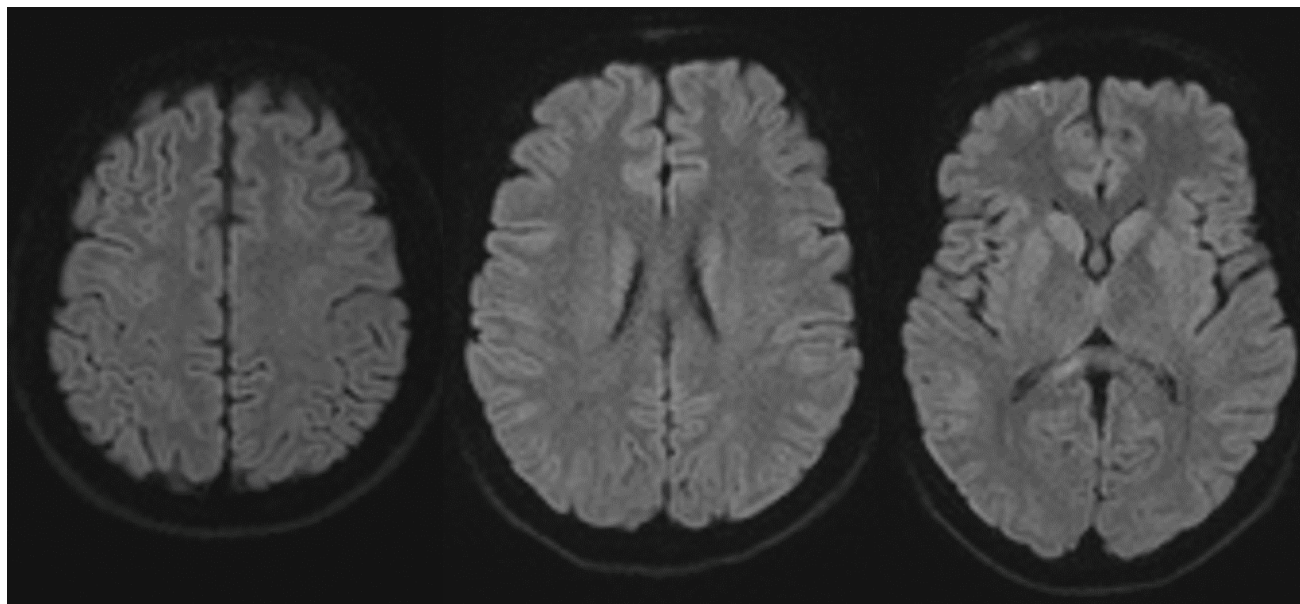


Figure 3: MRI FLAIR imaging after 10 days: Improvement of hyperintensity of known cerebral lesions.

Table 1: Two major criteria or 1 major criterion and 4 minor criteria suggest a diagnosis of fat embolism syndrome.

Major criteria	Minor criteria
Respiratory distress	Tachycardia (> 110 bpm)
Cerebral symptoms in injury patients	Fever (> 38.5 °C)
Petechial rash	Jaundice
	Renal changes
	Drop in hemoglobin
	New onset thrombocytopenia
	Elevated erythrocyte sedimentation rate
	Fat macroglobulinemia

absent meningeal symptoms. The patient during hospitalization practiced echocardiographic "bubble-test" with evidence of suspected atrial septal defects (ASDs) at the level of the caval septum with left-to-right shunt and passage of microbubbles of moderate entity. Transesophageal echocardiography could not be performed because of the patient's difficulty in lying lateral decubitus. After 10 days, the patient repeated brain MRI that showed attenuation of known ischemic lesions (Figure 3).

Discussion

Fat embolism syndrome is a clinical diagnosis and is caused by the release of fat droplets into the systemic circulation after conditions or procedures such as long bone or pelvic fractures, orthopedic surgery or other interventions [1-5]. The pathophysiology of FES is unknown, but different mechanisms have been suggested [6]. The mechanical mechanism suggests that physical obstruction of the vascular system occurs, caused by fat globules released from the bone marrow of long bones due to the increased intramedullary pressure after trauma or orthopedic surgery (such as intramedullary nailing) [7,8]. The biochemical theory

suggests liberation of free fatty acids after a local inflammatory response at the site(s) of fat emboli deposition, with a surge of catecholamines as a stress response to microtrauma of the affected capillary bed. These fatty acids interact with lung lipases, leading to the activation of the intrinsic apoptosis cascade and subsequent damage to both lung parenchyma and capillary endothelium, with the development of interstitial hemorrhages and edema [7,9,10]. The role of a PFO is not crucial in developing a lung fat embolism into a systemic embolism: The fat embolism is more of a biochemical and pathophysiological event, than a biomechanical one. The appearance of a patent foramen ovale associated with a systemic fat embolism should be less emphasized: Maybe arteriovenous shunts and anastomosis between the functional and nutritive, i.e. systemic circulation of lungs play a more important role in developing a SFE than a PFO [11]. The diagnosis of FES can be challenging and despite Gurd and Wilson's criteria (Table 1) have been adopted in clinical practice; no formal diagnostic criteria have been validated with large studies [12]. The clinical condition and neuroradiological imaging was compatible with fat embolism and "starfield pattern" [13,14]. High-risk

patients should be monitored closely for subclinical signs of respiratory insufficiency and with positive radiographic changes [15]. Other clinical signs of fat embolism are petechial rash, tachycardia, fever, retinal fat or petechiae, urinary fat globules or oligoanuria, sudden drop in Hg-level, sudden thrombocytopenia, high erythrocyte sedimentation rate and fat globules in sputum [16]. There is no specific treatment for fat embolism or fat embolism syndrome. Evidence has suggested that corticosteroids may be effective at preventing FES associated with long bone fractures [17]. The type 1 starfield pattern is usually reversible, thus resulting in better prognosis. It is most commonly observed in the acute stages, rather than in subacute or late stages [18].

Conclusion

We reported a rare case of isolated FES occurred after high-risk orthopedic injury. The patient fortunately went on to full cognitive recovery due to early diagnosis and appropriate supportive therapy. We must always suspect isolated FES in polytrauma patient, even if the classical findings are not present, performing an early MRI to confirm the diagnosis.

References

1. Nguyen QL, Varajic B, Reynolds SB, El-Kersh K (2022) Fat embolism syndrome with cerebral involvement: An underrecognized complication of long bone fractures. *Cureus* 14: e22816.
2. Scarpino M, Lanzo G, Lolli F, Grippo A (2019) From the diagnosis to the therapeutic management: Cerebral fat embolism, a clinical challenge. *Int J Gen Med* 12: 39-48.
3. Vetrugno L, Bignami E, Deana C, Bassi F, Vargas M, et al. (2021) Cerebral fat embolism after traumatic bone fractures: A structured literature review and analysis of published case reports. *Scand J Trauma Resusc Emerg Med* 29: 47.
4. Huang GS, Dunham CM, Chance EA (2023) Occurrence of numerous cerebral white matter hyperintensities in trauma patients with cerebral fat embolism: A systematic review and report of two cases. *Cureus* 15: e45450.
5. Yeo SH, Chang HW, Sohn SI, Cho CH, Bae KC (2013) Pulmonary and cerebral fat embolism syndrome after total knee replacement. *J Clin Med Res* 5: 239-242.
6. Taviloglu K, Yanar H (2007) Fat embolism syndrome. *Surg Today* 37: 5-8.
7. DeFroda SF, Klinge SA (2016) Fat embolism syndrome with cerebral fat embolism associated with long-bone fracture. *Am J Orthop* 45: E515-521.
8. Kwiatk ME, Seamon MJ (2013) Fat embolism syndrome. *Int J Crit Illn Inj Sci* 3: 64-68.
9. Berlot G, Bussani R, Shafiei V, Zarrillo N (2018) Fulminant cerebral fat embolism: Case description and review of the literature. *Case Rep Crit Care* 2018: 7813175.
10. Xiong L, Sun L, Liu S, Zhu X, Teng Z, et al. (2019) The protective roles of urinary trypsin inhibitor in brain injury following fat embolism syndrome in a rat model. *Cell Transplant* 28: 704-712.
11. Nikolić S, Živković V, Babić D, Džonić D, Djurić M (2012) Systemic fat embolism and the patent foramen ovale--A prospective autopsy study. *Injury* 43: 608-612.
12. Timon C, Keady C, Murphy CG (2021) Fat embolism syndrome - A qualitative review of its incidence, presentation, pathogenesis and management. *Malays Orthop J* 15: 1-11.
13. Parizel PM, Demey HE, Veeckmans G, Verstreken F, Cras P, et al. (2001) Early diagnosis of cerebral fat embolism syndrome by diffusion-weighted MRI (starfield pattern). *Stroke* 32: 2942-2944.
14. Aravapalli A, Fox J, Lazaridis C (2009) Cerebral fat embolism and the "starfield" pattern: A case report. *Cases J* 2: 212.
15. Robinson CM (2001) Current concepts of respiratory insufficiency syndromes after fracture. *J Bone Joint Surg Br* 83: 781-791.
16. Talbot M, Schemitsch EH (2006) Fat embolism syndrome: History, definition, epidemiology. *Injury* 37: S3-S7.
17. Fukumoto LE, Fukumoto KD (2018) Fat embolism syndrome. *Nurs Clin North Am* 53: 335-347.
18. Kuo KH, Pan YJ, Lai YJ, Cheung WK, Chang FC, et al. (2014) Dynamic MR imaging patterns of cerebral fat embolism: A systematic review with illustrative cases. *AJNR Am J Neuroradiol* 35: 1052-1057.