



## CASE REPORT

# Using Thromboelastography to Treat Patients with COVID-19-Associated Coagulopathy: A Case Report from the Front Lines

Crista E. Horton, MD\*, Vincent Athas, MD, Stacey L. Tannenbaum, PhD, Jose Lozada, MD and John Berne, MD

Department of Surgery, Broward Health Medical Center, 1600 S. Andrews Avenue, Fort Lauderdale, Florida, USA



\*Corresponding author: Crista E. Horton, MD, Department of Surgery, Broward Health Medical Center, 1600 S. Andrews Avenue, Fort Lauderdale, Florida, 33316, USA

## Abstract

There has been increasing evidence to support that COVID-19 infection is associated with hypercoagulable complications due to a systemic inflammatory response indirectly activating the coagulation cascade. This phenomenon has been termed, COVID-19-associated coagulopathy. Uniquely, trauma patients are highly susceptible to thromboembolic events. Monitoring for adequate chemical prophylaxis against these events is difficult, especially with superimposed COVID-19 infection. Although thromboelastography (TEG) has been utilized to assess clotting status in medical and surgical patients with ongoing bleeding, there has been limited research to investigate the value of TEG in evaluating clotting status of trauma patients affected by COVID-19. This case is the first to describe a COVID-19 positive trauma patient, who developed a DVT after splenectomy, who was on subtherapeutic DVT prophylaxis as assessed with anti-Xa assay monitoring and TEG analysis. This case supports that further utilization of TEG in COVID-19-positive trauma patients may be beneficial in identifying those patients at higher risk of thromboembolic complications, as well as assisting in DVT prophylaxis dosing, especially when confounding factors make identifying this risk challenging.

## Abbreviations

TEG: Thromboelastography; CAC: COVID-19-Associated Coagulopathy; DVT: Deep Venous Thrombosis

## Introduction

There has been increasing observational evidence of coagulopathic complications associated with COVID-19 infection. Recent evidence supports an indirect mechanism of endothelial injury causing

hypercoagulability in COVID-19 patients, which is now termed COVID-19-associated coagulopathy (CAC) [1,2]. A recent (2020) single-center study revealed that increased markers of Von Willebrand antigen significantly correlated with death in COVID-19 patients (n = 68), further highlighting the endothelial mechanism underlying the vasculopathy [3]. The emergent problem is to detect which patients with COVID-19 infection are at high risk from hypercoagulable complications.

Trauma is a major risk factor for development of deep venous thrombosis (DVT), for which the usual practice is prophylactic maintenance on low molecular weight heparin. An “anti-factor Xa” (anti-Xa) assay can be performed to further adjust dosing of DVT prophylaxis. Anti-Xa measures antithrombin inhibition of factor Xa, a clotting factor that is inhibited by low molecular weight heparin [4]. Currently, COVID-19 status is not included as an independent risk factor necessitating anti-Xa monitoring or adjustment, despite evidence that COVID-19 infection causes a hypercoagulable state. However, adjustments to DVT prophylaxis dosing may be recommended in patients who are underweight, obese, pregnant, or have renal impairment, as the anti-Xa level is usually higher in these patients, suggesting suprathreshold DVT prophylaxis dosing and higher risk of bleeding. Also, lower anti-Xa levels suggest subtherapeutic DVT prophylaxis in patients with liver cirrhosis or antithrombin deficiencies [5,6]. Adjusting DVT prophylaxis for COVID-19 positive patients may need consideration.



**Citation:** Horton CE, Athas V, Tannenbaum SL, Lozada J, Berne J (2023) Using Thromboelastography to Treat Patients with COVID-19-Associated Coagulopathy: A Case Report from the Front Lines. Trauma Cases Rev 9:099. doi.org/10.23937/2469-5777/1510099

**Accepted:** June 16, 2023; **Published:** June 18, 2023

**Copyright:** © 2023 Horton CE, et al. This is an open-access article distributed under the terms of the Creative Commons Attribution License, which permits unrestricted use, distribution, and reproduction in any medium, provided the original author and source are credited.

Thromboelastography (TEG) is a non-invasive test that quantitatively measures the ability of whole blood to form a clot. It is a technological assay dating back to the Vietnam War used to guide transfusions of blood components to injured soldiers in hemorrhagic shock [7]. However, more recently, TEG has emerged as a novel tool for understanding the hypercoagulable state of COVID-19 coagulopathy. TEG has advantages over other commonly used blood tests to evaluate coagulation in that it can be used to detect dynamic, qualitative changes and viscoelastic properties of blood under low shear stress, in time. The parameters of a thromboelastogram for interpretation include the R time - time to start forming clot, K time - time until clot reaches a fixed level of strength, alpha angle - speed of fibrin accumulation, maximum amplitude - maximal clot strength, and LY30, or percentage of amplitude reduction 30 minutes after maximum amplitude due to clot lysis [8]. This case highlights that TEG may be used to better understand the state of the clotting system in trauma patients who are already at high risk for thromboembolic complications, compounded by potentially devastating consequences of the hypercoagulable state of COVID-19.

## Case Presentation

A 59-year-old female was admitted to the trauma service after a motor vehicle collision. The patient

**Table 1:** TEG results. The values of the alpha angle and maximum amplitude are elevated beyond the normal range, indicating a hypercoagulable state due to higher fibrin accumulation and clot strength.

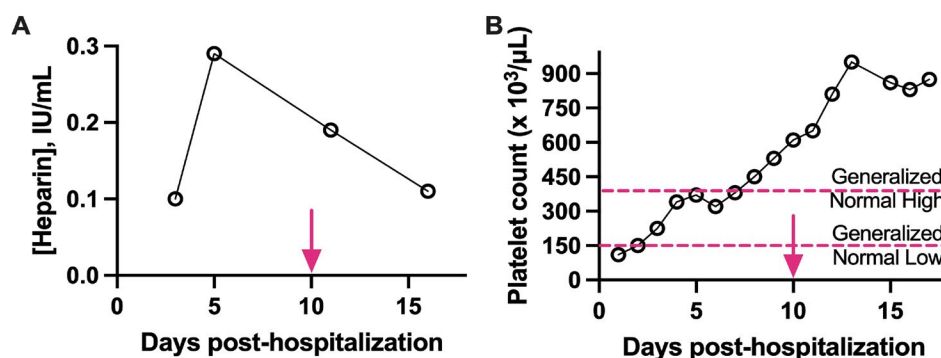
Component	Value	Normal range
R time	4.6 min	5-10 min
K time	0.8 min	1-3 min
Alpha angle	80 degrees	53-72 degrees
Maximum amplitude	75.5 mm	50-70 mm

suffered a left humeral fracture, a small subarachnoid hemorrhage, and a splenic laceration requiring emergent splenectomy on admission. The patient was also incidentally found to be positive for COVID-19, although, she did not complain of any COVID-19-related symptoms prior to surgery. On postoperative day two, the patient was started on 30 mg of enoxaparin [Lovenox, Sanofi-Aventis, Bridgewater Township, NJ, USA] every 12 hours as the standard starting regimen for DVT prophylaxis in trauma patients. On postoperative day three, the patient was extubated but required reintubation the same day due to acute hypoxic respiratory failure. She underwent tracheostomy on hospital day eight. Serial anti-Xa levels demonstrated that the patient was subtherapeutic for DVT prophylaxis despite weighting only 44.5 kg and having no other risk factors. The decision was made not to increase her dose of DVT prophylaxis, as she had recently had a splenectomy, as well as a traumatic brain bleed which are contraindications for chemical anticoagulation.

To further assess the patient's overall clotting status, a thromboelastogram was obtained on hospital day 12 (Table 1, Figure 1a and Figure 1b).

The value of the alpha angle and maximum amplitude suggested that, compared to normal, the patient had higher amounts of fibrin accumulation and maximal clot strength values. This was indicative of a hypercoagulable state, likely due to her underlying comorbidities of recent trauma and COVID-19. The TEG results provided an explanation for why her anti-Xa levels were low and not responding appropriately to therapeutic DVT prophylaxis.

The patient continued to recover slowly with intermittent episodes of hypotension and tachycardia requiring resuscitation with albumin. On hospital day 24, ultrasound of the lower extremities revealed a saphenofemoral superficial vein thrombus. The



**Figure 1:** (a) Anti-Xa level over time. Patient's anti-Xa level initially peaked to 0.28 IU/mL. Normal range is 0.2-0.8 IU/mL. After this peak, her levels were consistently low, indicating that she was subtherapeutic for DVT prophylaxis dosing; (b) Platelet level over time. Patient's platelet levels gradually increased during course of hospital stay. Increase in platelets is to be expected in patients after splenectomy. This demonstrates a confounding factor, as the patient had increasing level of platelets, which would have contributed to the patient's hypercoagulable state.

Red arrow: The red arrow indicates the time point at which TEG was conducted.

patient eventually developed bilateral femoral DVTs extending to the inferior vena cava. This likely occurred after DVT chemoprophylaxis had been held for several interventional radiology procedures including pigtail catheter placement due to pleural effusion, as well as catheter upsizing on hospital day 52. Despite a prolonged hospital course including readmission to the intensive care unit (ICU), she continued to recover well and was discharged to a rehabilitation center on hospital day 67.

## Discussion

COVID-19 positive patients have elevated parameters in TEG and this correlates with CAC, with maximum amplitude elevation observed in 75% of CAC patients in single-center studies [9]. CAC may be linked to longer hospital stays requiring ICU-level care and increased risks of DVT. There are certain criteria for which anti-Xa monitoring is used, none of which currently include COVID-19 infection. Further investigation is needed to determine if COVID-19 patients require dose adjustments in DVT prophylaxis and the role that anti-Xa monitoring can play.

TEG can be used to evaluate patients who may be at higher risk of hypercoagulability and thromboembolic events, specifically trauma patients. Trauma patients have a systemic inflammatory response that affects the coagulation cascade significantly. There is high value in utilizing TEG to treat trauma patients postoperatively who is at risk for thromboembolic events after resuscitation or surgery throughout their hospital stay.

Finally, evidence shows that trauma patients who undergo splenectomy have a more hypercoagulable state than other trauma patients, as demonstrated by greater values for alpha angle and maximum amplitude on TEG [10]. These splenectomy patients are also at higher risk of thromboembolic complications. This case highlights how COVID-19 infection may alter the overall clotting state, requiring further precautions in dosing DVT prophylaxis, especially when confounded by splenectomy. Further research is needed to establish the role of TEG interpretation in treating COVID-19 positive trauma patients, but TEG continues to be a useful adjunct to gain insight into the hypercoagulable state of COVID-19.

## Conclusions

CAC is a hypercoagulable state in which some evidence shows a role for the use of TEG in understanding clotting status. Trauma patients are already affected by

thromboembolic events at baseline due to the overall inflammatory mechanism of the coagulation cascade. In patients with superimposed COVID-19, trauma patients are at higher risk for these complications. There may be value in promoting the use of TEG in complementing DVT prophylaxis dosing using anti-Xa monitoring. This case presents a novel and emerging use for TEG in COVID-19-affected trauma patients.

## Source of Funding

This work was not conducted with any source of funding.

## Authors Contribution

All authors contributed equally to this work.

## References

1. Hartmann J, Ergang A, Mason D, Dias JD (2021) The role of TEG analysis in patients with covid-19-associated coagulopathy: A systematic review. *Diagnostics* 11: 172.
2. Nicosia RF, Ligresti G, Caporarello N, Akilesh S, Ribatti D (2021) COVID-19 vasculopathy: Mounting evidence for an indirect mechanism of endothelial injury. *Am J Pathol* 191: 1374-1384.
3. Goshua G, Pine AB, Meizlish ML, Chang CH, Zhang H, et al. (2020) Endotheliopathy in COVID-19-associated coagulopathy: Evidence from a single-centre, cross-sectional study. *The Lancet Haematology* 7: E575-E582.
4. Gates RS, Lollar DI, Collier BR, Smith J, Faulks ER, et al. (2022) Enoxaparin titrated by anti-Xa levels reduces venous thromboembolism in trauma patients. *J Trauma Acute Care Surg* 92: 93-97.
5. Vera-Aguilera J, Yousef H, Beltran-Melgarejo D, Teng TH, Jan R, et al. (2016) Clinical scenarios for discordant anti-xa. *Adv Hematol* 2016: 4054806.
6. Costantini TW, Min E, Box K, Tran V, Winfield RD, et al. (2013) Dose adjusting enoxaparin is necessary to achieve adequate venous thromboembolism prophylaxis in trauma patients. *J Trauma Acute Care Surg* 74: 128-133.
7. Shaydakov ME, Sigmon DF, Blebea J (2023) Thromboelastography. *StatPearls*.
8. Bolliger D, Seeberger MD, Tanaka KA (2012) Principles and practice of thromboelastography in clinical coagulation management and transfusion practice. *Transfus Med Rev* 26: 1-13.
9. Salem N, Atallah B, Nekidy WSE, Sadik ZG, Park WM, et al. (2021) Thromboelastography findings in critically ill COVID-19 patients. *J Thromb Thrombolysis* 51: 961-965.
10. Pommerening MJ, Rahbar E, Minei K, Holcomb JB, Wade CE, et al. (2015) Splenectomy is associated with hypercoagulable thromboelastography values and increased risk of thromboembolism. *Surgery* 158: 618-626.